



**PATIENT**

Drake Sterling

**SPECIES**

Feline

**BREED**

DSH

**SEX**

Neutered Male

**AGE**

10 Years

**WEIGHT**

11.5 Pounds

**INTERPRETED BY**

Eric Lindquist, DMV

DABVP, Cert. IVUSS

**IMAGING PERFORMED BY**

Dr. Carlos Abdul-Chani

**HOSPITAL NAME**

Byram AH

**REFERRING VET**

Dr. Carlos Abdul-Chani

**INVOICE**

43956

**DATE**

7/13/23

**PRESENTING CLINICAL SIGNS**

Reason for Ultrasound: R/O neoplasia, Pancreatitis; 4 lb. weight loss

Abnormal PE/Chem/CBC/UA Results: Abnormal CBC/Chem Findings: all WNL Abnormal U/A Findings: not done

**ULTRASONOGRAPHIC EXAMINATION OF THE ABDOMEN**

**Urinary System**

The **urinary bladder**, trigone, and pelvic urethra presented normal thicknesses and normal tone. The ureters were not visible which is normal. No uroliths or sediment were visualized and anechoic urine was present. No evidence of inflammatory or neoplastic changes were noted. Ureteral papillae were normal. The pelvic urethra was imaged 2.0 cm beyond the cystourethral junction.

The **kidneys** revealed normal size and structure, corticomedullary definition and ratio for this age. The cortices presented largely uniform texture with normal echogenic relationship to liver and spleen. Medullary structure differed distinctly from the cortex and no evidence of pelvic dilation was present. The capsules were acceptably uniform without significant irregularities. The right kidney measured 4.5 cm. The left kidney measured 4.3 cm.

**Adrenal Glands**

Both **adrenal glands** were visualized and recognized as having normal shape, size, position and echogenicity for this breed. The phrenic vasculature, glandular echogenicity and detail were unremarkable. Capsule, cortex, and medullary definition were normal for this age patient. The left adrenal gland measured 0.39 cm. The right adrenal gland measured 0.49 cm.

**Spleen**

The **spleen** presented a smooth homogeneous parenchyma hyperechoic to liver and renal cortical parenchyma. The capsule was smooth without noticeable expansion or deviation from within the spleen or adjacent pathology. The splenic vasculature demonstrated normal volume without signs of congestion or thrombosis. No sonographic evidence of acute or chronic inflammatory, neoplastic, or infarctual changes were noted.

**Liver**

The **liver** presented mild increased portal markings and coarse architecture. The gallbladder and common bile duct were unremarkable. Past history of cholangitis likely.

**Gastrointestinal**

Examination of the **gastrointestinal tract** revealed a stomach and intestine free of stasis, of normal wall thickness, acceptable curvilinear mural detail, and peristaltic activity. Small and large intestine demonstrated normal luminal chyme and stool consistency respectively. No obstructive or overt infiltrative disease was noted. No associated abnormal lymphatic activity was noted.

**Pancreas**

The **pancreas** was hypoechoic and irregular with dilated duct. Possible low-grade inflammation, yet no reactive mesentery noted.

**Free Abdomen**

Reactive mesenteric lymph nodes noted, measuring 1.0 cm x 0.50 cm.



**PATIENT**

Drake Sterling

**SPECIES**

Feline

**BREED**

DSH

**SEX**

Neutered Male

**AGE**

10 Years

**WEIGHT**

11.5 Pounds

**INTERPRETED BY**

Eric Lindquist, DMV

DABVP, Cert. IVUSS

**IMAGING PERFORMED BY**

Dr. Carlos Abdul-Chani

**HOSPITAL NAME**

Byram AH

**REFERRING VET**

Dr. Carlos Abdul-Chani

**INVOICE**

43956

**DATE**

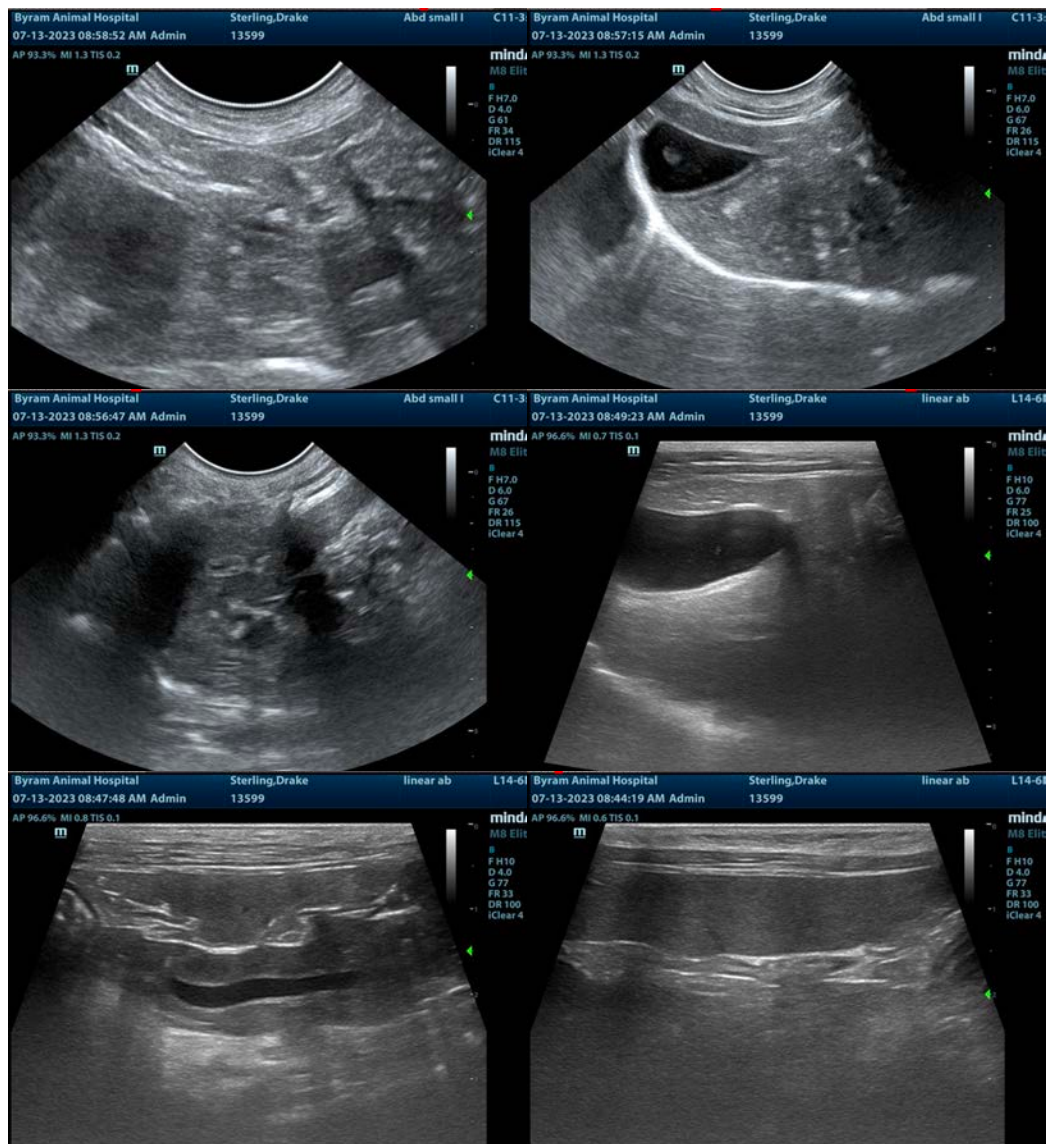
7/13/23

**ULTRASONOGRAPHIC FINDINGS**

- Prominent pancreas
- Coarse hepatic architecture

**INTERPRETATION OF THE FINDINGS & FURTHER RECOMMENDATIONS**

Bile acid profile would be indicated. Maldigestion panel, three view chest radiographs and full CNS examination is recommended to examine for occult disease that could be responsible for the weight loss. Evaluation for competitive eating environments should also be considered. No overt evidence of neoplasia.





**PATIENT**

Drake Sterling

**SPECIES**

Feline

**BREED**

DSH

**SEX**

Neutered Male

**AGE**

10 Years

**WEIGHT**

11.5 Pounds

**INTERPRETED BY**

Eric Lindquist, DMV

DABVP, Cert. IVUSS

**IMAGING PERFORMED BY**

Dr. Carlos Abdul-Chani

**HOSPITAL NAME**

Byram AH

**REFERRING VET**

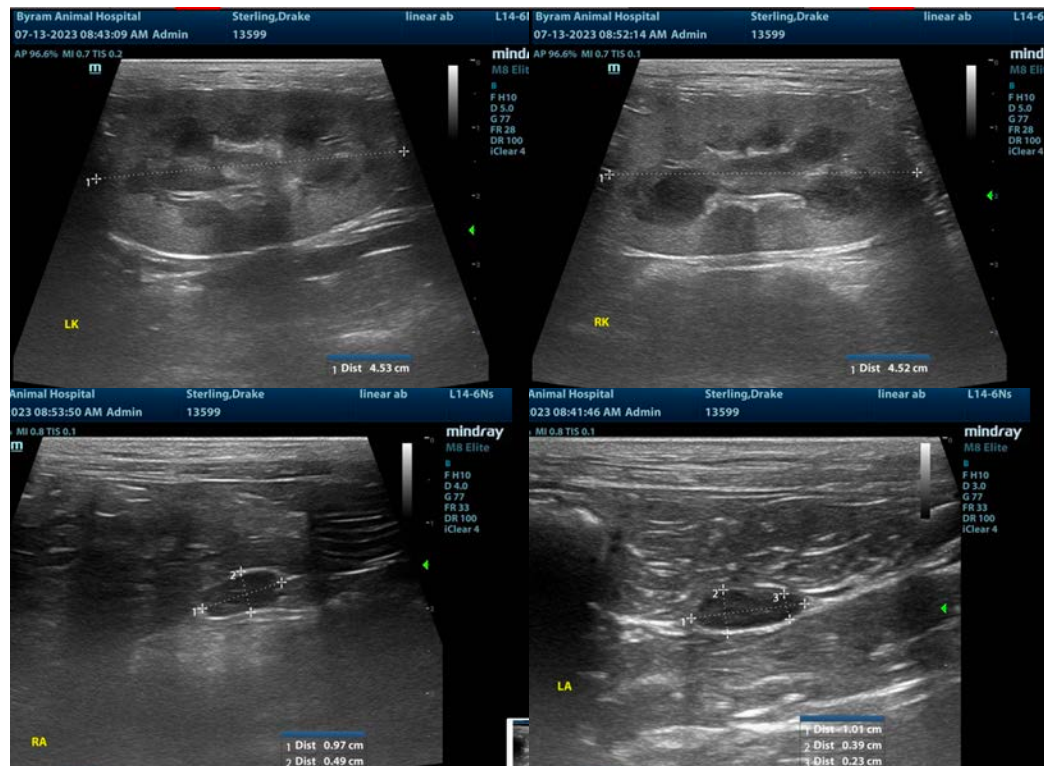
Dr. Carlos Abdul-Chani

**INVOICE**

43956

**DATE**

7/13/23



The information and recommendations provided are based on the images presented by the referring veterinarian/sonographer. No evaluation can be communicated regarding pathology that was not visible in the image/video clips provided.

Thank you for this referral. If the clinical or image interpretation does not parallel your findings or if I can be of any further assistance please contact me.

Eric Lindquist, DMV, DABVP, Cert. IVUSS, CEO of SonoPath.com

[info@SonoPath.com](mailto:info@SonoPath.com)