



## PATIENT PRESENTING CLINICAL SIGNS

**Bella Gmyrek** History of heart murmur. Will be getting dental in the fall; elevated liver enzymes; hx of UTIs. Not on any meds.

## SPECIES

Canine

Abnormal PE/Chem/CBC/UA Results: TP 2.6, ALKP 1329, chol 432, Trig 1610, PSL 225, BUN/Crea 40; platelets 470, UA: UPC 2.8, prot +3, occult blood trace, WBC 11-20, RBC 4-10, struvites 4-10, cocci 51-100, USPG 1.029

## BREED

Chihuahua Mix

## ULTRASONOGRAPHIC EXAMINATION OF THE HEART & ABDOMEN

## SEX

Spayed Female

## AGE

11 Years

## WEIGHT

21 Pounds

CANINE CARDIAC PARAMETERS	MR VMAX (m/s)	TR VMAX (m/s)	LA/AO (Boon method)	LA/AO (Heart Base; Swe)	FS (%)	EF (%)	EPSS (cm)
NORMAL PARAMETER	4.5-5.5	<2.7	1.3	<1.6	28-40	40-100	<0.6
PATIENT	5.87	--	1.57	1.8	38	70	0.1
CANINE CARDIAC PARAMETERS	HR (BPM)	AV VMAX (m/s)	PV MAX (m/s)	BODY WEIGHT (kg)	LA 2D short axis Base view (cm)	LVIDd Avg; 2D and m-mode short axis (cm)	LVIDs Avg; 2D and m-mode short axis (cm)
NORMAL PARAMETER	50-100	0.7-1.7	0.7-1.6				
PATIENT	178	1.53	1.10	--	2.8	3.13	--

## INTERPRETED BY

Eric Lindquist, DMV  
DABVP, Cert. IVUSS

## Cardiac Presentation

The echocardiogram in this patient demonstrated slightly enlarged **left atrial** size based on 3 different LA measurement methods. Chamber volumes and echogenicity were normal. The cranial and caudal **mitral** valve leaflets presented vegetative thickening consistent with endocardiosis. Doppler indicated measurable insufficiency. The **left ventricle** presented thicknesses with linear contour and was not dilated nor restricted. The **myocardium** presented normal echogenicity without subjective evidence of significant fibrotic or ischemic disease. **Contractility** of the ventricular walls was adequate and in normal range for this patient evidenced by the fractional shortening measurement and subjective evaluation of the different regions of the myocardium. The **left ventricular outflow** tract demonstrated normal laminar flow and subjective structural integrity. The **right atrium** and auricle revealed normal size, structure and content. No evidence of masses was noted or chamber overload. **Tricuspid** valvular assessment demonstrated adequate linear morphology. The **right ventricle** was of normal size (1/3 diameter of LV), chordae structure, myocardial echogenicity and thickness. **Pulmonic** tract assessment revealed normal valve structure, laminar flow, and diameter (approx.1:1 pa/ao ratio). No visible **pericardial** or free pleura fluid was noted. No echographically detectable evidence of infiltrative disease was visible. The cranial **mediastinum and pericardial regions** were free of masses in the visible window.

## IMAGING PERFORMED BY

Diane McFadden

## HOSPITAL NAME

AH of Roxbury

## REFERRING VET

Dr. Hickenbottom

## INVOICE

23334

## DATE

7/13/23

## Urinary System



**PATIENT**

Bella Gmyrek

The **urinary bladder** revealed sand accumulation, a grouping of which measured 1.5 cm. The pelvic urethra was imaged 2.0 cm beyond the cystourethral junction.

**SPECIES**

Canine

The **kidneys** revealed largely normal size and structure, corticomedullary definition and ratio (cortex 1/3 of medulla) were essentially maintained with some mild age-related loss of curvilinear patterns regarding the capsule and C/M junction. The cortices presented largely uniform texture with some increased echogenicity expected for his age patient. Medullary structure differed distinctly from that of the cortex and no evidence of pelvic dilation was present. The right kidney measured 5.52 cm. The left kidney measured 4.94 cm. Mineralization was present in the kidneys.

**BREED**

Chihuahua Mix

**Adrenal Glands**

**SEX**

Spayed Female

The **adrenal glands** appeared slightly enlarged and swollen. No evidence of focal capsular expansion or invasion into the phrenic veins were noted. No overt suspicion of neoplasia was noted. This is considered likely a hyperplastic change associated with stress or adrenal endocrinopathy (PDH). If isosthenuria is persistently present and the patient morphologically suggests Cushing's disease then ACTH testing would be indicated. This is a mild change. The right adrenal gland measured 2.12 cm x 0.64 cm at the caudal pole and 0.54 cm at the cranial pole. The left adrenal gland measured 2.28 cm x 0.83 cm at the caudal pole and 0.53 cm at the cranial pole.

**AGE**

11 Years

**Spleen**

**WEIGHT**

21 Pounds

The **spleen** presented a smooth homogeneous parenchyma hyperechoic to liver and renal cortical parenchyma. The capsule was smooth without noticeable expansion or deviation from within the spleen or adjacent pathology. The splenic vasculature demonstrated normal volume without signs of congestion or thrombosis. No sonographic evidence of acute or chronic inflammatory, neoplastic, or infarctual changes were noted.

**INTERPRETED BY**

Eric Lindquist, DMV  
DABVP, Cert. IVUSS

**Liver**

**IMAGING PERFORMED BY**

Diane McFadden

The **liver** was uniformly swollen with minor, excessive gallbladder debris and over distension with dependent and suspended bile without evidence of overt mucocele formation. However, excessive sludge was present. The liver presented coarse architecture with mildly increased portal markings and subtle, mixed echogenic changes. This is consistent with vacuolar hepatopathy and some level of remodeling and history of inflammatory component. There was no overt suspicion of neoplasia. This is a mild change. Slight gallbladder polyps were noted.

**HOSPITAL NAME**

AH of Roxbury

**Gastrointestinal**

**REFERRING VET**

Dr. Hickenbottom

There was some residual chyme and gas was noted in the **stomach**, yet not pathological. This is consistent with end post prandial presentation. Transit of chyme into the small intestine was normal. Curvilinear patterns were maintained throughout the GI tract. No evidence of pathology. Small and large intestine demonstrated normal luminal chyme and stool consistency respectively. No obstructive or overt infiltrative disease was noted. No associated abnormal lymphatic activity was noted.

**INVOICE**

23334

**Pancreas**

**DATE**

7/13/23

The base and limbs of the **pancreas** were observed to be largely isoechoic to surrounding omental fat. Pancreatic duct and capsular contour were acceptably normal and parenchyma respected normal curvilinear patterns. No overt evidence of active inflammatory or neoplastic disease was noted.

**ULTRASONOGRAPHIC FINDINGS**



**PATIENT**

Bella Gmyrek

- Early, stage B-2 valvular disease
- Age-related renal changes with mineralization
- Bilateral adrenal hypertrophy
- Urinary bladder sand
- Partially full stomach
- Hepatopathy with gallbladder polyps

**SPECIES**

Canine

**BREED**

Chihuahua Mix

**SEX**

Spayed Female

**AGE**

11 Years

**WEIGHT**

21 Pounds

**INTERPRETATION OF THE FINDINGS & FURTHER RECOMMENDATIONS**

Blood pressure measurements are warranted. Pimobendan (0.3 mg/kg BID) could be justified. The heart is in a somewhat precarious state with volume overload and a heart that is working to compensate for the valvular insufficiency. Target respiratory rate is < 20 resp/minute after therapy. After initiating therapy, I recommend recheck on the clinical exam, BUN, Creatinine, USG, Chest radiographs & Blood pressure in 5-7 days. Recheck echo in 1 month. Earlier if clinical decompensation is occurring. I do not recommend anesthesia at this time until stabilization has occurred on the recommended medications. Repeat preanesthetic echo is ideal if anesthesia is eventually necessary.

Dissolution therapy or eventual cystostomy and sand analysis and culture are indicated. However, assessment for emerging Cushings, blood pressures and cardiac treatment is recommended prior to eventual cystostomy. Strong concern for emerging pituitary dependent hyperadrenocorticism. If urine specific gravity is <1.020, then work up for PDH is indicated. The urine specific gravity is partially concentrated, hence an emerging cushingoid state is likely present. Full adrenal panel to University of Tennessee would be ideal.

**Cushing Work UP**

**Efficient & Accurate Cushing's Work up-Lindquist**

**Notes regarding Cushing's Clinical Presentations:**

*Nearly all Cushing's dogs have SAP elevations and true PU/PD (USG < 1.025) and most are polyphagic. Cushing's dogs are > 6 years and usually > 9 years old, usually have poor skin coats, body scores > 3/5, and are usually sedentary animals.*

*Its important to remember that Cushing's dogs usually look and play the part and other diseases cause false + stress related cortisol spikes. On rare occasion a Cushing's dog will not follow the rules but this is truly an exception.*

*Potential Cushing's patient workups can be costly and frustrating if not definitive and, in my experience, the non-definitive patient usually has something else going on that may be contributing to some of the clinical signs a Cushing's dog will have, especially SAP elevations or PU/PD. Based on this prelude of information I came up with the following algorithm in the spirit of diagnostic efficiency.*

*The following suggested protocol is based on current available literature on Cushing's disease and extensive clinical-sonographic experience evaluation + Cushing's and False + LDDST & ACTH stim. cases in order to maximize the efficiency of a Cushing's workup in practice.*

**INTERPRETED BY**

Eric Lindquist, DMV  
DABVP, Cert. IVUSS

**IMAGING PERFORMED BY**

Diane McFadden

**HOSPITAL NAME**

AH of Roxbury

**REFERRING VET**

Dr. Hickenbottom

**INVOICE**

23334

**DATE**

7/13/23

**Screen first, workup second**

1) **UA:** Repeatable (2-3 urine samples) Urine specific gravity & urine cortisol/creatinine ratio (UCCR): If **repeatable USG < 10.20 and + UCCR** move to next step 2.



## PATIENT

Bella Gmyrek

Note: UA is inexpensive and easy to obtain and if UA criteria is not met for Cushing's then resources can be spent into other more pertinent diagnostics or left on hold until the UA criteria is met in emerging Cushing's cases.

## SPECIES

Canine

2) **Sonogram:** Does the patient **have concurrent disease** clinically or sonographically as non-Cushing's illness will influence the potential false + LDDST or even ACTH stim. The sonogram gives a global perspective of the internal health of the patient to be considered in the Cushing's workup as an assessment of concurrent disease. Is there a concurrent neoplastic process, UTI pancreatitis, mucocele....? Are the adrenals enlarged (Cushing's-PDH, stress, age related or breed variant), or atrophied (iatrogenic Cushing's or adrenal burnout), have asymmetric enlargement (Adrenal tumor, hyperplasia, adenoma, age related variant), or is there vascular invasion (Invasive pheo with false + UA criteria or adenocarcinoma or phrenic thrombosis)? The sonogram answers these questions proactively.

## BREED

Chihuahua Mix

## SEX

Spayed Female

**Address & treat concurrent disease first before performing Cushing's testing or testing will be artificially altered increasing false negatives and positives.**

## AGE

11 Years

3) **LDDST** (0.01 D-Sodium phosphate mg/kg IV **with precise dosing\*\*\*\***) (Better screening test but plagued with false + but considered more specific than ACTH stim) Use if there is potential early Cushing's or if adrenal asymmetry present on sonogram suspecting tumor. Use LDDST in cats at a higher dose (0.1 mg/kg IV). **Interpretation LDDST:** Look at 8-hour post first: If > 1.4 = Cushing's. Then look at 4-hour: if > 1.4 or > 50% baseline = Cushing's. 4-hour do then 8-hour spike most consistent with PDH. Flat line high constant curve without dip more consistent with tumor but can be PDH. See attached graph.

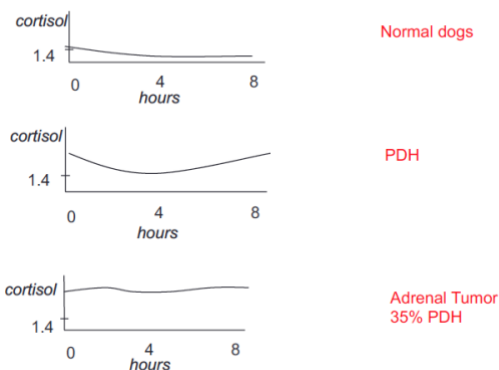
## WEIGHT

21 Pounds

## INTERPRETED BY

Eric Lindquist, DMV  
DABVP, Cert. IVUSS

## LDDS



## IMAGING PERFORMED BY

Diane McFadden

## HOSPITAL NAME

AH of Roxbury

## REFERRING VET

Dr. Hickenbottom

Courtesy: Rebecca Berg DACVIM, DECVIM

## INVOICE

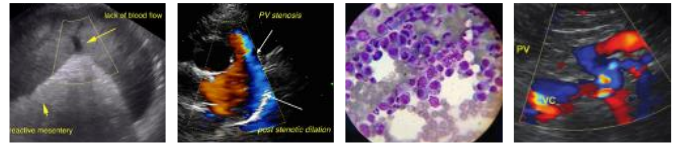
23334

4) **ACTH stim.** (Better confirming test but can have false +) Use if the patient "looks" Cushingoid or if bilateral adrenal enlargement is present, or high normal width on sonogram, or if iatrogenic Cushing's suspected (Cortisone Tx in past). ACTH stim is better for diagnosis of Addisons, Iatrogenic Cushing's, and Cushing's therapy monitoring but problematic with initial Cushing's diagnosis. First dx LDDST is suggested.

## DATE

7/13/23

5) If **diabetic** then run both LDDST & ACTH stim but stabilize as much as possible first.



**PATIENT**

Bella Gmyrek

5) Run a **serial blood pressure** in a BP friendly non "white coat effect" atmosphere. Run at least 3 at different times over a few hours or when eating as the patient tends to be calm when eating or give Torbutrol when entering the facility. Cushing's hypertension is usually 150-180 systolic range while pheochromocytoma range is more often > 180 systolic.

**SPECIES**

Canine

6) **Perform CT** of the pituitary to identify macro adenoma expansion if any lethargy or dullness or other central clinical CNS signs are minimally present. CT for adrenal may be more thorough for adrenalectomy surgical planning if ultrasound views of the CVC were problematic.

**BREED**

Chihuahua Mix

7) **Adrenectomy** for adrenal mass is prescribed then it is essential to stabilize the patient first regarding secondary disease such as organ dysfunction, hypertension, diabetes mellitus, hypernatremia, thromboembolic risk urinary and other infection in order to minimize potential for operative and postoperative complications as they are common in adrenalectomy. Trilostane stabilization therapy for Cushing's would be the first approach then address surgery and hypertension should be managed ideally < 160 systolic with ace inhibitors, phenoxybenzamine, or amlodipine.

**SEX**

Spayed Female

Suggested reading:

**AGE**

11 Years

Behrend EN, Kooistra HS, Nelson R, et al. Diagnosis of Spontaneous Canine Hyperadrenocorticism: 2012 ACVIM Consensus Statement (Small Animal). J Vet Intern Med 2013;27:1292–1304 .

**WEIGHT**

21 Pounds

**INTERPRETED BY**

Eric Lindquist, DMV  
DABVP, Cert. IVUSS

**IMAGING PERFORMED BY**

Diane McFadden

**HOSPITAL NAME**

AH of Roxbury

**REFERRING VET**

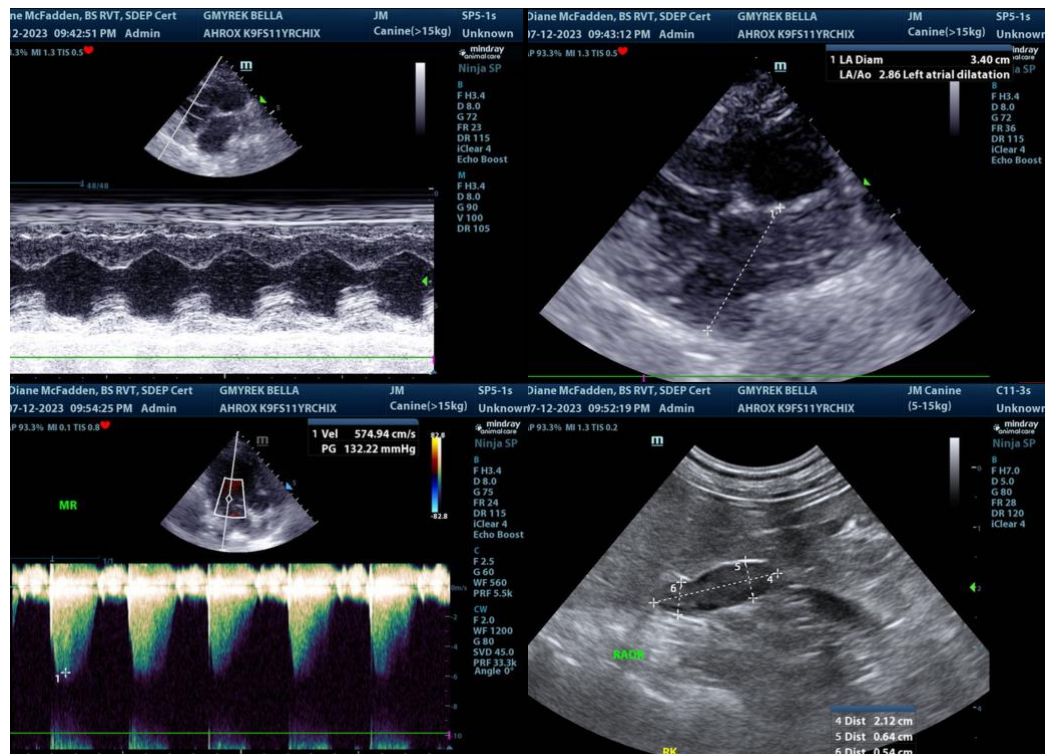
Dr. Hickenbottom

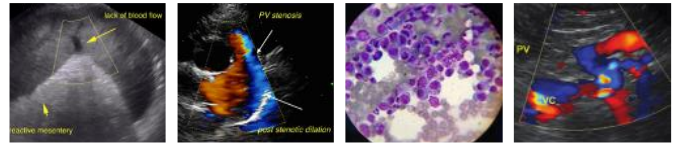
**INVOICE**

23334

**DATE**

7/13/23





**PATIENT**

Bella Gmyrek

**SPECIES**

Canine

**BREED**

Chihuahua Mix

**SEX**

Spayed Female

**AGE**

11 Years

**WEIGHT**

21 Pounds

**INTERPRETED BY**

Eric Lindquist, DMV  
DABVP, Cert. IVUSS

**IMAGING PERFORMED BY**

Diane McFadden

**HOSPITAL NAME**

AH of Roxbury

**REFERRING VET**

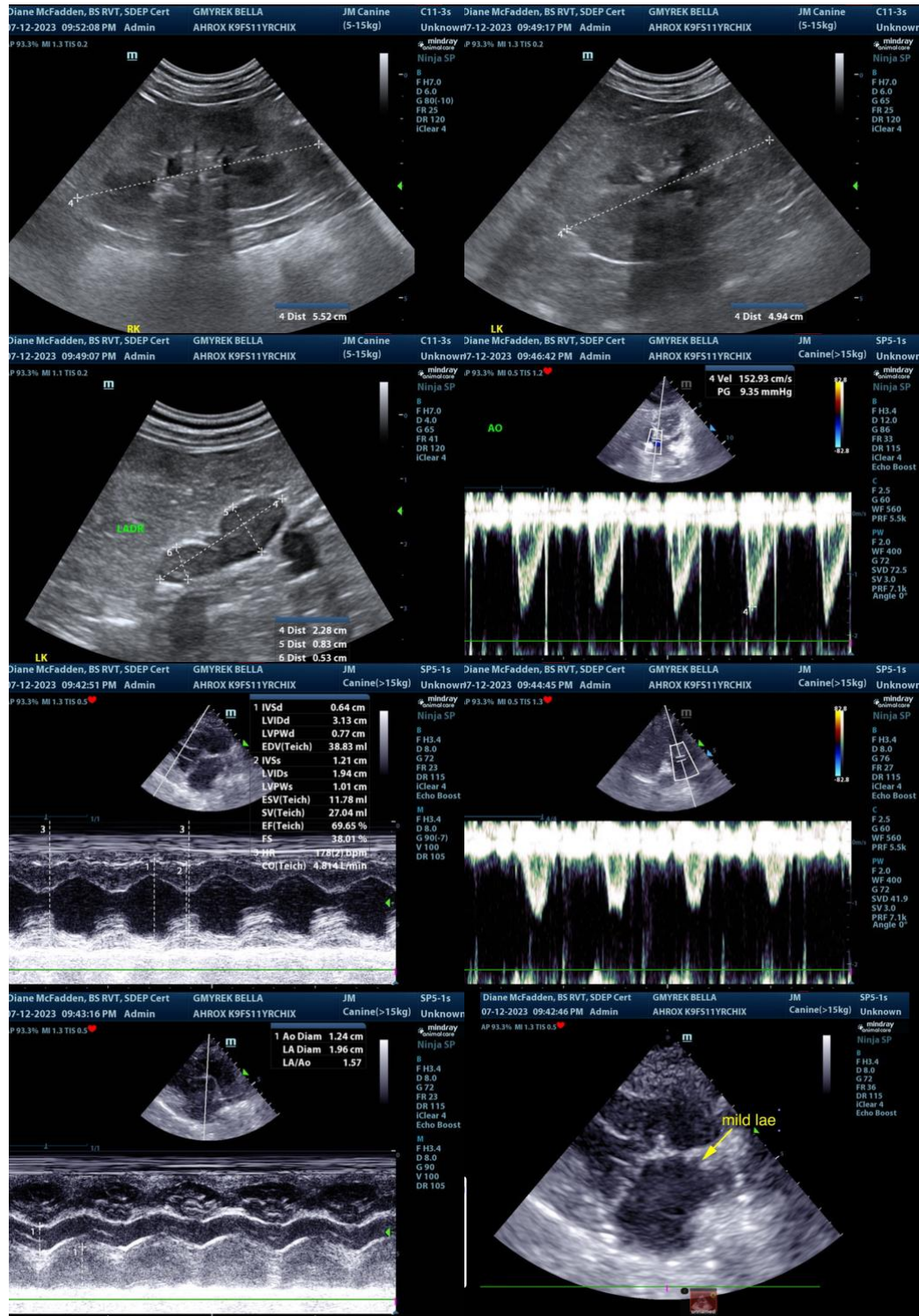
Dr. Hickenbottom

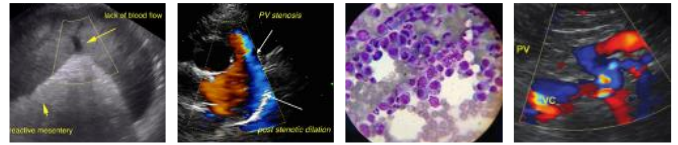
**INVOICE**

23334

**DATE**

7/13/23





**PATIENT**

Bella Gmyrek

**SPECIES**

Canine

**BREED**

Chihuahua Mix

**SEX**

Spayed Female

**AGE**

11 Years

**WEIGHT**

21 Pounds

**INTERPRETED BY**

Eric Lindquist, DMV  
DABVP, Cert. IVUSS

**IMAGING PERFORMED BY**

Diane McFadden

**HOSPITAL NAME**

AH of Roxbury

**REFERRING VET**

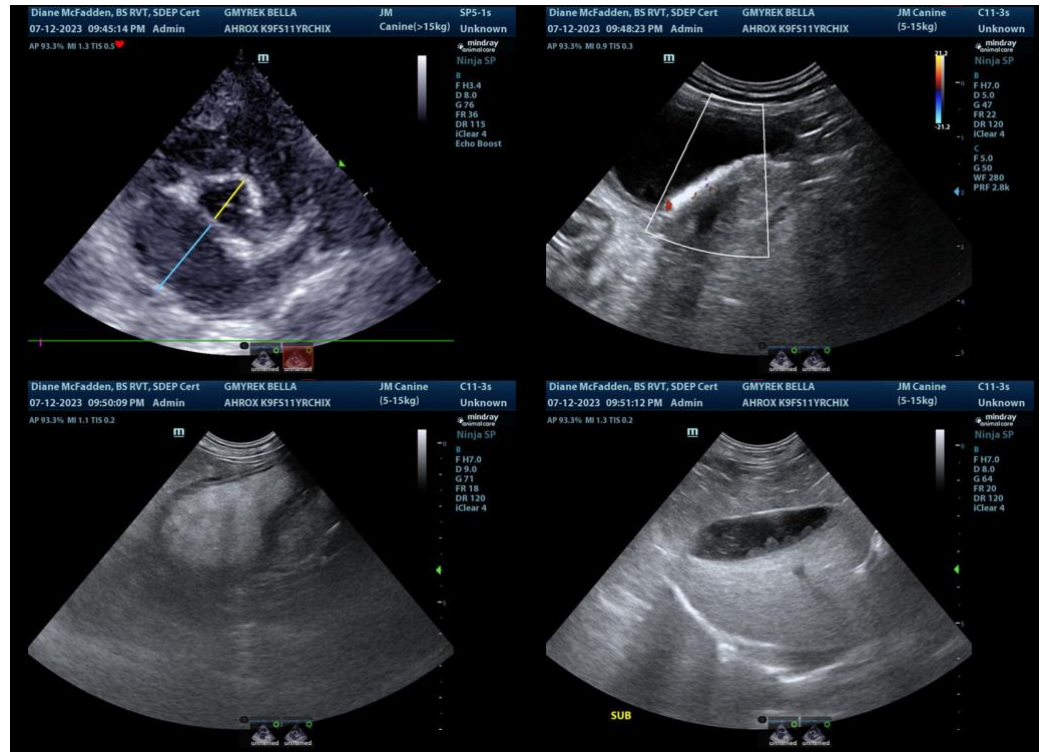
Dr. Hickenbottom

**INVOICE**

23334

**DATE**

7/13/23



**The information and recommendations provided are based on the images presented by the referring veterinarian. No evaluation can be communicated regarding pathology that was not visible in the image/video clips provided.**

Thank you for this referral. If the clinical or image interpretation does not parallel your findings or if I can be of any further assistance please contact me.

**Eric Lindquist**, DMV, DABVP, Cert. IVUSS, CEO of SonoPath.com  
info@SonoPath.com