



## PATIENT PRESENTING CLINICAL SIGNS

**Gunnar Baratti**  
Two week history of poor appetite, mild lethargy, and diarrhea. Abdominal mass (suspected to be splenic) identified on examination. Patient has a long-standing Grade 3/6 systolic heart murmur, with no clinical signs of heart disease evident.

**SPECIES**  
Canine

Abnormal PE/Chem/CBC/UA Results: Chem 17: Glob 4.7 CBC: Hct low normal at 37.9, but MCV low at 56.1, MCH low at 20, and Retics slightly increased at 110.9 Current Medications Metronidazole, Gabapentin

## BREED

Standard Poodle

## ULTRASONOGRAPHIC EXAMINATION OF THE HEART & ABDOMEN

## SEX

Neutered Male

## AGE

11 Years

## WEIGHT

76 Pounds

## INTERPRETED BY

Eric Lindquist, DMV

DABVP, Cert. IVUSS

CANINE CARDIAC PARAMETERS	MR VMAX (m/s)	TR VMAX (m/s)	LA/AO (Boon method)	LA/AO (Heart Base; Swe)	FS (%)	EF (%)	EPSS (cm)
NORMAL PARAMETER	4.5-5.5	<2.7	1.3	<1.6	28-40	40-100	<0.6
PATIENT	6.0	2.15	1.15	1.4	45	85	0.2
CANINE CARDIAC PARAMETERS	HR (BPM)	AV VMAX (m/s)	PV MAX (m/s)	BODY WEIGHT (kg)	LA 2D short axis Base view (cm)	LVIDd Avg; 2D and m-mode short axis (cm)	LVIDs Avg; 2D and m-mode short axis (cm)
NORMAL PARAMETER	50-100	0.7-1.7	0.7-1.6	BELOW	BELOW	BELOW	BELOW
PATIENT	130	1.3	--		3.7	3.5	

## IMAGING PERFORMED BY

Sara Hansen

## HOSPITAL NAME

Santa Clara AH

## REFERRING VET

Dr. Brasted-Maki

## INVOICE

39479

## DATE

7/13/22

## Cardiac Presentation

The echocardiogram in this patient demonstrated normal **left atrial** size based on 3 different LA measurement methods. Chamber volumes and echogenicity were normal. The cranial and caudal **mitral** valve leaflets presented vegetative thickening consistent with endocardiosis. Doppler indicated measurable insufficiency, moderate and centralized. The **left ventricle** presented thicknesses with linear contour and was not dilated nor restricted. The **myocardium** presented normal echogenicity without subjective evidence of significant fibrotic or ischemic disease. **Contractility** of the ventricular walls was adequate and in normal range for this patient evidenced by the fractional shortening measurement and subjective evaluation of the different regions of the myocardium. The **left ventricular outflow** tract demonstrated normal laminar flow and subjective structural integrity. The **right atrium** and auricle revealed normal size, structure and content. No evidence of masses was noted or chamber overload. Minor **tricuspid** insufficiency noted. The **right ventricle** was of normal size (1/3 diameter of LV), chordae structure, myocardial echogenicity and thickness. **Pulmonic** tract assessment revealed normal valve structure, laminar flow, and diameter (approx. 1:1 pa/ao ratio). No visible **pericardial** or free pleura fluid was noted. No echographically detectable evidence of infiltrative disease was visible. The cranial **mediastinum and pericardial regions** were free of masses in the visible window.



## PATIENT *Urinary System*

Gunnar Baratti The **urinary bladder**, trigone, and pelvic urethra presented normal thicknesses and normal tone. The ureters were not visible which is normal. No uroliths or sediment were visualized and anechoic urine was present. No evidence of inflammatory or neoplastic changes were noted. Ureteral papillae were normal. The pelvic urethra was imaged 2.0 cm beyond the cystourethral junction.

## SPECIES

Canine

## BREED

Standard Poodle

## SEX

Neutered Male

## AGE

11 Years

## WEIGHT

76 Pounds

## INTERPRETED BY

Eric Lindquist, DMV

DABVP, Cert. IVUSS

## IMAGING PERFORMED BY

Sara Hansen

## HOSPITAL NAME

Santa Clara AH

## REFERRING VET

Dr. Brasted-Maki

## INVOICE

39479

## DATE

7/13/22

The **kidneys** revealed normal size and structure, corticomedullary definition and ratio for this age. The cortices presented largely uniform texture with normal echogenic relationship to liver and spleen. Medullary structure differed distinctly from the cortex and no evidence of pelvic dilation was present. The capsules were acceptably uniform without significant irregularities. The left kidney measured 6.9 cm. The right kidney measured 7.93 cm.

## *Adrenal Glands*

Both **adrenal glands** were visualized and recognized as having normal shape, size, position and echogenicity for this breed. The phrenic vasculature, glandular echogenicity and detail were unremarkable. Capsule, cortex, and medullary definition were normal for this age patient. The right adrenal gland measured 3.47 cm x 2.06 cm at the cranial pole and 0.58 cm at the caudal pole. The left adrenal gland measured 3.51 cm x 0.57 cm at the caudal pole and 0.81 cm at the cranial pole.

## *Spleen*

The **spleen** revealed an expansive, mixed hypoechoic parenchymal mass measuring approximately 6.0 cm. No evidence of cavitation. No evidence of free fluid.

## *Liver*

The **liver** images submitted revealed subjectively normal liver size, contour, and structure. Parenchymal echogenicity was naturally coarse and hypoechoic to the spleen. Vascular and biliary tracts were of normal volume with no evidence of congestion. The gallbladder presented acceptably thin walls with primarily anechoic content. The cystic and common bile ducts were normal. No pathological hepatic lymphadenopathy was evident. No overt structural evidence of inflammatory, infiltrative or regenerative pathology was evident.

## *Gastrointestinal*

A minor amount of non-shadowing, non-obstructive ingesta was noted in the **stomach**. Transit of chyme into the small intestine was normal. Curvilinear patterns were maintained throughout the GI tract. No evidence of pathology. Small and large intestine demonstrated normal luminal chyme and stool consistency respectively. No obstructive or overt infiltrative disease was noted. No associated abnormal lymphatic activity was noted.

## *Pancreas*

The base and limbs of the **pancreas** were observed to be largely isoechoic to surrounding omental fat. Pancreatic duct and capsular contour were acceptably normal and parenchyma respected normal curvilinear patterns. No overt evidence of active inflammatory or neoplastic disease was noted.

## PRIMARY FINDINGS

- Stage B1 valvular disease, compensated
- Splenic mass



**PATIENT      SECONDARY FINDINGS**

Gunnar Baratti      • Gastric ingesta

**SPECIES      INTERPRETATION OF THE FINDINGS & FURTHER RECOMMENDATIONS**

Canine      No evidence of masses. No overt contraindication to anesthetic procedure. B1: The heart is stable without clinical disease. No overt contraindication for anesthesia of brief to moderate duration. I suggest Torbutrol premed, Propofol induction, Isoflor maintenance or similar protocol if anesthesia is desired. Blood pressure recommended if not already performed and target white coat negative systolic pressure of < 160 mmHg. If higher than this ACE-inhibitor is suggested to reach this level. Recheck echocardiogram is recommended in 6 months, earlier if murmur grade increases or clinical signs initiate.

**BREED**

Standard Poodle

**SEX**

Neutered Male

Chest radiographs and exploratory splenectomy with liver biopsy indicated to rule out micrometastasis. Hemangiosarcoma, round cell neoplasia, benign hyperplasia all possible.

**AGE**

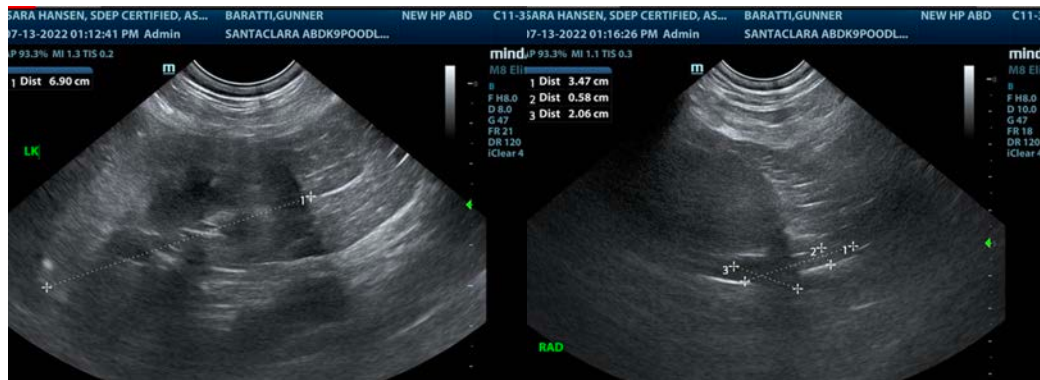
11 Years

**WEIGHT**

76 Pounds

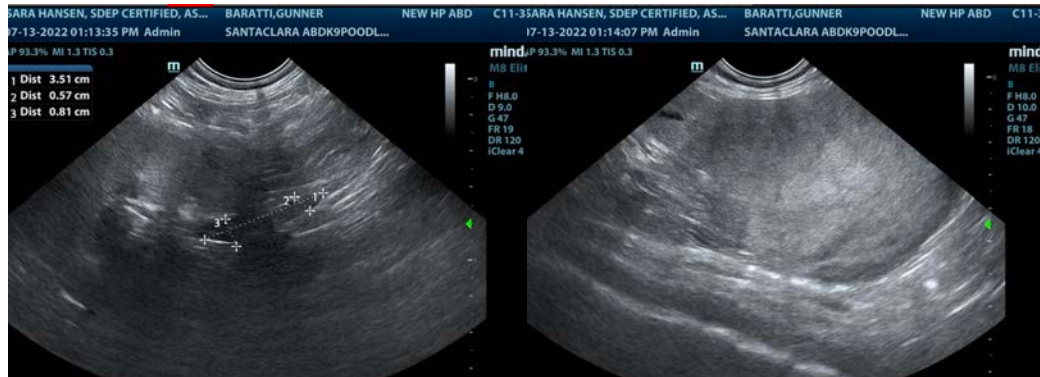
**INTERPRETED BY**

Eric Lindquist, DMV  
 DABVP, Cert. IVUSS



**IMAGING PERFORMED BY**

Sara Hansen



**HOSPITAL NAME**

Santa Clara AH

**REFERRING VET**

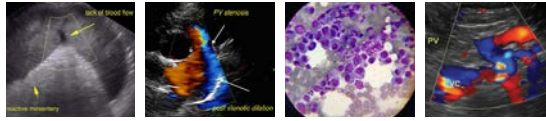
Dr. Brasted-Maki

**INVOICE**

39479

**DATE**

7/13/22



**PATIENT**

Gunnar Baratti

**SPECIES**

Canine

**BREED**

Standard Poodle

**SEX**

Neutered Male

**AGE**

11 Years

**WEIGHT**

76 Pounds

**INTERPRETED BY**

Eric Lindquist, DMV  
DABVP, Cert. IVUSS

**IMAGING PERFORMED BY**

Sara Hansen

**HOSPITAL NAME**

Santa Clara AH

**REFERRING VET**

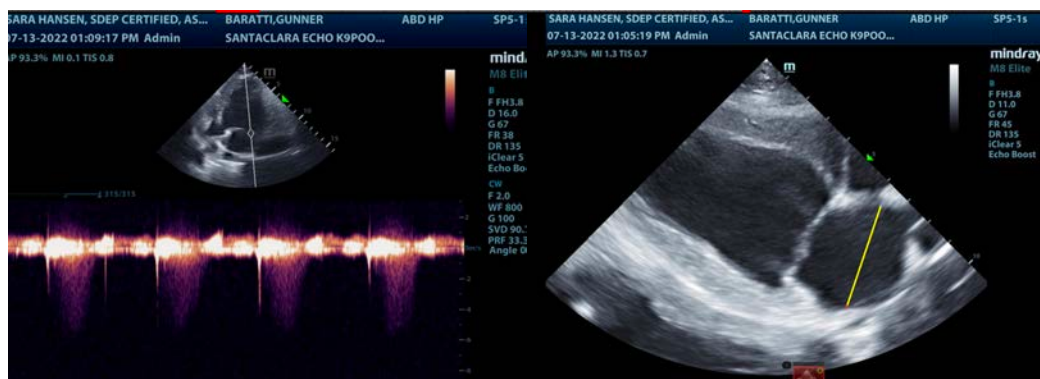
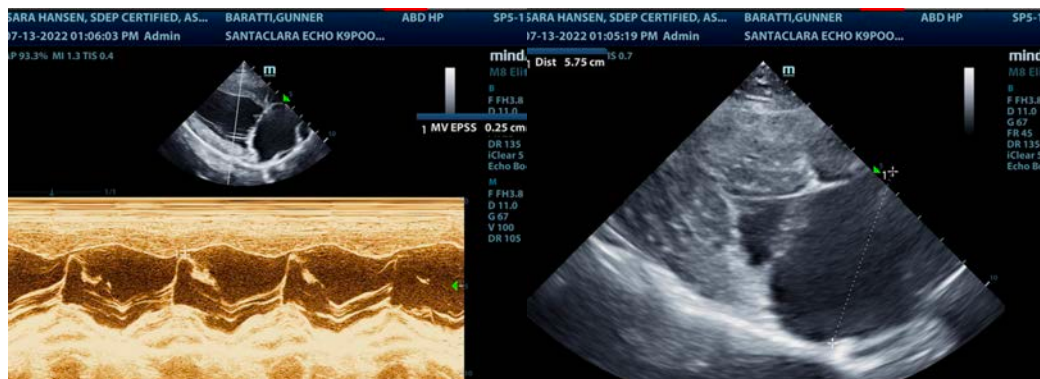
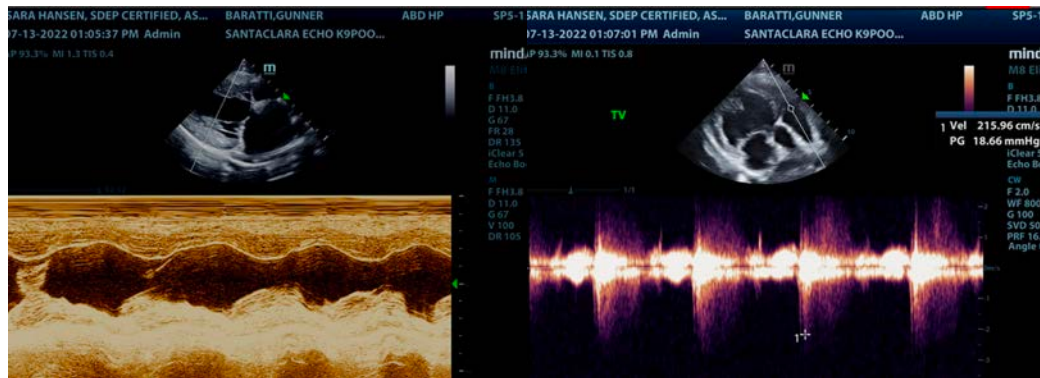
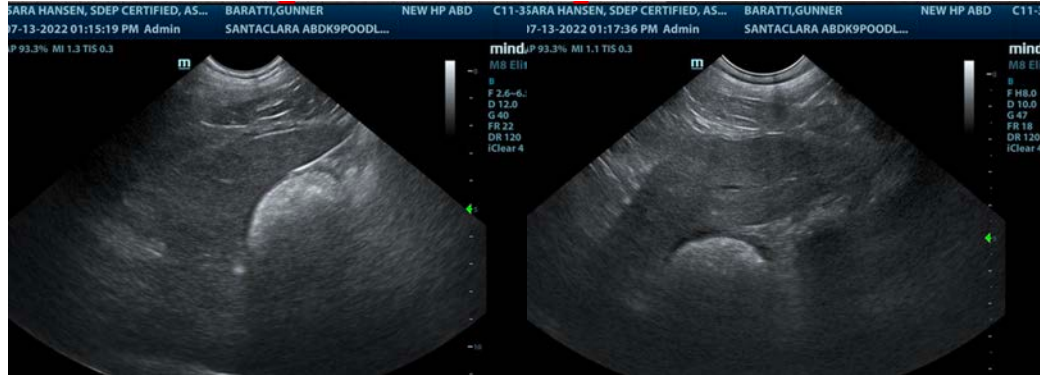Dr. Brasted-Maki

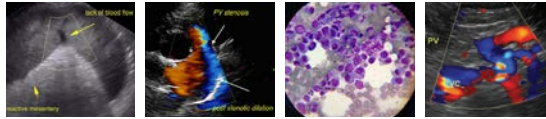
**INVOICE**

39479

**DATE**

7/13/22





**PATIENT**

Gunnar Baratti

**SPECIES**

Canine

**BREED**

Standard Poodle

**SEX**

Neutered Male

**AGE**

11 Years

**WEIGHT**

76 Pounds

**INTERPRETED BY**

Eric Lindquist, DMV  
DABVP, Cert. IVUSS

**IMAGING PERFORMED BY**

Sara Hansen

**HOSPITAL NAME**

Santa Clara AH

**REFERRING VET**

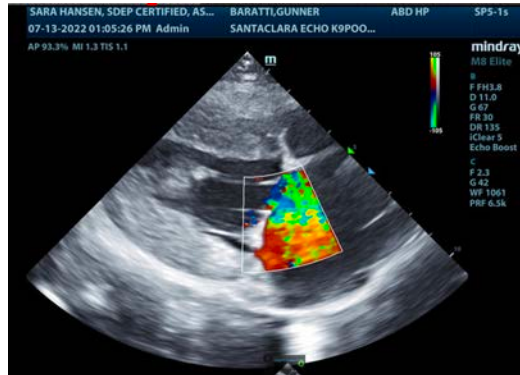
Dr. Brasted-Maki

**INVOICE**

39479

**DATE**

7/13/22



The information and recommendations provided are based on the images presented by the referring veterinarian/sonographer. No evaluation can be communicated regarding pathology that was not visible in the image/video clips provided.

Thank you for this referral. If the clinical or image interpretation does not parallel your findings or if I can be of any further assistance please contact me.

Eric Lindquist, DMV, DABVP, Cert. IVUSS, CEO of SonoPath.com

[info@SonoPath.com](mailto:info@SonoPath.com)