



PATIENT

Anna Mastanduno

SPECIES

Canine

BREED

Spaniel Mix

SEX

Spayed Female

AGE

15 Years

WEIGHT

17 Pounds

INTERPRETED BY

Eric Lindquist, DMV
DABVP, Cert. IVUSS

IMAGING PERFORMED BY

Jenn

HOSPITAL NAME

Rockaway AH

REFERRING VET

Dr. Maniar

INVOICE

16617

DATE

7/13/22

PRESENTING CLINICAL SIGNS

History: azotemia, hyporexia, lethargy, suspect degenerative renal dz owner wants to r/o neoplasia
Current meds Plasma Lyte Metro Pepcid

Abnormal PE/Chem/CBC/UA Results: Neu 13K Creat 3.8 BUN 104 Phos 14 Glob 6.4 ALT 208 4dx neg

ULTRASONOGRAPHIC EXAMINATION OF THE ABDOMEN

Urinary System

The **urinary bladder** presented a relatively uniform thickening of the cranioventral and craniodorsal mucosae with micropolypoid mucosal changes without involvement of the submucosae. The urine presented some echogenicity consistent with suspended debris. No evidence of urethral pathology was present. This presentation is most consistent with chronic cystitis. Technically transitional cell carcinoma cannot be ruled out without histopathological review but is not overtly suspected based on this pattern. Cystocentesis and urine culture +/- pathological review of urine cytology would be warranted. No overt calculi were present at this time. This is a moderate change.

The **kidneys** were mildly subnormal in size with normal structure, corticomedullary definition and ratio (cortex 1/3 of medulla) were essentially maintained with some moderate age-related loss of curvilinear patterns regarding the capsule and C/M junction. The cortices presented largely uniform texture with some increased echogenicity expected for his age patient. Medullary structure differed distinctly from that of the cortex and no evidence of pelvic dilation was present. Pinpoint mineralizations were noted, nonobstructive. The right kidney measured 5.11 cm. The left kidney measured 4.38 cm. These changes do not appear to be end-stage.

Adrenal Glands

Both **adrenal glands** were visualized and recognized as having normal shape, size, position and echogenicity for this breed. The phrenic vasculature, glandular echogenicity and detail were unremarkable. Capsule, cortex, and medullary definition were normal for this age patient. The left adrenal gland measured 1.89 cm x 0.49 cm at the caudal pole and 0.56 cm at the cranial pole. The right adrenal gland measured 0.5 cm.

Spleen

The **spleen** was largely smooth with subtle heterogeneous parenchymal changes while maintaining normal echogenic relationship to the liver and kidney. These changes are consistent with normal age-related alteration. The capsule was smooth without noticeable impingement from within the spleen or from pathology in the adjacent abdomen. The splenic vasculature demonstrated normal volume without signs of congestion or significant contraction. No evidence of active acute or chronic inflammatory, neoplastic, or infarctual changes were noted. This is a mild change.

Liver

The **liver** images from right and left intercostal as well as subcostal views revealed subjectively normal liver size, contour, and structure. Some minor age-related parenchymal remodeling was noted but likely not clinically significant at this time. Vascular tracts were of normal volume and no evidence of congestion was noted. No overt evidence of active inflammatory, infiltrative or regenerative pathology was noted but should be paired with current or past LE elevations regarding any clinical significance



PATIENT

Anna Mastanduno

to this presentation. The hepatic lymph nodes were unremarkable. The gallbladder was mildly over distended with suspended and dependent debris, yet not to the level of emerging mucocele, yet sludge appears to be mildly excessive. No adjunctive inflammation was noted.

SPECIES

Canine

Gastrointestinal

BREED

Spaniel Mix

Examination of the **gastrointestinal tract** revealed a stomach and intestine free of stasis, of normal wall thickness, acceptable curvilinear mural detail, and peristaltic activity. Small and large intestine demonstrated normal luminal chyme and stool consistency respectively. No obstructive or overt infiltrative disease was noted. No associated abnormal lymphatic activity was noted.

SEX

Spayed Female

Pancreas

The base and limbs of the **pancreas** were observed to be largely isoechoic to surrounding omental fat. Pancreatic duct and capsular contour were acceptably normal and parenchyma respected normal curvilinear patterns. No overt evidence of active inflammatory or neoplastic disease was noted.

AGE

15 Years

ULTRASONOGRAPHIC FINDINGS

WEIGHT

17 Pounds

- Chronic cystitis bladder pattern
- Moderate degenerative renal changes
- Age-related splenic changes
- Age-related hepatic changes with gallbladder sludge

INTERPRETED BY

Eric Lindquist, DMV
DABVP, Cert. IVUSS

INTERPRETATION OF THE FINDINGS & FURTHER RECOMMENDATIONS

Acute on chronic renal failure suspected. Complicated factors, such as leptospirosis, hypertension, prerenal disease and UTI should all be considered. 72-hour IV fluid protocol and urine culture and sensitivity are indicated. Ursodiol therapy is warranted in the long term. Good to guarded prognosis depending upon response to therapy.

IMAGING PERFORMED BY

Jenn

HOSPITAL NAME

Rockaway AH

REFERRING VET

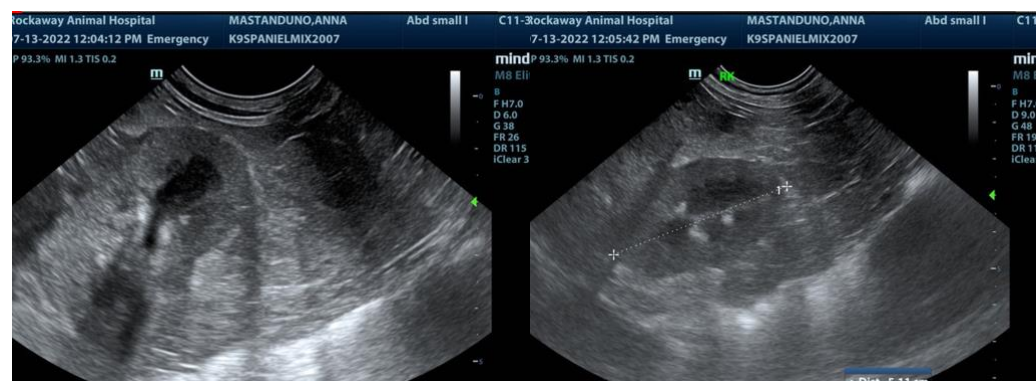
Dr. Maniar

INVOICE

16617

DATE

7/13/22





PATIENT

Anna Mastanduno

SPECIES

Canine

BREED

Spaniel Mix

SEX

Spayed Female

AGE

15 Years

WEIGHT

17 Pounds

INTERPRETED BY

Eric Lindquist, DMV
DABVP, Cert. IVUSS

IMAGING PERFORMED BY

Jenn

HOSPITAL NAME

Rockaway AH

REFERRING VET

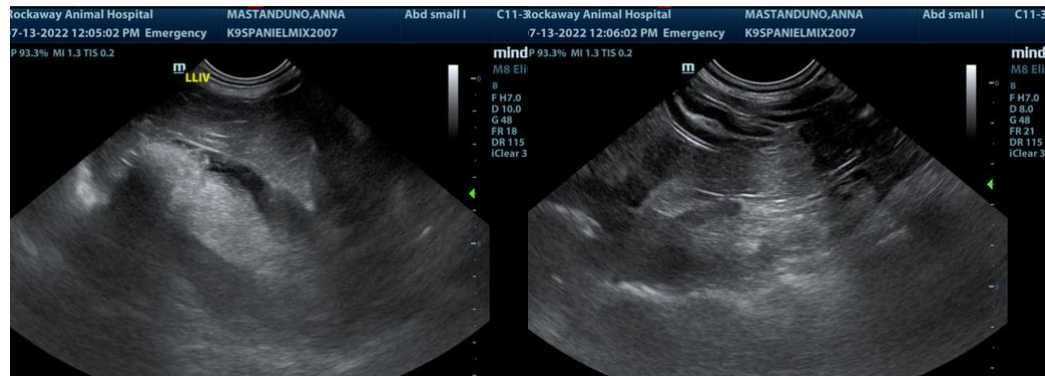
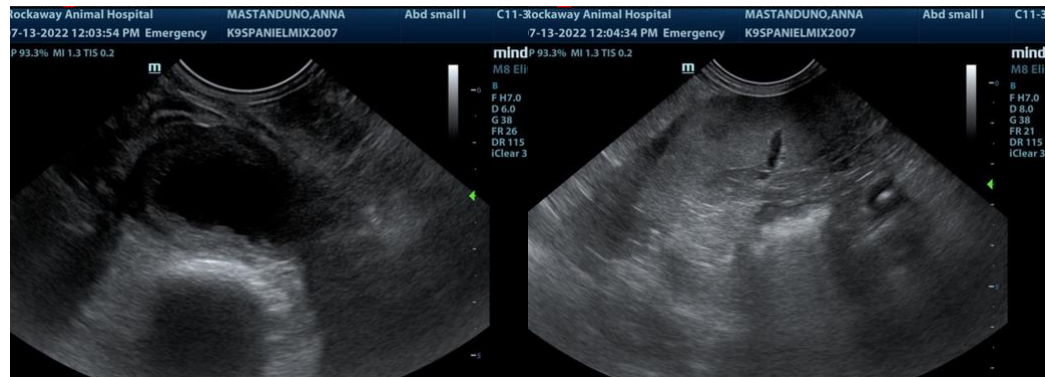
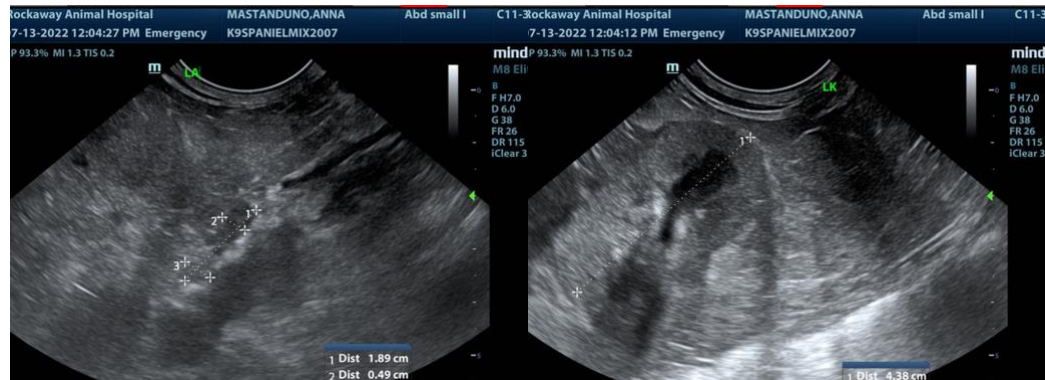
Dr. Maniar

INVOICE

16617

DATE

7/13/22



The information and recommendations provided are based on the images presented by the referring veterinarian. No evaluation can be communicated regarding pathology that was not visible in the image/video clips provided.

Thank you for this referral. If the clinical or image interpretation does not parallel your findings or if I can be of any further assistance please contact me.

Eric Lindquist, DMV, DABVP, Cert. IVUSS, CEO of SonoPath.com
info@SonoPath.com