

PATIENT

Pumpkin Fly Away
Home

SPECIES

Canine

BREED

Rottweiler

SEX

Male

AGE

6 weeks

WEIGHT

2.8 lbs

INTERPRETED BY

Eric Lindquist, DMV
DABVP, Cert. IVUSS

IMAGING PERFORMED BY

Jenn

HOSPITAL NAME

Rockaway AH

REFERRING VET

Dr. Maniar

INVOICE

76094

DATE

7/12/23

PRESENTING CLINICAL SIGNS

History: URI anorexia lethargic

ULTRASONOGRAPHIC EXAMINATION OF THE ABDOMEN

Urinary System

The **urinary bladder**, trigone, and pelvic urethra presented normal thicknesses and normal tone. The ureters were not visible which is normal. No uroliths or sediment were visualized and anechoic urine was present. No evidence of inflammatory or neoplastic changes was noted. Ureteral papillae were normal.

The **kidneys** revealed normal size and structure, corticomedullary definition and ratio for this age. The cortices presented largely uniform texture with normal echogenic relationship to liver and spleen. Medullary structure differed distinctly from the cortex and no evidence of pelvic dilation was present. The capsules were acceptably uniform without significant irregularities. The kidneys measured 4.0 cm each.

Adrenal Glands

The region of the **adrenal glands** were imaged with no evidence of pathology.

Spleen

The **spleen** presented a smooth homogeneous parenchyma hyperechoic to liver and renal cortical parenchyma. The capsule was smooth without noticeable expansion or deviation from within the spleen or adjacent pathology. The splenic vasculature demonstrated normal volume without signs of congestion or thrombosis. No sonographic evidence of acute or chronic inflammatory, neoplastic, or infarctual changes was noted.

Liver

The **liver** was mildly subnormal in size and was normal in contour and structure. Parenchymal echogenicity was naturally coarse and hypoechoic to the spleen. Vascular and biliary tracts were of normal volume with no evidence of congestion. The gallbladder presented acceptably thin walls with primarily anechoic content. The cystic and common bile ducts were normal. No pathological hepatic lymphadenopathy was evident. No overt structural evidence of inflammatory, infiltrative or regenerative pathology was evident.

Gastrointestinal

The **stomach** was over distended with chyme. This is consistent with a post prandial presentation. The small intestines and colon were unremarkable.



PATIENT

Pumpkin Fly Away Home

SPECIES

Canine

BREED

Rottweiler

SEX

Male

AGE

6 weeks

WEIGHT

2.8 lbs

INTERPRETED BY

Eric Lindquist, DMV
DABVP, Cert. IVUSS

IMAGING PERFORMED BY

Jenn

HOSPITAL NAME

Rockaway AH

REFERRING VET

Dr. Maniar

INVOICE

76094

DATE

7/12/23

Pancreas

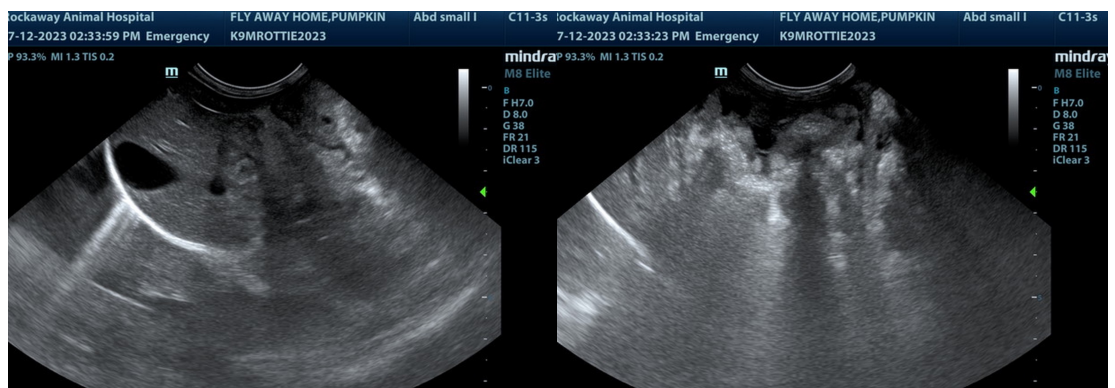
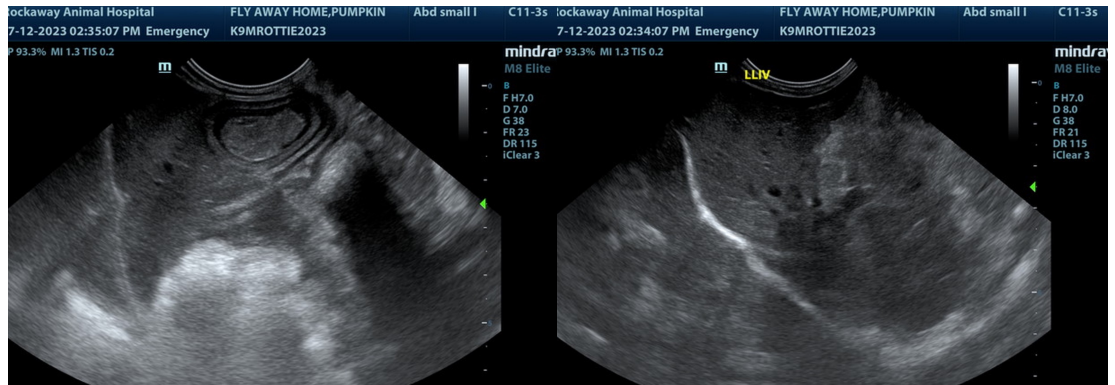
The base and limbs of the **pancreas** were observed to be largely isoechoic to surrounding omental fat. Pancreatic duct and capsular contour were acceptably normal and parenchyma respected normal curvilinear patterns. No overt evidence of active inflammatory or neoplastic disease was noted.

ULTRASONOGRAPHIC FINDINGS

Very full stomach. Possible hiatal hernia

INTERPRETATION OF THE FINDINGS & FURTHER RECOMMENDATIONS

The ingesta in the stomach appeared to impinge upon and enter into the gastroesophageal inlet. I cannot rule out underlying hiatal hernia. Radiographic evaluation is recommended at a more developed age is recommended to assess for potential hiatal hernia. There was no other evidence of pathology. The cause of lethargy is not overtly evident in the abdomen.





PATIENT

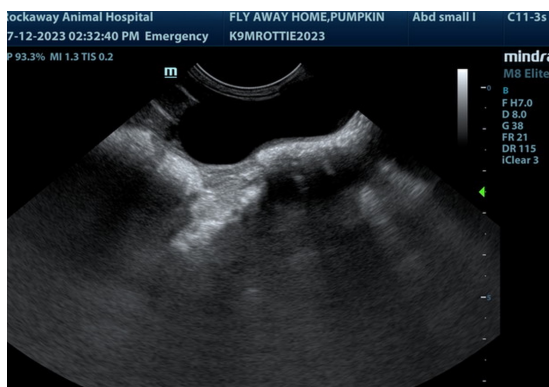Pumpkin Fly Away Home

SPECIES

Canine

BREED

Rottweiler



SEX

Male

AGE

6 weeks

WEIGHT

2.8 lbs

The information and recommendations provided are based on the images presented by the referring veterinarian/sonographer. No evaluation can be communicated regarding pathology that was not visible in the image/video clips provided.

Thank you for this referral. If the clinical or image interpretation does not parallel your findings or if I can be of any further assistance please contact me.

Eric Lindquist, DMV, DABVP, Cert. IVUSS, CEO of SonoPath.com
info@SonoPath.com

INTERPRETED BY

Eric Lindquist, DMV
DABVP, Cert. IVUSS

IMAGING PERFORMED BY

Jenn

HOSPITAL NAME

Rockaway AH

REFERRING VET

Dr. Maniar

INVOICE

76094

DATE

7/12/23