



**PATIENT PRESENTING CLINICAL SIGNS**

June Shea History: Vomiting and diarrhea for a few days. Gave chicken and rice but not able to keep much down  
Abnormal PE/Chem/CBC/UA Results: Pending

**SPECIES ULTRASONOGRAPHIC EXAMINATION OF THE ABDOMEN**

Canine **Urinary System**

**BREED** The **bladder** in this patient was mildly thickened with slight echogenic mural changes. No calculi or masses were noted. Slight micropolypoid changes were noted. This is a frequent finding in older animals and may be linked to a history of chronic urinary tract infection or active urinary tract infection. Urinalysis would be recommended with culture if any evidence of inflammatory sediment is present. The region of the trigone and visible pelvic urethra were normal.

Pit Cross

**SEX**

Spayed feamle

**AGE**

4 years

The **kidneys** revealed normal size and structure, corticomedullary definition and ratio for this age. The cortices presented largely uniform texture with normal echogenic relationship to liver and spleen. Medullary structure differed distinctly from the cortex and no evidence of pelvic dilation was present. The capsules were acceptably uniform without significant irregularities. The left kidney measured 6.1 cm. The right kidney measured 6.7 cm.

**WEIGHT**

55.6 lbs

**Adrenal Glands**

Both **adrenal glands** were visualized and recognized as having normal shape, size, position and echogenicity for this breed. The phrenic vasculature, glandular echogenicity and detail were unremarkable. Capsule, cortex, and medullary definition were normal for this age patient. The right adrenal gland measured 3.06 x 0.8 cm. The left adrenal gland measured 2.34 x 0.5 cm.

**INTERPRETED BY**

Eric Lindquist, DMV  
DABVP, Cert. IVUSS

**Spleen**

The **spleen** presented a smooth homogeneous parenchyma hyperechoic to liver and renal cortical parenchyma. The capsule was smooth without noticeable expansion or deviation from within the spleen or adjacent pathology. The splenic vasculature demonstrated normal volume without signs of congestion or thrombosis. No sonographic evidence of acute or chronic inflammatory, neoplastic, or infarctual changes was noted.

**IMAGING PERFORMED BY**

Dr. Rodriguez

**HOSPITAL NAME**

Foxfield VS

**Liver**

**REFERRING VET**

Dr. Rodriguez

The **liver** images submitted revealed subjectively normal liver size, contour, and structure. Parenchymal echogenicity was naturally coarse and hypoechoic to the spleen. Vascular and biliary tracts were of normal volume with no evidence of congestion. The gallbladder presented acceptably thin walls with primarily anechoic content. The cystic and common bile ducts were normal. No pathological hepatic lymphadenopathy was evident. No overt structural evidence of inflammatory, infiltrative or regenerative pathology was evident.

**INVOICE**

76120

**DATE**

7/12/23



**PATIENT**

June Shea

**SPECIES**

Canine

**BREED**

Pit Cross

**SEX**

Spayed female

**AGE**

4 years

**WEIGHT**

55.6 lbs

**INTERPRETED BY**

Eric Lindquist, DMV  
DABVP, Cert. IVUS

**IMAGING PERFORMED BY**

Dr. Rodriguez

**HOSPITAL NAME**

Foxfield VS

**REFERRING VET**

Dr. Rodriguez

**INVOICE**

76120

**DATE**

7/12/23

**Gastrointestinal**

The **gastrointestinal** presentation revealed mild uniform prominence of the gastric mucosa as well as areas of "ropy" small intestinal wall with slight disruption of the normal 1:3 muscularis/mucosal ratio. The intestinal submucosa was slightly irregular, thickened and hyperechoic suggestive of low grade, chronic disease. The mesenteric lymph nodes are enlarged and measured 3.6 x 1.4 cm.

**Pancreas**

The base and limbs of the **pancreas** were observed to be largely isoechoic to surrounding omental fat. Pancreatic duct and capsular contour were acceptably normal and parenchyma respected normal curvilinear patterns. No overt evidence of active inflammatory or neoplastic disease was noted.

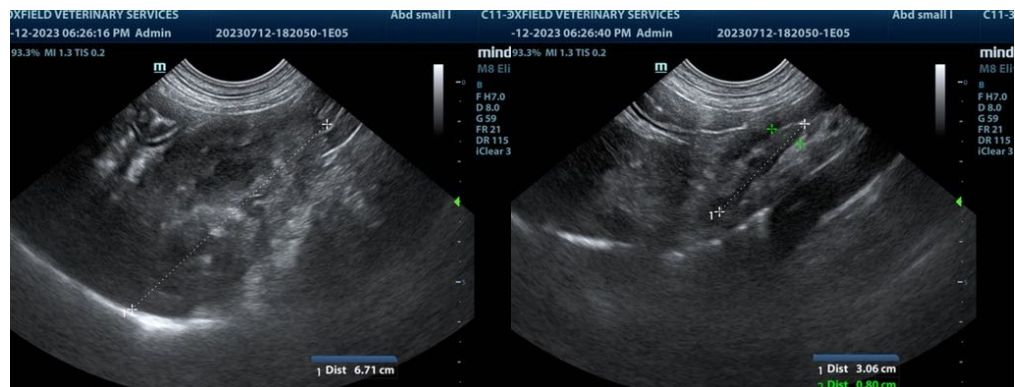
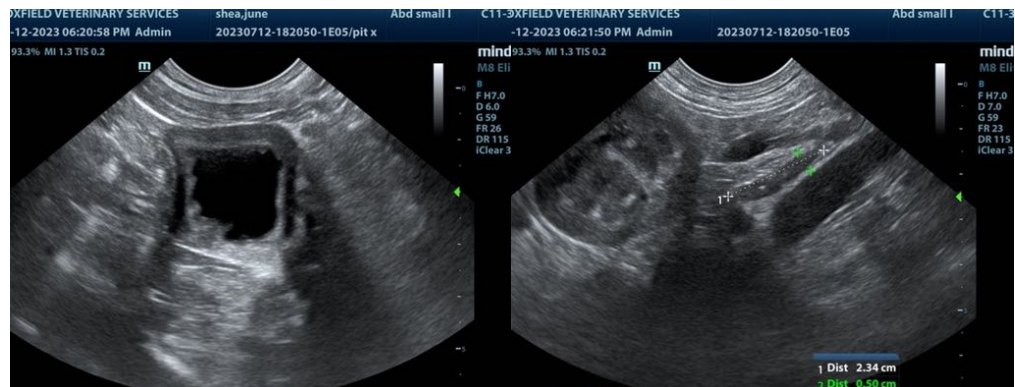
**ULTRASONOGRAPHIC FINDINGS**

Mesenteric lymphadenopathy. Reactive nodes versus emerging neoplasia.

Minor IBD GI pattern.

**INTERPRETATION OF THE FINDINGS & FURTHER RECOMMENDATIONS**

FNA, cytology and culture are indicated. There was no evidence of obstruction. The prognosis is guarded depending on cytology results.





**PATIENT**

June Shea

**SPECIES**

Canine

**BREED**

Pit Cross

**SEX**

Spayed female

**AGE**

4 years

**WEIGHT**

55.6 lbs

**INTERPRETED BY**

Eric Lindquist, DMV  
DABVP, Cert. IVUSS

**IMAGING PERFORMED BY**

Dr. Rodriguez

**HOSPITAL NAME**

Foxfield VS

**REFERRING VET**

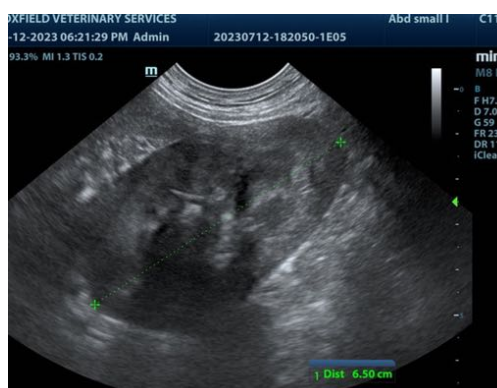Dr. Rodriguez

**INVOICE**

76120

**DATE**

7/12/23



The information and recommendations provided are based on the images presented by the referring veterinarian/sonographer. No evaluation can be communicated regarding pathology that was not visible in the image/video clips provided.

Thank you for this referral. If the clinical or image interpretation does not parallel your findings or if I can be of any further assistance please contact me.

**Eric Lindquist**, DMV, DABVP, Cert. IVUSS, CEO of SonoPath.com  
info@SonoPath.com