



PATIENT

Woody Howard

SPECIES

Feline

BREED

Domestic Shorthair

SEX

Neutered male

AGE

12 years

WEIGHT

14 lbs

PRESENTING CLINICAL SIGNS

History of IBD. Sedated with Gabapentin PO, added Butorphanol IV.
Abnormal PE/Chem/CBC/UA Results: PE: Anisocoria, overweight, Grade 3/6 systolic heart murmur. BW: proBNP 171, BUN 38, K 3.6, TP 6.2. Hct 25 %. BP: WNL. IOP: WNL. RADS (attached): enlarged R atrium.

ULTRASONOGRAPHIC EXAMINATION OF THE HEART

The echocardiogram in this patient demonstrated normal **left atrial** size based on 3 separate LA measurements. The cranial and caudal **mitral** valve leaflets presented normal linear structure and kinetics. The **left ventricle** presented normal thicknesses with linear contour and was not dilated nor restricted. The **myocardium** presented normal echogenicity without subjective evidence of significant fibrotic or ischemic disease. **Contractility** of the ventricular walls was adequate and in normal range for this patient evidenced by the fractional shortening measurement and subjective evaluation of the different regions and angles of the myocardium. The **left ventricular outflow** tract demonstrated normal laminar flow and subjective structural integrity. The **right atrium** and auricle revealed normal size, structure and content. No evidence of masses was noted or chamber overload. **Tricuspid** valvular assessment demonstrated adequate linear morphology and kinetics. The **right ventricle** was of normal size (1/3 diameter of LV), chordae structure, myocardial echogenicity and thickness. **Pulmonic** tract assessment revealed normal valve structure, laminar flow, and diameter (approx. 1:1 pa/ao ratio). No visible **pericardial** or free pleura fluid was noted or extra cardiac pathology in the visible planes. The cranial **mediastinum** and **pericardial** regions were free of masses in the visible window. A moderate amount of extracardiac fat noted adjacent to the pulmonary artery. The fat accumulation measured 2.5 cm.

INTERPRETED BY

Eric Lindquist, DMV
DABVP, Cert. IVUSS

IMAGING PERFORMED BY

Dr. Norman

HOSPITAL NAME

Scanvet

REFERRING VET

Dr. Ebersole

INVOICE

31610

DATE

7/12/22

FELINE CARDIAC PARAMETERS	BODY WEIGHT (kg)	HR (BPM)	IVSd (cm)	LVIDd (cm)	LVWd (cm)	FS (%)	EF (%)
NORMAL PARAMETER	-----	150-240	0.3-0.6	1.0-2.1	0.25-0.6	35-67	80-100
PATIENT		NM					
FELINE CARDIAC PARAMETERS	LA/AO (Boon)	LA/AO HEART BASE (Sisson)	LA 2D 4-chamber long axis AS to FW (Sisson) (cm)	LVOT VEL. (m/s)	RVOT VEL. (m/s)	IVRT (m)	
NORMAL PARAMETER	<1.5	0.88-1.79	0.7-1.7	<1.6	<1.3	40-60	
PATIENT		1.57	1.2 max	1.39	0.9	NM	
Adapted from June Boon, Veterinary Echocardiography, 1998 Sisson D et al. JVIM 1991; 5: 232, Jacobs et al. Am J Vet Res 1985; 46:1705							

ULTRASONOGRAPHIC FINDINGS

Normal echocardiogram, with extracardiac fat. May create a density in the mediastinum on radiographs.



PATIENT

Woody Howard

SPECIES

Feline

BREED

Domestic Shorthair

SEX

Neutered male

AGE

12 years

WEIGHT

14 lbs

INTERPRETED BY

Eric Lindquist, DMV
DABVP, Cert. IVUSS

IMAGING PERFORMED BY

Dr. Norman

HOSPITAL NAME

Scanvet

REFERRING VET

Dr. Ebersole

INVOICE

31610

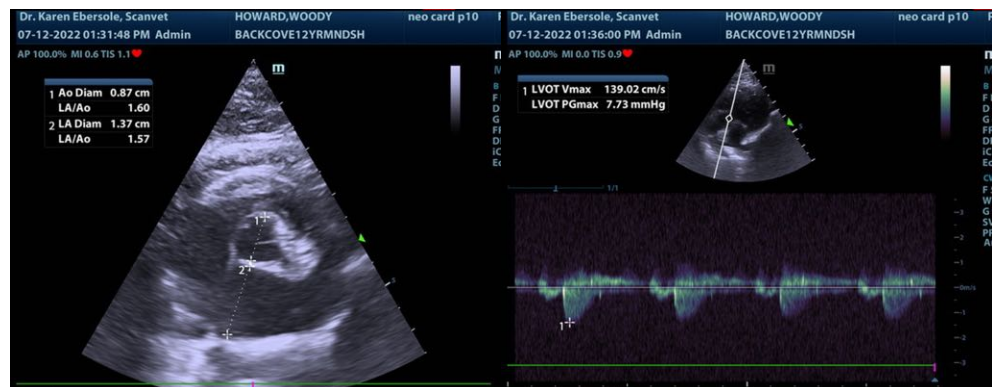
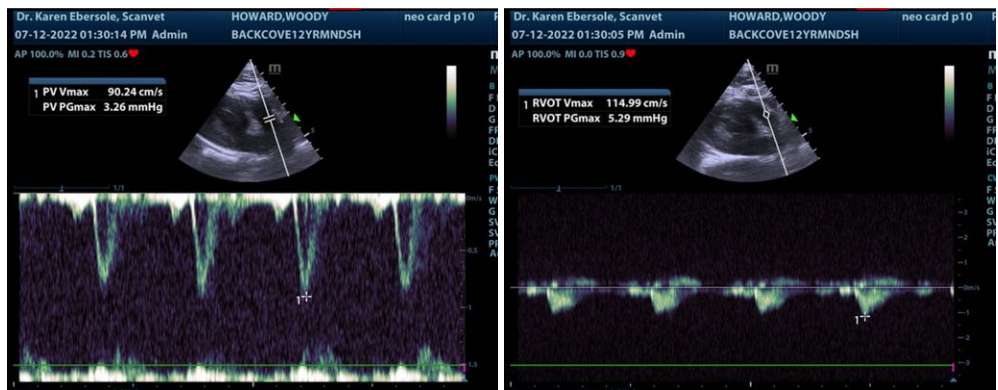
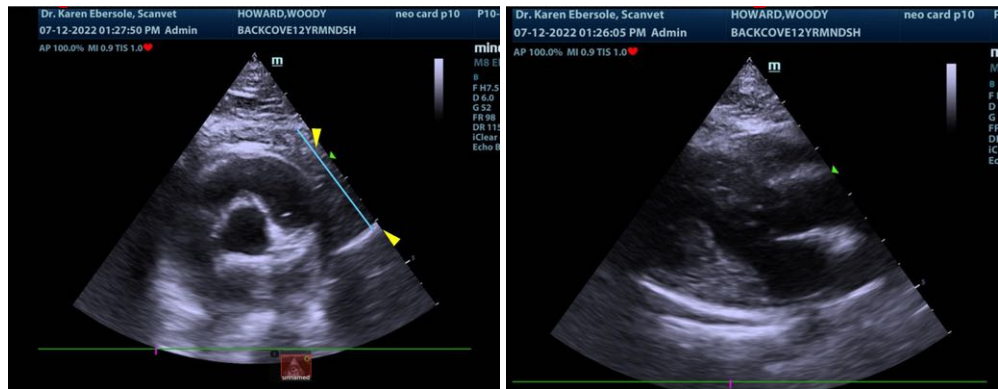
DATE

7/12/22

INTERPRETATION OF THE FINDINGS & FURTHER RECOMMENDATIONS

There was no evidence of pathology present. The cause of murmur is unclear.

Flow murmurs can be caused by volume shifts, anemia, excitable/tachycardic state, DRVOTO (Dynamic Right Ventricular Outflow Obstruction), or even simple stethoscope pressure upon clinical exam. These flow murmurs are typically benign and may develop often later in life theoretically owing to age related clinically insignificant changes of the heart. If the patient is recently clinical for anorexia, weight loss or metabolic disturbances, an abdominal sonogram and full workup may be appropriate to assess underlying clinical systemic causes of a newly developed flow murmur.





PATIENT

Woody Howard

SPECIES

Feline

BREED

Domestic Shorthair

SEX

Neutered male

AGE

12 years

WEIGHT

14 lbs

INTERPRETED BY

Eric Lindquist, DMV
DABVP, Cert. IVUSS

IMAGING PERFORMED BY

Dr. Norman

HOSPITAL NAME

Scanvet

REFERRING VET

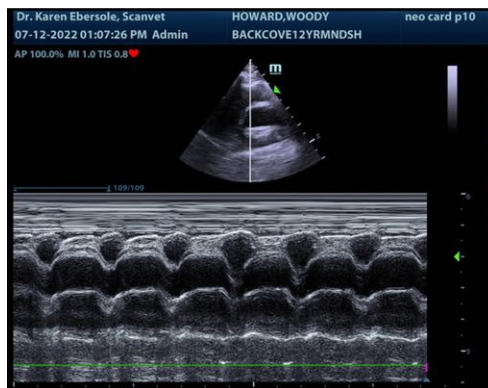
Dr. Ebersole

INVOICE

31610

DATE

7/12/22



The information and recommendations provided are based on the images presented by the referring veterinarian/sonographer. No evaluation can be communicated regarding pathology that was not visible in the image/video clips provided.

Thank you for this referral. If the clinical or image interpretation does not parallel your findings or if I can be of any further assistance please contact me.

Eric Lindquist, DMV, DABVP, Cert. IVUSS, CEO of SonoPath.com
info@SonoPath.com