



## PATIENT

Rocky Lajeunesse

## SPECIES

Canine

## BREED

Lab Mix

## SEX

Neutered Male

## AGE

11 1/2 Years

## WEIGHT

32.9 kg

## INTERPRETED BY

Eric Lindquist, DMV  
DABVP, Cert. IVUSS

## IMAGING PERFORMED BY

Dr. Trudeau

## HOSPITAL NAME

Petworks VH

## REFERRING VET

Dr. Trudeau

## INVOICE

16596

## DATE

7/12/22

## PRESENTING CLINICAL SIGNS

History: anorexic x2 days with v/d; painful on abdominal palpation; dumpy; concerned for GB mucocele - images are limited to just the GB /liver at this time

Abnormal PE/Chem/CBC/UA Results: rads: enlarged liver cpli - abnormal Chem - slight increased ALP otherwise NSF AFAST u/s at local emerg clinic - concerned about GB

\*\*7 stills, and 15 videos were submitted.

## LIMITED ULTRASONOGRAPHIC EXAMINATION

The liver was slightly heterogeneous with minor increased portal markings, yet uniform. Hyperechoic lipogranulomatous type changes were noted in the liver with hypoechoic nodules and minor capsular expansion.

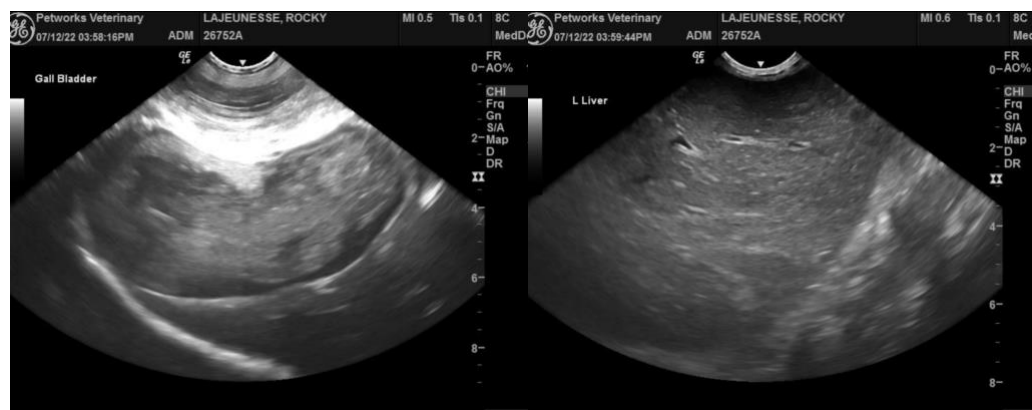
The gallbladder was overdistended, 7.0 cm x 4.5 cm, with mildly mobile bile. The bile was striating, consistent with mucocele formation.

## ULTRASONOGRAPHIC FINDINGS

- Heterogeneous liver with lipogranulomatous type changes and hypoechoic nodules
- Gallbladder overdistended with striating bile consistent with mucocele formation

## INTERPRETATION OF THE FINDINGS & FURTHER RECOMMENDATIONS

FNA of the liver nodules are recommended to assess for round cell neoplasia versus nodular hyperplasia. Gallbladder motility study is warranted. Eventual cholecystectomy may be necessary; however, I'm not convinced that the gallbladder is the complete cause of the abdominal presentation. Full abdominal sonogram with focus on the upper gastrointestinal tract and pancreas is indicated.





**PATIENT**

Rocky Lajeunesse

**SPECIES**

Canine

**BREED**

Lab Mix

**SEX**

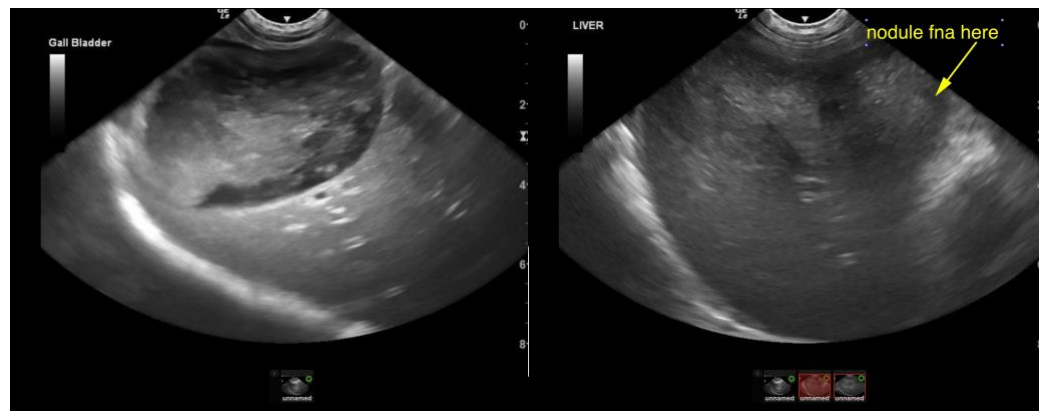
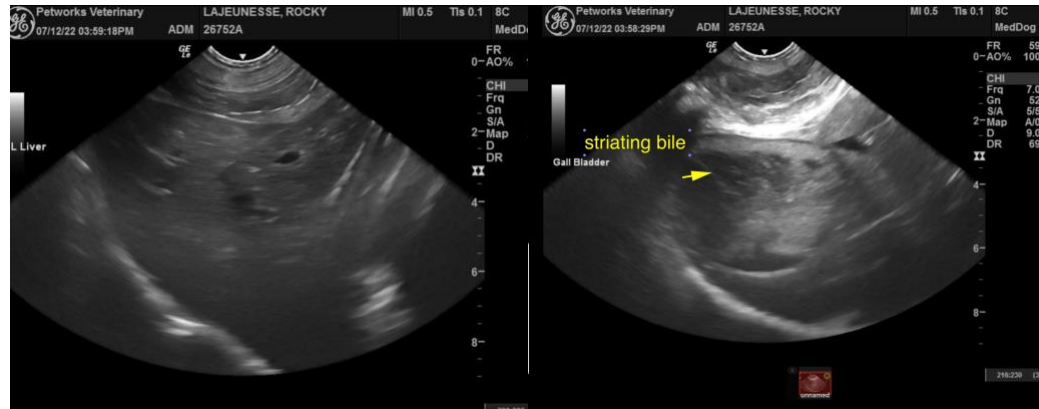
Neutered Male

**AGE**

11 ½ Years

**WEIGHT**

32.9 kg



**INTERPRETED BY**

Eric Lindquist, DMV  
DABVP, Cert. IVUSS

The information and recommendations provided are based on the images presented by the referring veterinarian. No evaluation can be communicated regarding pathology that was not visible in the image/video clips provided.

**IMAGING PERFORMED BY**

Dr. Trudeau

Thank you for this referral. If the clinical or image interpretation does not parallel your findings or if I can be of any further assistance please contact me.

**Eric Lindquist**, DMV, DABVP, Cert. IVUSS, CEO of SonoPath.com  
info@SonoPath.com

**HOSPITAL NAME**

Petworks VH

**REFERRING VET**

Dr. Trudeau

**INVOICE**

16596

**DATE**

7/12/22