



PATIENT

Bella Durso

SPECIES

Feline

BREED

DSH

SEX

Spayed Female

AGE

14 Years

WEIGHT

12 Pounds

INTERPRETED BY

Eric Lindquist, DMV
DABVP, Cert. IVUSS

IMAGING PERFORMED BY

Eric Lindquist, DMV
DABVP, Cert. IVUSS

HOSPITAL NAME

Franklin Lakes AH

REFERRING VET

Dr. Hudson/Dr.
Pomerantz

INVOICE

16600

DATE

7/12/22

PRESENTING CLINICAL SIGNS

History: Anorexia WBC 45 K

ULTRASONOGRAPHIC EXAMINATION OF THE ABDOMEN

Urinary System

The **urinary bladder**, trigone, and pelvic urethra presented normal thicknesses and normal tone. The ureters were not visible which is normal. No uroliths or sediment were visualized and anechoic urine was present. No evidence of inflammatory or neoplastic changes were noted. Ureteral papillae were normal.

The **kidneys** revealed largely normal size and structure, corticomedullary definition and ratio (cortex 1/3 of medulla) were essentially maintained with some moderate age-related loss of curvilinear patterns regarding the capsule and C/M junction. The cortices presented largely uniform texture with some increased echogenicity expected for his age patient. Medullary structure differed distinctly from that of the cortex and no evidence of pelvic dilation was present. The kidneys measured 3.5 cm each.

Adrenal Glands

The regions of the **adrenal glands** revealed no evident pathology.

Spleen

The **spleen** in this patient was uniform, yet volume contracted. Hydration status should be assessed.

Liver

The **liver** images from right and left intercostal as well as subcostal views revealed subjectively normal liver size, contour, and structure. Some age-related parenchymal remodeling was noted but likely not clinically significant at this time. Vascular and biliary tracts were of normal volume and no evidence of congestion was noted. The gallbladder presented some dependent debris with essentially normal contour. The cystic and common bile ducts were normal. The hepatic lymph nodes were unremarkable. Pleural effusion was noted through the diaphragm.

Gastrointestinal

The **gastrointestinal tract** presented an extensive 6.0 cm x 2.5 cm intestinal mass with regional inflammation and areas of free fluid and nodular omentum.

Pancreas

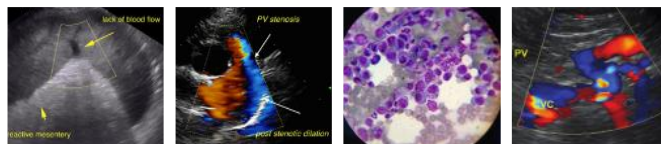
The base and limbs of the **pancreas** were observed to be largely isoechoic to surrounding omental fat. Pancreatic duct and capsular contour were acceptably normal and parenchyma respected normal curvilinear patterns. No overt evidence of active inflammatory or neoplastic disease was noted.

Free Abdomen

A mesenteric **lymph node** cluster measured 3.0 cm x 2.5 cm. Regional free fluid was present.

ULTRASONOGRAPHIC FINDINGS

- Multicentric lymphoma pattern of the intestine, omentum, lymph nodes and likely chest



PATIENT

Bella Durso

SPECIES

Feline

BREED

DSH

SEX

Spayed Female

AGE

14 Years

WEIGHT

12 Pounds

INTERPRETED BY

Eric Lindquist, DMV
DABVP, Cert. IVUSS

IMAGING PERFORMED BY

Eric Lindquist, DMV
DABVP, Cert. IVUSS

HOSPITAL NAME

Franklin Lakes AH

REFERRING VET

Dr. Hudson/Dr.
Pomerantz

INVOICE

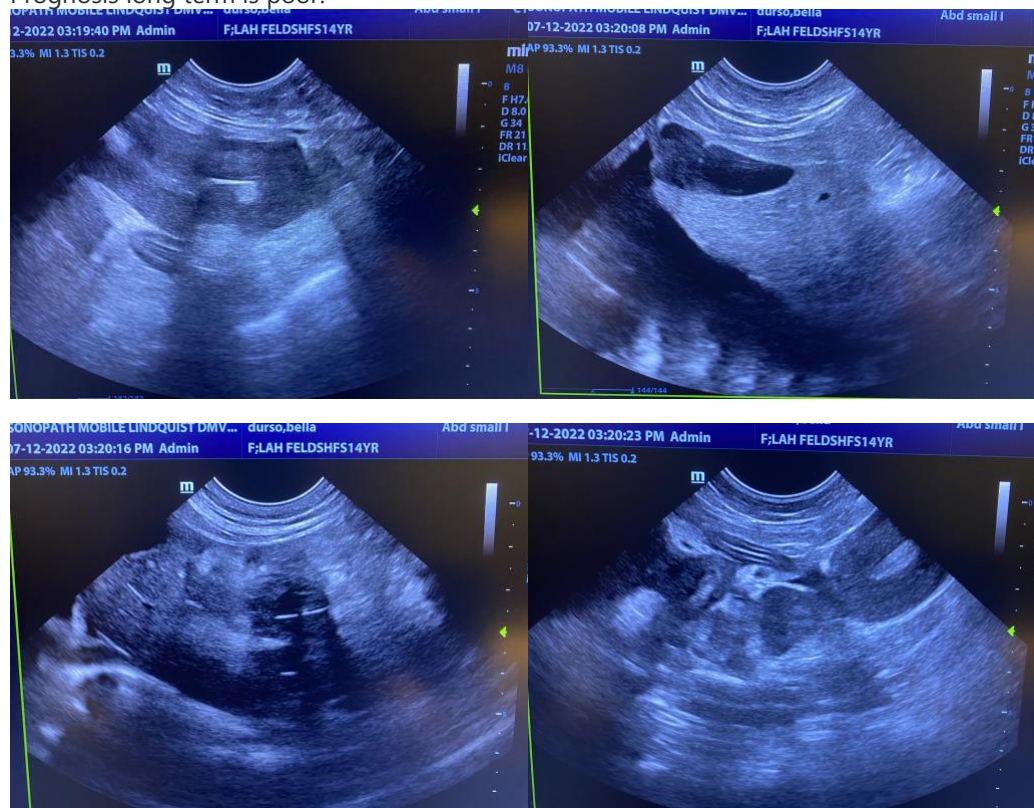
16600

DATE

7/12/22

INTERPRETATION OF THE FINDINGS & FURTHER RECOMMENDATIONS

FNA and immediate chemotherapeutic intervention or management of quality of life all indicated. Prognosis long term is poor.



The information and recommendations provided are based on the images presented by the referring veterinarian. No evaluation can be communicated regarding pathology that was not visible in the image/video clips provided.

Thank you for this referral. If the clinical or image interpretation does not parallel your findings or if I can be of any further assistance please contact me.

Eric Lindquist, DMV, DABVP, Cert. IVUSS, CEO of SonoPath.com
info@SonoPath.com