



PATIENT

Jersey MacLean

SPECIES

Canine

BREED

Chihuahua

SEX

Neutered male

AGE

12 years

WEIGHT

4.8 kg

INTERPRETED BY

Eric Lindquist, DMV
DABVP, Cert. IVUSS

IMAGING PERFORMED BY

Dave Stasiuk RDMS,
RDCE

HOSPITAL NAME

Falconridge AH

REFERRING VET

Dr. Rix

INVOICE

76090

DATE

7/11/23

PRESENTING CLINICAL SIGNS

History: 6 month follow up from previous echo read by Sonopath. Moderate MR. Moderate LA enlargement. MVP.

ULTRASONOGRAPHIC EXAMINATION OF THE HEART

The **left atrium** presented minor enlargement. The cranial and caudal **mitral** valve leaflets presented vegetative thickening consistent with endocardiosis. Prolapse of the anterior mitral valve leaflet was noted. Doppler indicated measurable insufficiency. The **left ventricle** presented thicknesses with linear contour and was not dilated nor restricted. The **myocardium** presented normal echogenicity without subjective evidence of significant fibrotic or ischemic disease. **Contractility** of the ventricular walls was adequate and in normal range for this patient evidenced by the fractional shortening measurement and subjective evaluation of the different regions of the myocardium. The **left ventricular outflow** tract demonstrated normal laminar flow and subjective structural integrity. The **right atrium** and auricle revealed normal size, structure and content. No evidence of masses was noted or chamber overload. **Tricuspid** valvular assessment demonstrated adequate linear morphology. The **right ventricle** was of normal size (1/3 diameter of LV), chordae structure, myocardial echogenicity and thickness. **Pulmonic** tract assessment revealed normal valve structure, laminar flow, and diameter (approx.1:1 pa/ao ratio). No visible **pericardial** or free pleura fluid was noted. No echographically detectable evidence of infiltrative disease was visible. The cranial **mediastinum and pericardial regions** were free of masses in the visible window.

CANINE CARDIAC PARAMETERS	MR VMAX (m/s)	TR VMAX (m/s)	LA/AO (Boon method)	LA/AO (Heart Base;)	FS (%)	EF (%)	EPSS (cm)
NORMAL PARAMETER	4.5-5.5	<2.7	1.3	Up to 1.6	28-40	40-100	<0.6
PATIENT			2.1	1.7	55	87	NM
CANINE CARDIAC PARAMETERS	HR (BPM)	AV VMAX (m/s)	PV MAX (m/s)	BODY WEIGHT (kg)	LA 2D short axis Base view (cm)	LVIDd Avg; 2D and m- mode short axis (cm)	LVIDs Avg; 2D and m- mode short axis (cm)
NORMAL PARAMETER	50-100	0.7-1.7	0.7-1.6	BELOW	BELOW	BELOW	BELOW
PATIENT		1.1	0.79	4.8 kg	3.0	2.08	

ULTRASONOGRAPHIC FINDINGS

Mitral insufficiency prolapse, slight left atrial enlargement.



INTERPRETATION OF THE FINDINGS & FURTHER RECOMMENDATIONS

PATIENT

Jersey MacLean

Left atrial parameters are similar to the prior sonogram with a slight increase in size subjectively. If vertebral heart score is excessive on radiographs then this would be considered early stage B2 valvular disease. I recommend initiating Pimobendan at 0.3 mg/kg b.i.d. Blood pressure measurements are indicated.

SPECIES

Canine

BREED

Chihuahua

SEX

Neutered male

AGE

12 years

WEIGHT

4.8 kg

INTERPRETED BY

Eric Lindquist, DMV
DABVP, Cert. IVUSS

IMAGING PERFORMED BY

Dave Stasiuk RDMS,
RDMS

HOSPITAL NAME

Falconridge AH

REFERRING VET

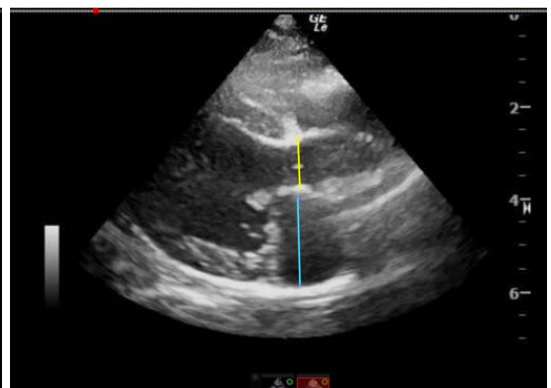
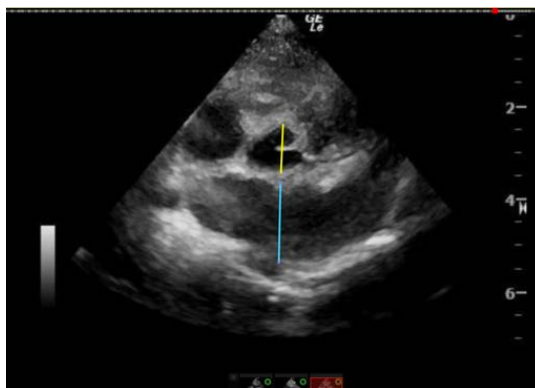
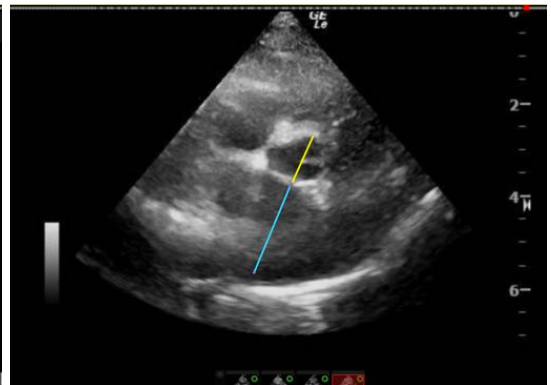
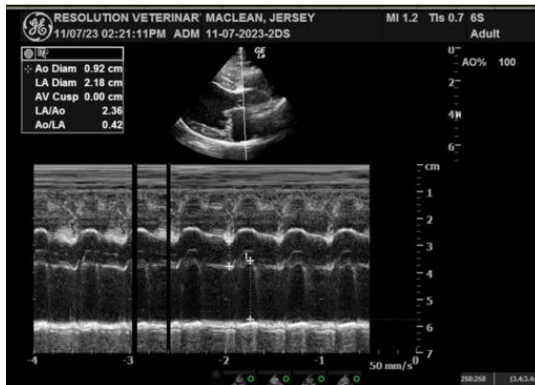
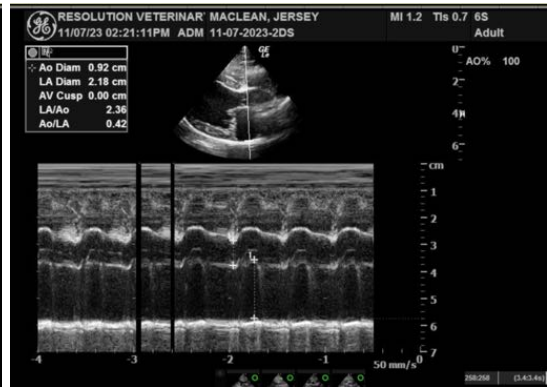
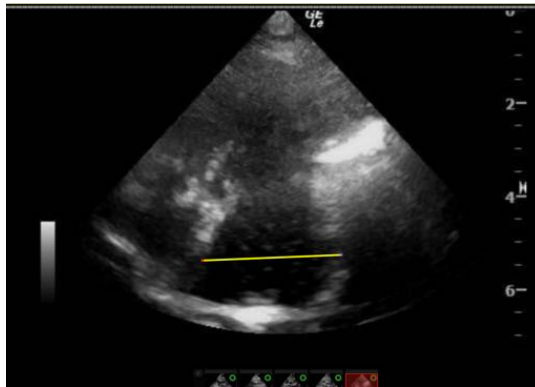
Dr. Rix

INVOICE

76090

DATE

7/11/23





PATIENT

Jersey MacLean

SPECIES

Canine

BREED

Chihuahua

SEX

Neutered male

AGE

12 years

WEIGHT

4.8 kg

INTERPRETED BY

Eric Lindquist, DMV
DABVP, Cert. IVUSS

IMAGING PERFORMED BY

Dave Stasiuk RDMS,
RDCS

HOSPITAL NAME

Falconridge AH

REFERRING VET

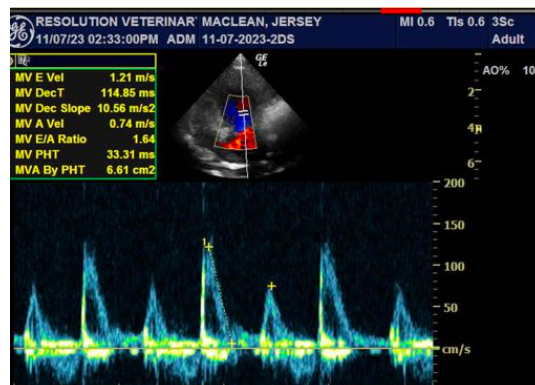
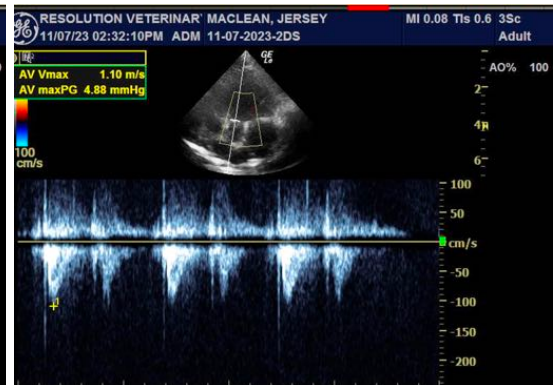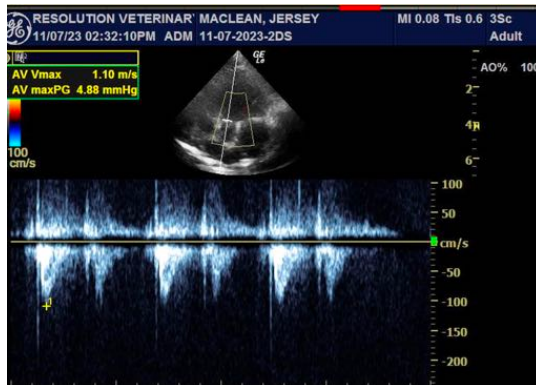
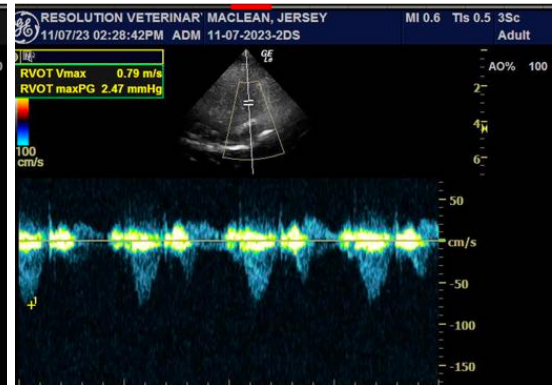
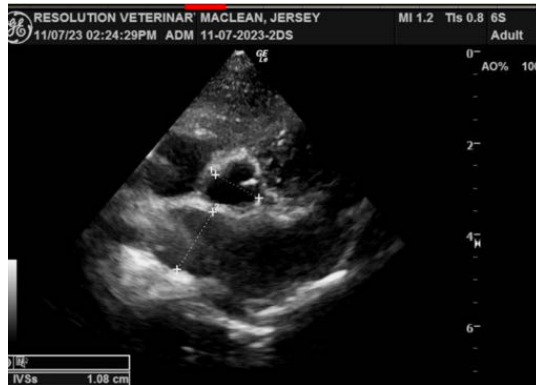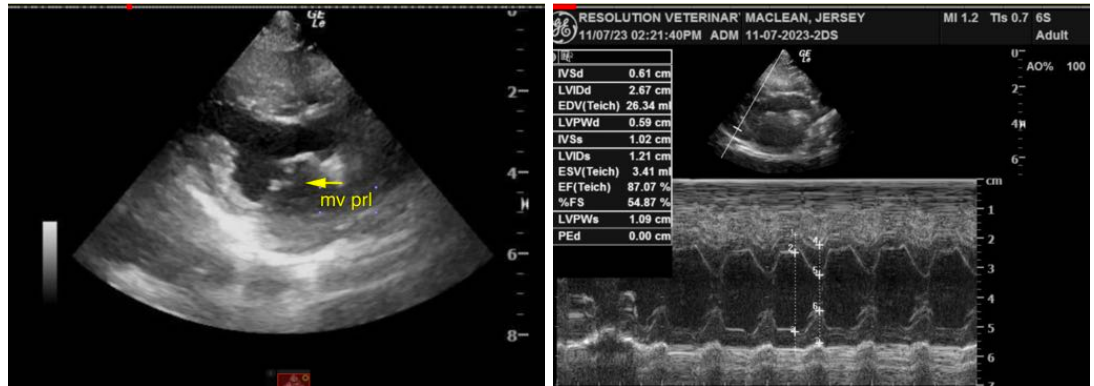
Dr. Rix

INVOICE

76090

DATE

7/11/23





PATIENT

Jersey MacLean

The information and recommendations provided are based on the images presented by the referring veterinarian/sonographer. No evaluation can be communicated regarding pathology that was not visible in the image/video clips provided.

SPECIES

Canine

Thank you for this referral. If the clinical or image interpretation does not parallel your findings or if I can be of any further assistance please contact me.

BREED

Chihuahua

Eric Lindquist, DMV, DABVP, Cert. IVUSS, CEO of SonoPath.com
info@SonoPath.com

SEX

Neutered male

AGE

12 years

WEIGHT

4.8 kg

INTERPRETED BY

Eric Lindquist, DMV
DABVP, Cert. IVUSS

**IMAGING
PERFORMED BY**

Dave Stasiuk RDMS,
RDCS

HOSPITAL NAME

Falconridge AH

REFERRING VET

Dr. Rix

INVOICE

76090

DATE

7/11/23