



PATIENT PRESENTING CLINICAL SIGNS

Trey Levon Hx of intermittent vomiting for past 3 years, worsening to vomiting EOD to 2-3x/week, also recent soft BM with blood present, slow weight loss over same time period, usually good appetite
Abnormal PE/Chem/CBC/UA Results: Persistent eosinophilia in 2020 (1024) and then in 3/2022 (2556) renal tech positive with normal BUN/ Creat T4 in gray zone (2.2, 2.1) both labs grade 2/6 sternal murmur, normocardic

SPECIES

Feline

BREED

El-dsh

SEX

El-nm

AGE

12 years

WEIGHT

9.88 lbs

ULTRASONOGRAPHIC EXAMINATION OF THE ABDOMEN

Urinary System

The **urinary bladder**, trigone, and pelvic urethra presented normal thicknesses and normal tone. The ureters were not visible which is normal. No uroliths or sediment were visualized and anechoic urine was present. No evidence of inflammatory or neoplastic changes was noted. Ureteral papillae were normal.

The **kidneys** revealed normal size and structure, corticomedullary definition and ratio for this age. The cortices presented largely uniform texture with normal echogenic relationship to liver and spleen. Medullary structure differed distinctly from the cortex and no evidence of pelvic dilation was present. The capsules were acceptably uniform without significant irregularities. Slight mineralization was noted in both kidneys. The left kidney measured 3.7 cm and the right kidney measured 3.44 cm.

Adrenal Glands

The **adrenal glands** were not visualized.

Spleen

The visible **spleen** was unremarkable. Images in the near field were dark and may limit some diagnostic value.

Liver

The **liver** images submitted revealed subjectively normal liver size, contour, and structure. Parenchymal echogenicity was naturally coarse and hypoechoic to the spleen. Vascular and biliary tracts were of normal volume with no evidence of congestion. The gallbladder presented acceptably thin walls with primarily anechoic content. The cystic and common bile ducts were normal. No pathological hepatic lymphadenopathy was evident. No overt structural evidence of inflammatory, infiltrative or regenerative pathology was evident.

Gastrointestinal

The visible pylorus was unremarkable. I cannot rule out subtle lesions in the pyloric outflow, yet globally appears unremarkable.

INTERPRETED BY

Eric Lindquist, DMV
DABVP, Cert. IVUSS

IMAGING PERFORMED BY

Casita

HOSPITAL NAME

Companion AC

REFERRING VET

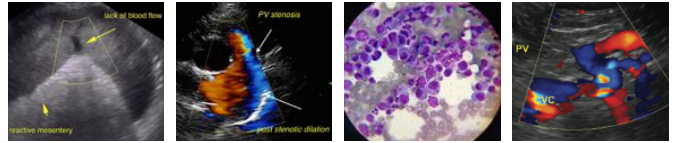
Dr. Casita

INVOICE

31575

DATE

7/11/22



PATIENT

Pancreas

Trey Levon

The base and limbs of the **pancreas** were observed to be largely isoechoic to surrounding omental fat. Pancreatic duct and capsular contour were acceptably normal and parenchyma respected normal curvilinear patterns. No overt evidence of active inflammatory or neoplastic disease was noted.

SPECIES

Feline

ULTRASONOGRAPHIC FINDINGS

BREED

Unremarkable geriatric abdomen with possible, minor upper gastrointestinal thickening.

El-dsh

INTERPRETATION OF THE FINDINGS & FURTHER RECOMMENDATIONS

SEX

Endoscopy is recommended in this patient. Maldigestion panel, three view chest radiographs and full CNS examination is recommended to examine for occult disease that could be responsible for the weight loss. Evaluation for competitive eating environments should also be considered.

El-nm

AGE

12 years

WEIGHT

9.88 lbs

INTERPRETED BY

Eric Lindquist, DMV
DABVP, Cert. IVUSS

IMAGING PERFORMED BY

Casita

HOSPITAL NAME

Companion AC

REFERRING VET

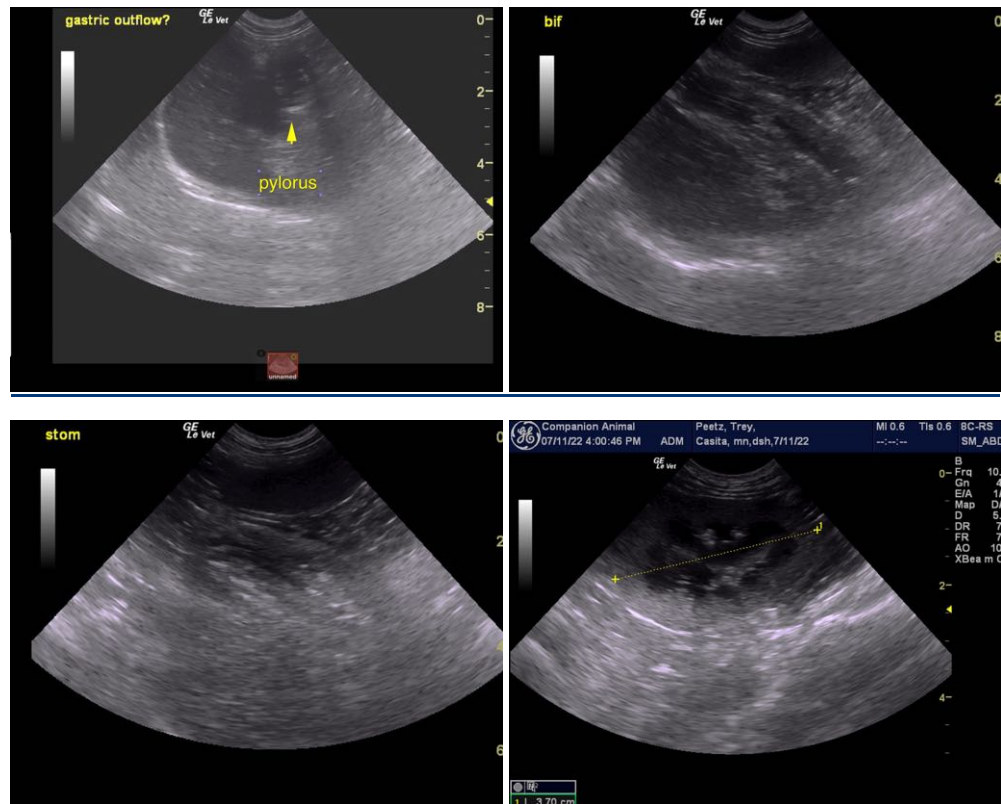
Dr. Casita

INVOICE

31575

DATE

7/11/22





PATIENT

Trey Levon

The information and recommendations provided are based on the images presented by the referring veterinarian/sonographer. No evaluation can be communicated regarding pathology that was not visible in the image/video clips provided.

SPECIES

Feline

Thank you for this referral. If the clinical or image interpretation does not parallel your findings or if I can be of any further assistance please contact me.

BREED

El-dsh

Eric Lindquist, DMV, DABVP, Cert. IVUSS, CEO of SonoPath.com
info@SonoPath.com

SEX

El-nm

AGE

12 years

WEIGHT

9.88 lbs

INTERPRETED BY

Eric Lindquist, DMV
DABVP, Cert. IVUSS

**IMAGING
PERFORMED BY**

Casita

HOSPITAL NAME

Companion AC

REFERRING VET

Dr. Casita

INVOICE

31575

DATE

7/11/22