



PATIENT

Otis Slattery

SPECIES

Canine

BREED

English Bulldog

SEX

Neutered Male

AGE

10 Years

WEIGHT

79 Pounds

INTERPRETED BY

Eric Lindquist, DMV
DABVP, Cert. IVUS

IMAGING PERFORMED BY

Kelly Vazquez

HOSPITAL NAME

Glen Rock VH

REFERRING VET

Dr. Scott Steklar

INVOICE

16565

DATE

7/11/22

PRESENTING CLINICAL SIGNS

History: Patient with abdominal ascites and suspect cardiac disease presents for echo.

ULTRASONOGRAPHIC EXAMINATION OF THE HEART

| CANINE CARDIAC PARAMETERS | MR VMAX (m/s) | TR VMAX (m/s) | LA/AO (Boon method) | LA/AO (Heart Base; Swe) | FS (%) | EF (%) | EPSS (cm) |
|---------------------------|---------------|---------------|---------------------|-------------------------|---------------------------------|--|--|
| NORMAL PARAMETER | 4.5-5.5 | <2.7 | 1.3 | <1.3 | 28-40 | 40-100 | <0.6 |
| PATIENT | 6.0 | 3.5 | >2.0 | 2.5 | 20 | 42 | 0.1 |
| CANINE CARDIAC PARAMETERS | HR (BPM) | AV VMAX (m/s) | PV MAX (m/s) | BODY WEIGHT (kg) | LA 2D short axis Base view (cm) | LVIDd Avg; 2D and m-mode short axis (cm) | LVIDs Avg; 2D and m-mode short axis (cm) |
| NORMAL PARAMETER | 50-100 | 0.7-1.7 | 0.7-1.6 | | | | |
| PATIENT | 123 | -- | -- | -- | 5.65 | 4.7 | -- |

Cardiac Presentation

The cardiac presentation presented mitral and tricuspid insufficiency with tachyarrhythmia and volume overload of the left and right heart. Contractility was subnormal, consistent with myocardial insufficiency. No pericardial or pleural effusion noted. EPSS was normal.

ULTRASONOGRAPHIC FINDINGS

- Left and right sided heart failure
- End-stage valvular disease (Stage C1-D1)
- Periodic tachyarrhythmia

INTERPRETATION OF THE FINDINGS & FURTHER RECOMMENDATIONS

EKG is indicated. I recommend quadra therapy in this patient and Pimobendan at 0.3 mg/kg BID, Ace-inhibitor at 0.5 mg/kg SID, progressing to BID, Lasix at 2-4 mg/kg BID and Spironolactone at 1-2 mg/kg BID. Recheck echo in 7-10 days. Leash-based low-grade exercise recommended. However, cage rest is warranted over the next 48 hours. There is a concern for potential sudden death development in this patient. An addition of Sildenafil will likely be necessary based on response to initial therapy.



PATIENT

Otis Slattery

SPECIES

Canine

BREED

English Bulldog

SEX

Neutered Male

AGE

10 Years

WEIGHT

79 Pounds

INTERPRETED BY

Eric Lindquist, DMV
DABVP, Cert. IVUSS

IMAGING PERFORMED BY

Kelly Vazquez

HOSPITAL NAME

Glen Rock VH

REFERRING VET

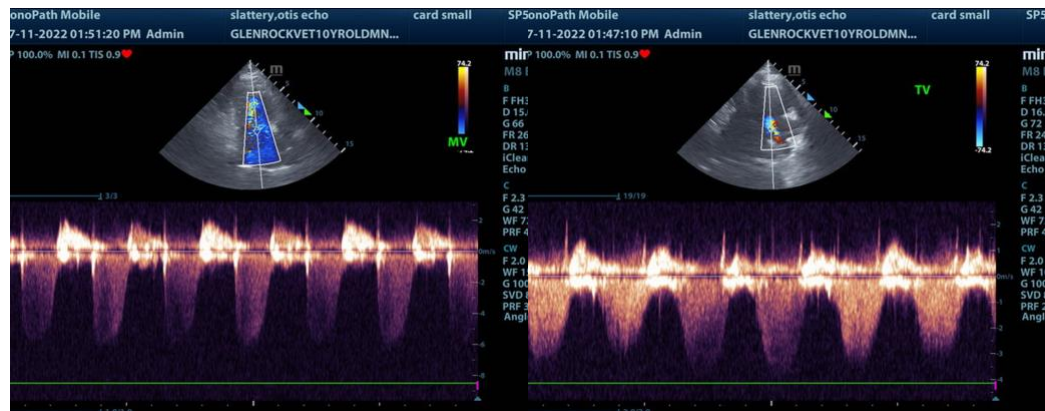
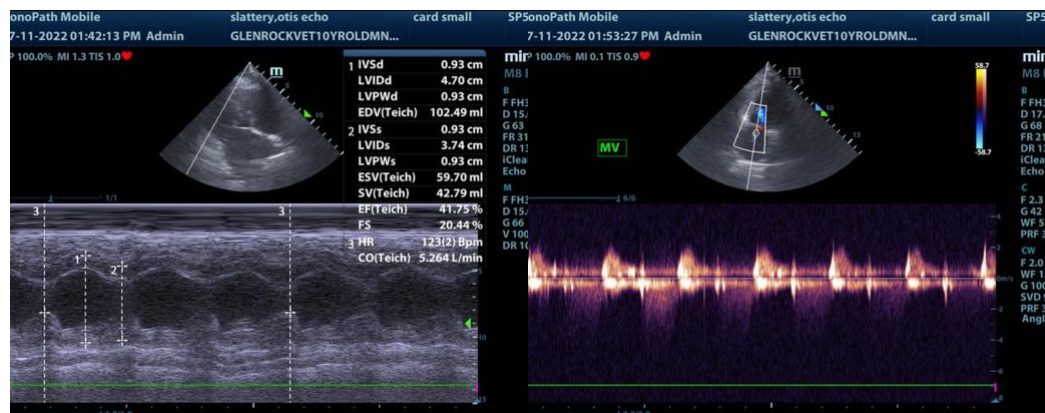
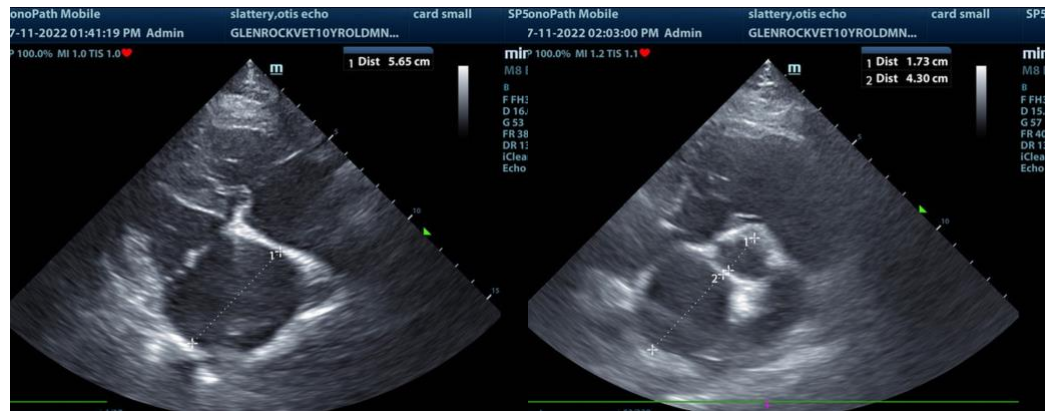
Dr. Scott Steklar

INVOICE

16565

DATE

7/11/22



The information and recommendations provided are based on the images presented by the referring veterinarian. No evaluation can be communicated regarding pathology that was not visible in the image/video clips provided.

Thank you for this referral. If the clinical or image interpretation does not parallel your findings or if I can be of any further assistance please contact me.

Eric Lindquist, DMV, DABVP, Cert. IVUSS, CEO of SonoPath.com
info@SonoPath.com