SonoPath
Clinical Sonography & Telecytology

EDUCATIONAL TELECONSULTATION SERVICES™

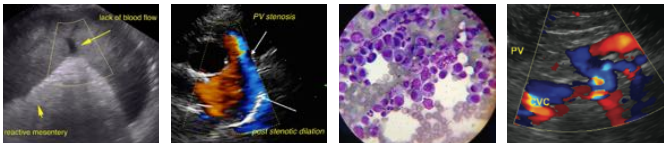

SonoPath.com™
1-800-838-4268 info@sonopath.com

PATIENT
Kenzie Thomas

SPECIES
Canine

BREED
Beagle

SEX
Spayed female

AGE
9 years

WEIGHT
30.3 lbs

INTERPRETED BY
Eric Lindquist, DMV DABVP, Cert. IVUSS

IMAGING PERFORMED BY
Jen Amidon

HOSPITAL NAME
The Pet Hospital of Stratford

REFERRING VET
Dr. Giuliani

INVOICE
31561

DATE
7/11/22

PRESENTING CLINICAL SIGNS

Pt presented for having urinary accidents in the house. UA showed proteinuria with UPC of 2.8. Pt blood pressure was checked and was wnl - no hypertension. Pt had 2 first morning urine samples with protein in the urine, but reflex UPC wasn't indicated for either. Pt was put on clavamox and urinary accidents stopped as of Nov. In May, pt came back because started to have accidents again. Pt u/a still had protein in the urine, but also had signs of infection, so was put back on clavamox. Pt has also been having diarrhea for the past 2 months. Pt has been given proviable kit, metron, and GI diet, but o reports it only resolved while pt was on clavamox, and came back when she finished it.

ULTRASONOGRAPHIC EXAMINATION OF THE ABDOMEN

Urinary System

The **urinary bladder**, trigone, and pelvic urethra presented normal thicknesses and normal tone. The pelvic urethra was imaged 2.0 cm beyond the cystourethral junction and appeared normal. The ureters were not visible which is normal. No uroliths or sediment were visualized and anechoic urine was present. No evidence of inflammatory or neoplastic changes was noted. Ureteral papillae were normal.

The **kidneys** revealed largely normal size and structure, corticomedullary definition and ratio (cortex 1/3 of medulla) were essentially maintained with some age-related loss of curvilinear patterns regarding the capsule and C/M junction. The cortices presented largely uniform texture with some increased echogenicity expected for his age patient. Medullary structure differed distinctly from that of the cortex and no evidence of pelvic dilation was present. The left and right kidney measured 5.0 cm. Power Doppler assessment revealed normal blood flow.

Adrenal Glands

Both **adrenal glands** were visualized and recognized as having normal shape, size, position and echogenicity for this breed. The phrenic vasculature, glandular echogenicity and detail were unremarkable. Capsule, cortex, and medullary definition were normal for this age patient. The left adrenal gland measured 0.5 cm and was visualized obliquely. The right adrenal gland measured 0.6 cm.

Spleen

The **spleen** was folded upon itself caudally and cranially with uniform enlargement.

Liver

The **liver** images from right and left intercostal as well as subcostal views revealed subjectively normal liver size, contour, and structure. Some age-related parenchymal remodeling was noted but likely not clinically significant at this time. Vascular and biliary tracts were of normal volume and no evidence of congestion was noted. The gallbladder and common bile duct were unremarkable. The hepatic lymph nodes were unremarkable.

SonoPath
Clinical Sonography & Telecytology

EDUCATIONAL TELECONSULTATION SERVICES™

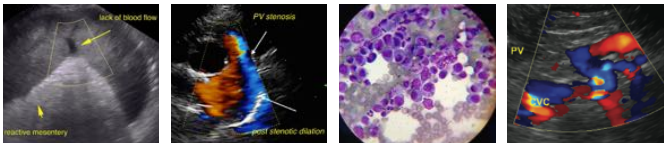

SonoPath.com™
1-800-838-4268 info@sonopath.com

PATIENT

Kenzie Thomas

SPECIES

Canine

BREED

Beagle

SEX

Spayed female

AGE

9 years

WEIGHT

30.3 lbs

INTERPRETED BY

Eric Lindquist, DMV
DABVP, Cert. IVUSS

IMAGING PERFORMED BY

Jen Amidon

HOSPITAL NAME

The Pet Hospital of Stratford

REFERRING VET

Dr. Giuliani

INVOICE

31561

DATE

7/11/22

Gastrointestinal

Examination of the **gastrointestinal tract** revealed a stomach and intestine free of stasis, of normal wall thickness, acceptable curvilinear mural detail, and peristaltic activity. Small and large intestine demonstrated normal luminal chyme and stool consistency respectively. No obstructive or overt infiltrative disease was noted. No associated abnormal lymphatic activity was noted.

Pancreas

The base and limbs of the **pancreas** were observed to be largely isoechoic to surrounding omental fat. Pancreatic duct and capsular contour were acceptably normal and parenchyma respected normal curvilinear patterns. No overt evidence of active inflammatory or neoplastic disease was noted.

ULTRASONOGRAPHIC FINDINGS

Structurally unremarkable abdomen.

Age related renal and hepatic changes, minor hypersplenism.

INTERPRETATION OF THE FINDINGS & FURTHER RECOMMENDATIONS

There was no evidence of significant structural disease. Subjectively the urethra appears to have appropriate tone; however, Phenylpropanolamine trial can be considered. If any inflammatory sediment is present in the urine then culture is indicated and/or empirical treatment for UTI over a 10 day period. Enrofloxacin trial or similar could be considered.

SonoPath

Clinical Sonography & Telecytology

EDUCATIONAL TELECONSULTATION SERVICES™

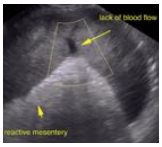

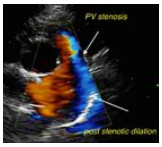

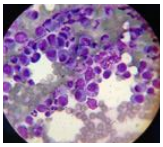

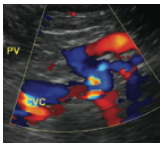

SonoPath.com™
1-800-838-4268 info@sonopath.com

PATIENT

Kenzie Thomas

SPECIES

Canine

BREED

Beagle

SEX

Spayed female

AGE

9 years

WEIGHT

30.3 lbs

INTERPRETED BY

Eric Lindquist, DMV
DABVP, Cert. IVUSS

IMAGING PERFORMED BY

Jen Amidon

HOSPITAL NAME

The Pet Hospital of Stratford

REFERRING VET

Dr. Giuliani

INVOICE

31561

DATE

7/11/22

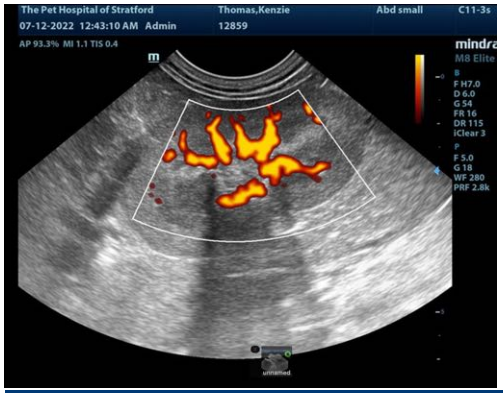

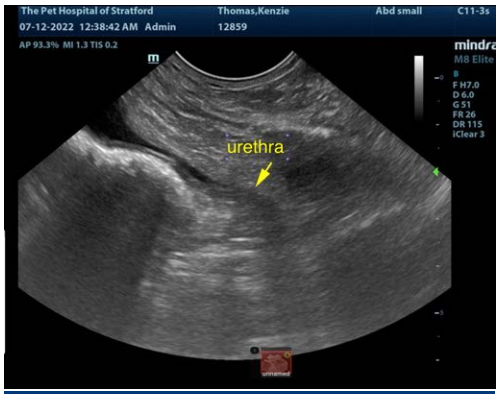

SonoPath

Clinical Sonography & Telecytology

EDUCATIONAL TELECONSULTATION SERVICES™

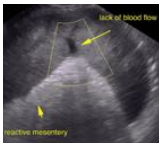

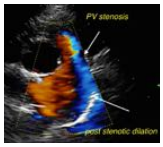

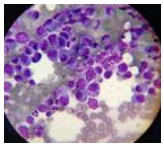
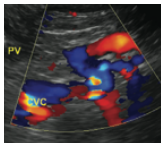

SonoPath.com™
1-800-838-4268 info@sonopath.com

PATIENT

Kenzie Thomas

SPECIES

Canine

BREED

Beagle

SEX

Spayed female

AGE

9 years

WEIGHT

30.3 lbs

INTERPRETED BY

Eric Lindquist, DMV
DABVP, Cert. IVUSS

IMAGING PERFORMED BY

Jen Amidon

HOSPITAL NAME

The Pet Hospital of Stratford

REFERRING VET

Dr. Giuliani

INVOICE

31561

DATE

7/11/22

The information and recommendations provided are based on the images presented by the referring veterinarian/sonographer. No evaluation can be communicated regarding pathology that was not visible in the image/video clips provided.

Thank you for this referral. If the clinical or image interpretation does not parallel your findings or if I can be of any further assistance please contact me.

Eric Lindquist, DMV, DABVP, Cert. IVUSS, CEO of SonoPath.com
info@SonoPath.com