



**PATIENT**

Digger Welsh

**PRESENTING CLINICAL SIGNS**

Hx of FB. Vomited Sunday. Hyporexia. Suspected FB at referral hospital July 6th. Lethargic since the 4th  
Abnormal PE/Chem/CBC/UA Results: Pending

**SPECIES**

Canine

**ULTRASONOGRAPHIC EXAMINATION OF THE ABDOMEN**

**Urinary System**

**BREED**

Boxer X

The **urinary bladder**, trigone, and pelvic urethra presented normal thicknesses and normal tone. The ureters were not visible which is normal. No uroliths or sediment were visualized and anechoic urine was present. No evidence of inflammatory or neoplastic changes were noted. Ureteral papillae were normal.

**SEX**

Neutered Male

The **kidneys** revealed normal size and structure, corticomedullary definition and ratio for this age. The cortices presented largely uniform texture with normal echogenic relationship to liver and spleen. Medullary structure differed distinctly from the cortex and no evidence of pelvic dilation was present. The capsules were acceptably uniform without significant irregularities. The left kidney measured 7.64 cm. The right kidney measured 7.08 cm.

**AGE**

3 Years

**Adrenal Glands**

**WEIGHT**

70 Pounds

Both **adrenal glands** were visualized and recognized as having normal shape, size, position and echogenicity for this breed. The phrenic vasculature, glandular echogenicity and detail were unremarkable. Capsule, cortex, and medullary definition were normal for this age patient. The left adrenal gland measured 3.25 cm x 0.72 cm. The right adrenal gland measured 4.39 cm x 0.60 cm at the cranial pole and 0.40 cm at the caudal pole.

**INTERPRETED BY**

Eric Lindquist, DMV

DABVP, Cert. IVUSS

**Spleen**

The **spleen** presented a smooth homogeneous parenchyma hyperechoic to liver and renal cortical parenchyma. The capsule was smooth without noticeable expansion or deviation from within the spleen or adjacent pathology. The splenic vasculature demonstrated normal volume without signs of congestion or thrombosis. No sonographic evidence of acute or chronic inflammatory, neoplastic, or infarctual changes were noted.

**IMAGING PERFORMED BY**

Dr. Rodriguez

**Liver**

The **liver** images submitted revealed subjectively normal liver size, contour, and structure. Parenchymal echogenicity was naturally coarse and hypoechoic to the spleen. Vascular and biliary tracts were of normal volume with no evidence of congestion. The gallbladder presented acceptably thin walls with primarily anechoic content. The cystic and common bile ducts were normal. No pathological hepatic lymphadenopathy was evident. No overt structural evidence of inflammatory, infiltrative or regenerative pathology was evident.

**HOSPITAL NAME**

Foxfield VS

**REFERRING VET**

Dr. Rodriguez

**Gastrointestinal**

The **stomach** itself was unremarkable. The mid jejunum revealed a 3-4 cm anechoic tubular foreign body with variable intestinal thickening followed by empty small intestine. Reactive mesenteric lymph nodes noted.

**INVOICE**

39379

**DATE**

7/11/22



**PATIENT**

**Pancreas**

Digger Welsh

The base and limbs of the **pancreas** were observed to be largely isoechoic to surrounding omental fat. Pancreatic duct and capsular contour were acceptably normal and parenchyma respected normal curvilinear patterns. No overt evidence of active inflammatory or neoplastic disease was noted.

**SPECIES**

Canine

**PRIMARY FINDINGS**

- Obstructive jejunal foreign body with variable intestinal thickening and minor lymphadenopathy

**BREED**

Boxer X

**INTERPRETATION OF THE FINDINGS & FURTHER RECOMMENDATIONS**

Recommend immediate exploratory surgery. Intestinal lymph node biopsies noted along with retrieval of foreign body.

**SEX**

Neutered Male

According to Sonopath research presented at ECVIM 2016 (Stockholm, Sweden), Advances in Small Animal Medicine and Surgery (May 2017), and EVDI 2017 (Verona, Italy), concurrent underlying chronic inflammatory neoplastic intestinal disease can often reside in PICA patients. Therefore, surgical biopsies are essential in this case regardless of the exploratory findings.

**AGE**

3 Years

**WEIGHT**

70 Pounds

**INTERPRETED BY**

Eric Lindquist, DMV

DABVP, Cert. IVUSS

**IMAGING PERFORMED BY**

Dr. Rodriguez

**HOSPITAL NAME**

Foxfield VS

**REFERRING VET**

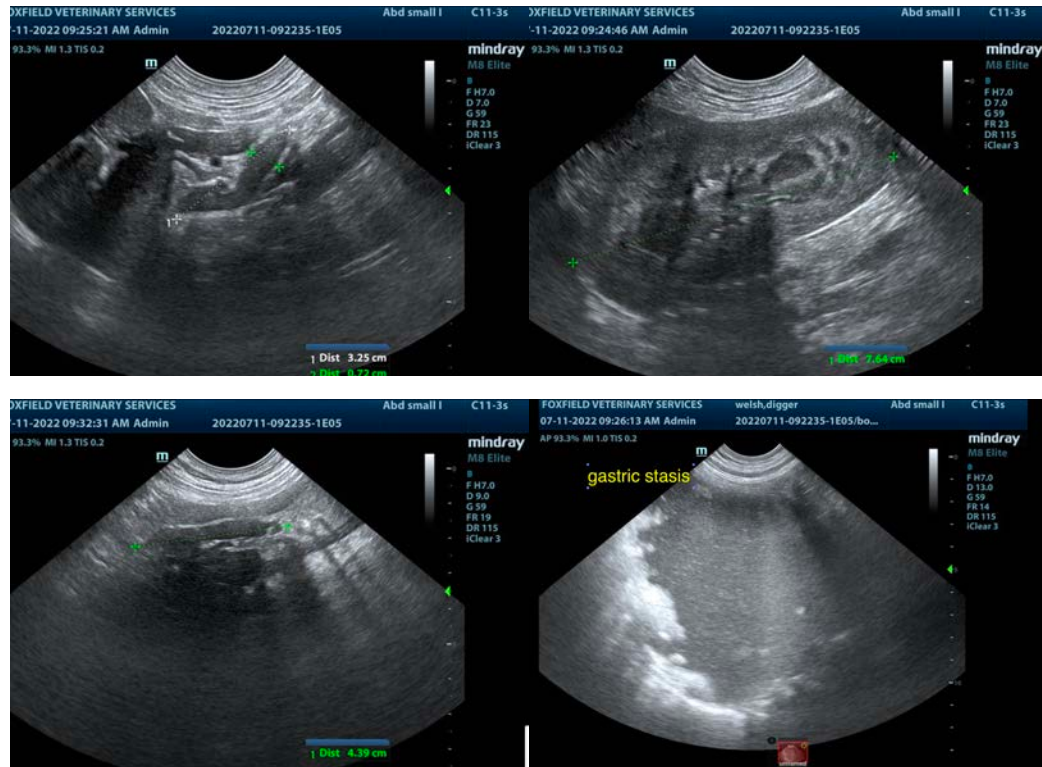
Dr. Rodriguez

**INVOICE**

39379

**DATE**

7/11/22





**PATIENT**

Digger Welsh

**SPECIES**

Canine

**BREED**

Boxer X

**SEX**

Neutered Male

**AGE**

3 Years

**WEIGHT**

70 Pounds

**INTERPRETED BY**

Eric Lindquist, DMV

DABVP, Cert. IVUSS

**IMAGING PERFORMED BY**

Dr. Rodriguez

**HOSPITAL NAME**

Foxfield VS

**REFERRING VET**

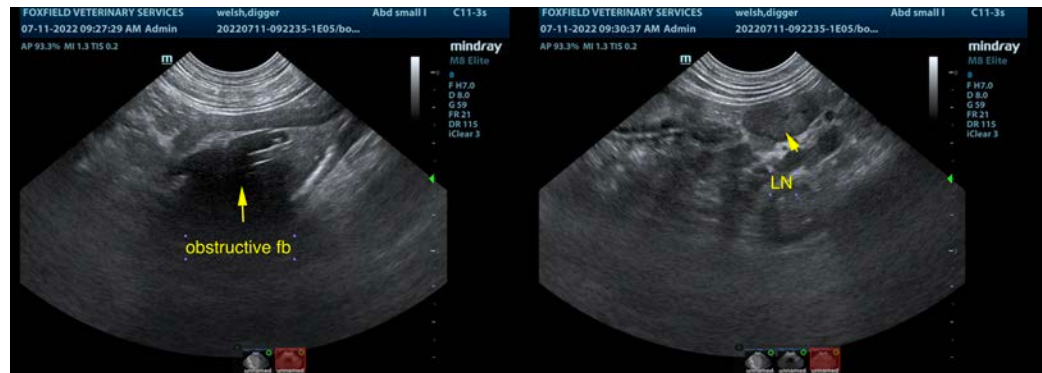Dr. Rodriguez

**INVOICE**

39379

**DATE**

7/11/22



The information and recommendations provided are based on the images presented by the referring veterinarian/sonographer. No evaluation can be communicated regarding pathology that was not visible in the image/video clips provided.

Thank you for this referral. If the clinical or image interpretation does not parallel your findings or if I can be of any further assistance please contact me.

**Eric Lindquist, DMV, DABVP, Cert. IVUSS, CEO of SonoPath.com**

[info@SonoPath.com](mailto:info@SonoPath.com)