



PATIENT

Danika Lauricello

SPECIES

Canine

BREED

Labrador Retriever

SEX

Spayed Female

AGE

8 Years

WEIGHT

50 Pounds

INTERPRETED BY

Eric Lindquist, DMV
DABVP, Cert. IVUSS

IMAGING PERFORMED BY

Shari Reffi, CVT

HOSPITAL NAME

Shohola

REFERRING VET

Dr. DeMeo

INVOICE

16568

DATE

7/11/22

PRESENTING CLINICAL SIGNS

History: Proteinuria, pu/pd. Current meds: Prednisone 2.5mg sid, Apoquel 16mg 1/2 t sid

Abnormal PE/Chem/CBC/UA Results: sdma 16, alt 130, alp 250, USG 1.019, 3+ protein, Creat 80.6, protein 672.5, UPC 8.3

ULTRASONOGRAPHIC EXAMINATION OF THE ABDOMEN

Urinary System

The **urinary bladder**, trigone, and pelvic urethra presented normal thicknesses and normal tone. The ureters were not visible which is normal. No uroliths or sediment were visualized, and anechoic urine was present. No evidence of inflammatory or neoplastic changes were noted. Ureteral papillae were normal. The pelvic urethra was imaged 3.0 cm beyond the cystourethral junction.

The **kidneys** were normal in size and contour with nonspecific mild increased cortical echogenicity. Vascularity was normal. The left kidney measured 5.4 cm. The right kidney measured 6.68 cm.

Adrenal Glands

Both **adrenal glands** were flattened and isoechoic, likely owing to prednisone therapy. However, underlying Addison's should be considered. The right adrenal gland measured 2.09 cm x 0.37 cm at the cranial pole and 0.31 cm at the caudal pole. The left adrenal gland measured 1.54 cm x 0.25 cm at the cranial pole and 0.25 cm at the caudal pole.

Spleen

The **spleen** presented a smooth homogeneous parenchyma hyperechoic to liver and renal cortical parenchyma. The capsule was smooth without noticeable expansion or deviation from within the spleen or adjacent pathology. The splenic vasculature demonstrated normal volume without signs of congestion or thrombosis. No sonographic evidence of acute or chronic inflammatory, neoplastic, or infarctual changes were noted.

Liver

The **liver** images from right and left intercostal as well as subcostal views revealed subjectively normal liver size, contour, and structure. Some mild age-related parenchymal remodeling was noted but likely not clinically significant at this time. The hepatic lymph nodes were unremarkable. Minor gallbladder sand was noted, nonobstructive.

Gastrointestinal

Examination of the **gastrointestinal tract** revealed a stomach and intestine free of stasis, of normal wall thickness, acceptable curvilinear mural detail, and peristaltic activity. Small and large intestine demonstrated normal luminal chyme and stool consistency respectively. No obstructive or overt infiltrative disease was noted. No associated abnormal lymphatic activity was noted.

Pancreas

The base and limbs of the **pancreas** were observed to be largely isoechoic to surrounding omental fat. Pancreatic duct and capsular contour were acceptably normal and parenchyma respected normal curvilinear patterns. No overt evidence of active inflammatory or neoplastic disease was noted.



PATIENT

Danika Lauricello

SPECIES

Canine

BREED

Labrador Retriever

SEX

Spayed Female

AGE

8 Years

WEIGHT

50 Pounds

INTERPRETED BY

Eric Lindquist, DMV
DABVP, Cert. IVUSS

IMAGING PERFORMED BY

Shari Reffi, CVT

HOSPITAL NAME

Shohola

REFERRING VET

Dr. DeMeo

INVOICE

16568

DATE

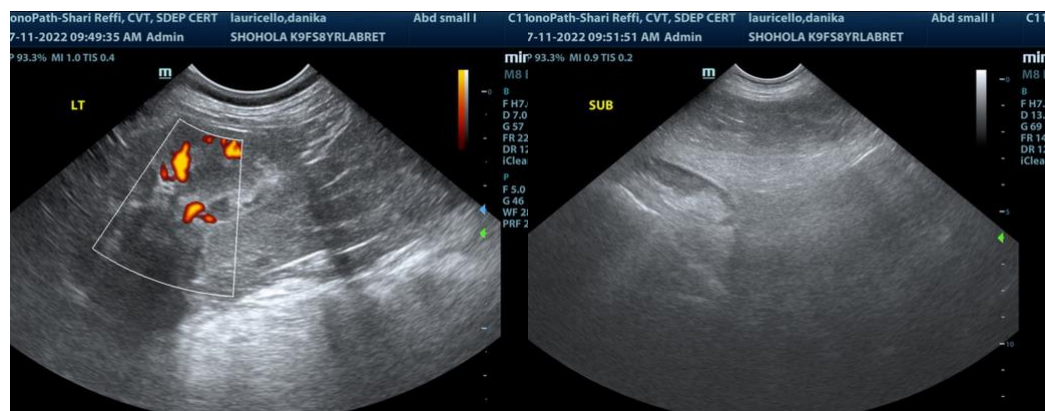
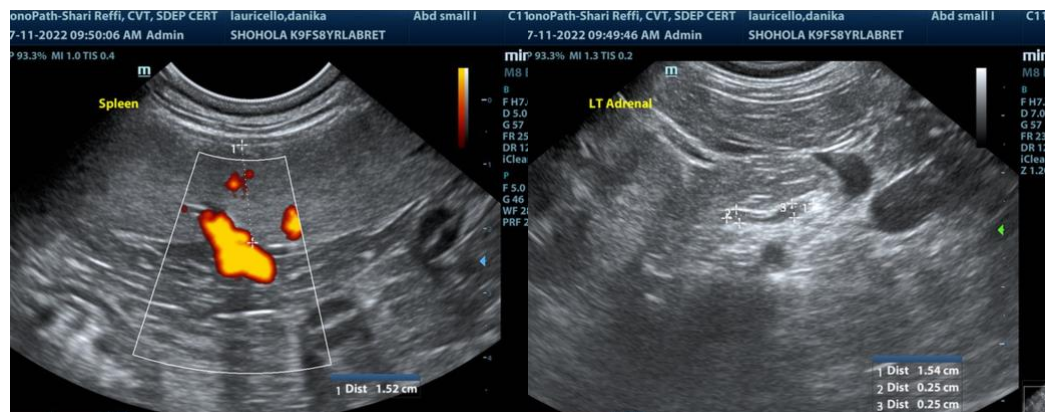
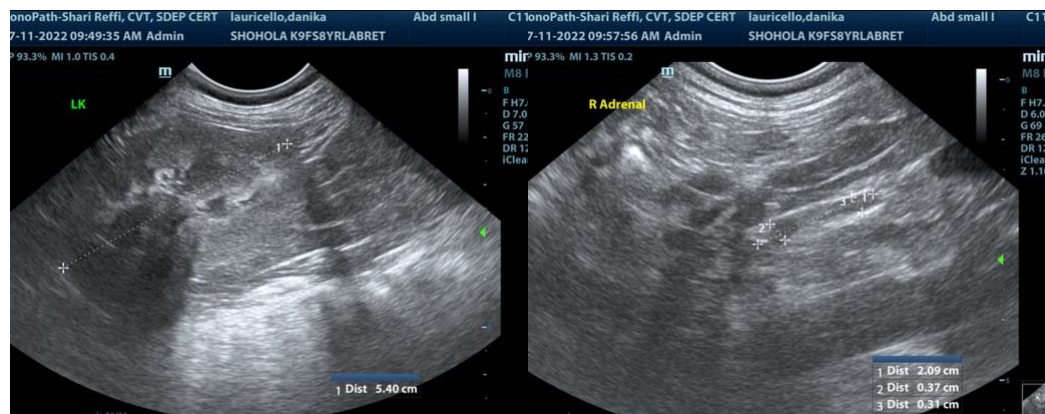
7/11/22

ULTRASONOGRAPHIC FINDINGS

- Nonspecific protein losing nephropathy
- Age-related hepatic changes with minor gallbladder sand
- Flattened and isoechoic adrenal glands

INTERPRETATION OF THE FINDINGS & FURTHER RECOMMENDATIONS

Tick-borne disease panel is warranted. Diet change to hydrolyzed diet is recommended. A doxycycline trial could also be considered. No evidence of neoplasia. Blood pressure measurements are indicated.





PATIENT

Danika Lauricello

SPECIES

Canine

BREED

Labrador Retriever

SEX

Spayed Female

AGE

8 Years

WEIGHT

50 Pounds

INTERPRETED BY

Eric Lindquist, DMV
DABVP, Cert. IVUSS

IMAGING PERFORMED BY

Shari Reffi, CVT

HOSPITAL NAME

Shohola

REFERRING VET

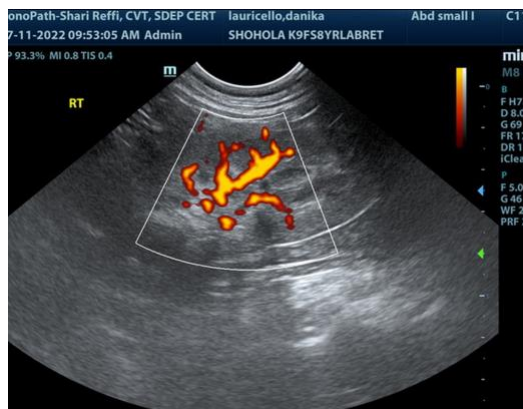
Dr. DeMeo

INVOICE

16568

DATE

7/11/22



The information and recommendations provided are based on the images presented by the referring veterinarian. No evaluation can be communicated regarding pathology that was not visible in the image/video clips provided.

Thank you for this referral. If the clinical or image interpretation does not parallel your findings or if I can be of any further assistance please contact me.

Eric Lindquist, DMV, DABVP, Cert. IVUSS, CEO of SonoPath.com
info@SonoPath.com

Canine and Feline Proteinuria

<http://www.sonopath.com/Proteinuria>

Description: Protein-losing nephropathy is a common but underdiagnosed form of renal disease in dogs and cats. Unfortunately, the disease is often clinically silent and can only be determined upon urinalysis. Therapeutic options and prognosis are much better if it is diagnosed early. Urine analysis should be performed routinely in animals, and all animals with unexplained proteinuria should be thoroughly investigated to determine the specific cause.

The hallmark of all glomerular diseases is abnormal protein loss in the urine. From a diagnostic standpoint, one must first establish whether proteinuria is prerenal, renal, or postrenal.

Prerenal proteinuria: This condition occurs when protein is lost in normal kidneys due to the passage of abnormally low-molecular-weight proteins across the filtration barrier (e.g. hemoglobinuria, light-chain proteinuria in myeloma, and myoglobinuria). Transient prerenal proteinuria can result from increased intraglomerular capillary pressure. The increased pressure favours the migration of small



PATIENT

Danika Lauricello

proteins normally present in plasma through the filtration barrier, which may occur as a result of strenuous exercise, fever, or seizures.

SPECIES

Canine

Renal proteinuria: Glomerular proteinuria occurs when the filtration barrier undergoes disruption, altering its permselectivity and resulting in the loss of molecules that are otherwise usually retained in urine plasma. Because albumin is relatively small (65,000 Daltons), it is the protein most predominantly lost from the glomerulus. Proteinuria can also transpire in the renal tubule when the proximal tubule fails to reabsorb normally filtered proteins. This may occur in cases of generalized tubulopathies, such as Fanconi syndrome or acute tubular necrosis.

BREED

Labrador Retriever

Postrenal proteinuria: Postrenal proteinuria occurs when protein enters the urine as a result of hemorrhage or inflammation in the lower urinary or genital tract.

SEX

Spayed Female

Prerenal proteinuria can usually be ruled out by taking the patient's history and spinning the urine to distinguish hemoglobinuria and myoglobinuria from hematuria. Postrenal proteinuria can often be diagnosed based on the presence of active urine sediment, which is indicative of hematuria, pyuria, and/or bacteriuria.

AGE

8 Years

The glomerulus is a tuft of highly branched capillaries, which, together with the Bowman's capsule, form the renal corpuscle of the nephron. The glomeruli are confined to the renal cortex. The glomerulus is comprised of capillary endothelial cells, visceral epithelial cells, mesangial cells, the mesangial matrix, and capillary basement membranes.

WEIGHT

50 Pounds

INTERPRETED BY

Eric Lindquist, DMV
DABVP, Cert. IVUSS

Glomerular capillary endothelial cells are similar to those found in capillaries throughout the body except that they contain numerous large pores called fenestrae. Visceral epithelial cells called podocytes cover the glomerular capillaries; they contain cytoplasmic foot processes that extend onto the glomerular basement membrane (GBM). The spaces between the cytoplasmic foot processes are all called slit pores and they are covered with slit pore membranes. This is where filtration is believed to occur. The visceral epithelium is covered with sialoprotein, which is negatively charged and tends to inhibit the passage of negatively charged macromolecules. Mesangial cells occupy spaces in the tuft between the capillary loops and produce the mesangial matrix; they also have phagocytic capabilities. The mesangial matrix provides the structural support for the glomerulus. The GBM is located between the endothelial and visceral epithelial cells; however, it does not completely surround the capillary lumen.

IMAGING PERFORMED BY

Shari Reffi, CVT

HOSPITAL NAME

Shohola

REFERRING VET

Dr. DeMeo

Glomerular injury is an important cause of renal disease in companion animals and appears to be more common in dogs than in cats. Because the components of the nephron are functionally interdependent, disease in the glomerulus—if progressive and unresolved—will eventually damage the tubules, interstitium, and vasculature, resulting in chronic renal failure.

INVOICE

16568

In both dogs and cats, immune complex glomerulonephritis (GN) and amyloidosis are the most common primary glomerular disease syndromes. A hereditary susceptibility to certain types of GN has been demonstrated in humans, but not yet in dogs and cats to date.

DATE

7/11/22



PATIENT

Danika Lauricello

Causative factors associated with GN in dogs and cats include the following:

SPECIES

Canine

BREED

Labrador Retriever

SEX

Spayed Female

AGE

8 Years

WEIGHT

50 Pounds

INTERPRETED BY

Eric Lindquist, DMV
DABVP, Cert. IVUSS

IMAGING PERFORMED BY

Shari Reffi, CVT

HOSPITAL NAME

Shohola

REFERRING VET

Dr. DeMeo

INVOICE

16568

DATE

7/11/22

- Infectious:
 - FeLV
 - FIP
 - Bacterial endocarditis
 - Adenovirus
 - Pyometra
 - Ehrlichiosis
 - Leptospirosis
 - Chronic bacterial infections
- Inflammatory:
 - Pancreatitis
 - Systemic lupus erythematosus (SLE)
 - Chronic inflammatory skin disease
 - Polyarthritis
 - Chronic hepatopathies
 - Chronic gastro-enteropathies
- Neoplasia:
 - Lymphoma
 - Mast cell tumours
 - Other
- Metabolic/toxic:
 - Corticosteroids
 - Diabetes mellitus
 - Captopril
 - Pencillamine
 - Sulphonamides
 - Vaccines
 - Mercury
 - Bee stings
- Idiopathic
- Possibly familial

Potential mechanisms involved in glomerular injury include:

- Deposition of preformed, circulating immune complexes in the GBM.
- In situ reaction of antibody with exogenous (planted) antigens or intrinsic glomerular antigens.
- Cell-mediated immune reactions.
- Complement-mediated damage.
- Deposition of amyloid protein.
- Hemodynamic forces (i.e., altered renal blood flow, systemic or glomerular hypertension).
- Hyperlipidaemia.
- Intrarenal coagulation.



PATIENT

Danika Lauricello

SPECIES

Canine

BREED

Labrador Retriever

SEX

Spayed Female

AGE

8 Years

WEIGHT

50 Pounds

INTERPRETED BY

Eric Lindquist, DMV
DABVP, Cert. IVUSS

IMAGING PERFORMED BY

Shari Reffi, CVT

HOSPITAL NAME

Shohola

REFERRING VET

Dr. DeMeo

INVOICE

16568

DATE

7/11/22

The most common inciting cause of GN is the deposition of preformed, circulating immune complexes in the GBM. In certain instances, immunoglobulins may combine with antigens previously planted in the GBM. Primary autoimmune GN occurs when antibodies react against native GBM proteins; however, this has not been reported in companion animals. Any infectious, inflammatory, parasitic, neoplastic, or degenerative disease process that results in sustained antigenic stimulation can lead to immune-mediated glomerular damage. Yet, in the vast majority of animal cases the antigen source or underlying disease process cannot be identified, and the glomerular disease is thus labelled idiopathic.

The presence of immune complexes in the GBM triggers a cascade of immunologic reactions resulting in damage caused by bioactive mediators (e.g. cytokines, nitric oxide, eicosanoids, complements, growth factors) that are either directly produced by glomerular cells or recruited by circulating blood cells, especially thrombocytes and neutrophils.

Because the inciting cause of GN is rarely known, it is usually characterized by its histological description:

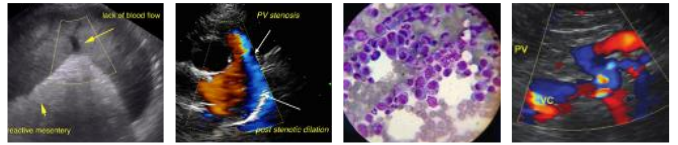
- Membranous GN
- Proliferative GN: increased glomerular cellularity
- Membranoproliferative GN: a combination of membranous and proliferative GN
- Glomerulosclerosis: glomerular scarring associated with increased mesangial matrix deposition

Membranous GN is the most common histological finding. It is generally associated with heavy proteinuria and frequently follows an insidiously progressive course that results in renal failure. Membranoproliferative (mesangiocapillary) glomerulonephropathy is also common in dogs. Late-stage membranous GN is difficult to distinguish definitively from membranoproliferative GN without the help of electron microscopy. Proliferative glomerulopathy generally presents with a fulminating course. Glomerulosclerosis is the end-stage of chronic inflammatory or degenerative renal diseases in which the glomeruli have been replaced by hyaline or fibrotic material.

Amyloid is deposited mainly in the glomeruli; however, in cats, it may also be deposited in the interstitium of the medulla. It is produced by mononuclear macrophage cells from amyloidogenic glycoproteins. In cases of chronic inflammation, serum amyloid protein A is produced by hepatocytes and in plasma cell dyscrasia, amyloid AL is produced by light-chain immunoglobulins. Glomerular amyloidosis can result in proteinuria, nephrotic syndrome, and ultimately, renal failure. Medullary amyloidosis in cats produces no clinical signs but may cause renal medullary necrosis.

Glomerular dysfunction can result in one or more of the following:

- Chronic renal disease.



PATIENT

Danika Lauricello

SPECIES

Canine

BREED

Labrador Retriever

SEX

Spayed Female

AGE

8 Years

WEIGHT

50 Pounds

INTERPRETED BY

Eric Lindquist, DMV
DABVP, Cert. IVUSS

IMAGING PERFORMED BY

Shari Reffi, CVT

HOSPITAL NAME

Shohola

REFERRING VET

Dr. DeMeo

INVOICE

16568

DATE

7/11/22

- Moderate to severe protein loss that can lead to negative nitrogen balance and hypoalbuminaemia, and culminate in nephrotic syndrome.
- Altered drug metabolism as hypoalbuminaemia may reduce binding and increase circulating levels of free drugs.
- Hyperlipidaemia.
- Predisposition to thromboembolic disease because of increases in factors V, VII, VIII, and X; decreases in anti-thrombin III; and altered platelet function.
- Arterial hypertension, which is a common complication of glomerular disease. It can affect up to 80% of dogs with GN and may in turn promote progressive renal damage.
- Low circulating levels of cholecalciferol and thyroxin, which may occur due to urinary protein loss.

Diagnostics: All ages and breeds of dogs and cats are susceptible to proteinuria, with a higher incidence occurring in animals over 5 years of age. There is a slight breed predilection in dogs for Labradors, Golden Retrievers, and Miniature Schnauzers, whereas in cats, there appears to be a sex predilection: 75% of cases occur in males. Familial GN has been reported in the following canine breeds: Doberman, Samoyed, Cocker Spaniel, Soft-coated Wheaten Terrier, Greyhound, Bernese Mountain Dog, Newfoundland, Rottweiler, and Bull Terrier. Familial amyloidosis has been reported in Abyssinian, Siamese, and Oriental Shorthair cats, as well as Shar Pei dogs. Other dog breeds overrepresented for amyloidosis are Collies, Beagles, and Walker Hounds.

Because many cases of GN are secondary to occult disease, one must conduct a careful history and undertake a full clinical examination. One report on dogs with GN found that approximately 50% of the subjects had a concurrent neoplastic, infectious, inflammatory, or immune-mediated disease at postmortem. Specific clinical abnormalities associated with glomerular injury may be subtle (e.g. weight loss, poor hair coat) or absent unless the animal is in renal failure. Edema, ascites, or pleural effusion is present in animals with nephrotic syndrome. Renal size may be normal, increased in cases of amyloidosis and acute GN, or decreased in cases of glomerulosclerosis or chronic GN. Hematuria with red blood cell casts may be found in animals with GN.

Shar Pei dogs with amyloidosis may have pyrexia, swollen hocks, and/or a swollen muzzle. Clinical signs of hepatic involvement may be present in affected Shar Pei dogs and Abyssinian, Oriental Shorthair, and Siamese cats.

Occasionally, animals may present with signs attributable to thromboembolism (i.e., dyspnea due to pulmonary thromboembolism and hind limb paresis due to aortic thromboembolism). Some animals may present with acute blindness associated with hypertensive retinal detachment.

Persistent proteinuria with a negative sediment or accompanied by hyaline or granular casts in the urine sediment is suggestive of glomerular disease. In early cases, the urine dipstick may in fact be negative for



PATIENT

Danika Lauricello

proteinuria, as the concentration of protein is extremely low. False negatives can be avoided if one tests for microalbuminuria; however, this test is currently only available for dogs.

SPECIES

Canine

Animals with glomerular amyloidosis generally have the highest urine protein-creatinine (UPC) ratio. Animals with medullary amyloidosis may not display significant proteinuria early on in the course of their disease.

BREED

Labrador Retriever

In sum, a full investigation into the etiology of renal proteinuria would include the following:

SEX

Spayed Female

- History and full physical examination
- Full urine analysis
- Hematology
- Urine culture
- Serum protein (albumin and globulin) levels with electrophoresis
- Serum urea and creatinine
- UPC ratio and quantification of urine protein loss
- ANA titer
- Abdominal ultrasonography
- Survey thoracic radiographs
- Serology or PCR (leptospirosis, toxoplasmosis, FeLV, FIV, *Ehrlichia*)
- Renal biopsy (histopathology, electron microscopy, and immunofluorescence)

AGE

8 Years

WEIGHT

50 Pounds

INTERPRETED BY

Eric Lindquist, DMV
DABVP, Cert. IVUSS

Treatment: To date, the ideal treatment plan for GN in dogs and cats has not been established. Despite whether one has access to the appropriate histopathological information based on biopsy results, it remains difficult to determine the optimal treatment plan. Even results from studies with human patients are, in many cases, conflicting. In some cases, therapies have succeeded in alleviating the signs of proteinuria without improving survival times. This seems paradoxical given the relationship, noted in many studies, between the magnitude of proteinuria and disease progression.

IMAGING PERFORMED BY

Shari Reffi, CVT

HOSPITAL NAME

Shohola

REFERRING VET

Dr. DeMeo

Because higher protein diets promote a greater magnitude of proteinuria, depleting the body's albumin pool, veterinarian researchers have long recommended high-quality, low-protein diets. Recently, however, the practice of protein restriction has come into question for certain types of GN in humans. It may be the case that higher protein diets can be fed without inducing a greater magnitude of proteinuria if they are administered together with an angiotensin-converting enzyme (ACE) inhibitor or an anti-thrombin antagonist.

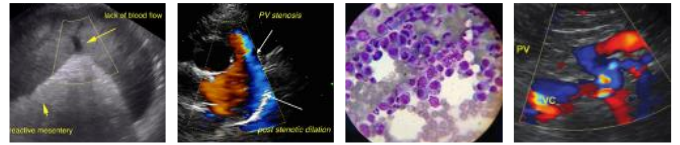
INVOICE

16568

ACE inhibitors have been shown to reduce proteinuria in both dogs and humans with GN. In humans, improvements in lipid abnormalities (e.g. hypercholesterolemia, hyperlipoproteinemia) have also been clearly demonstrated. Moreover, angiotensin receptor blockers, such as Losartan, can also be used, starting at a 1 mg/kg BID.

DATE

7/11/22



PATIENT

Danika Lauricello

Mini-dose aspirin is used routinely to minimize risks of hypercoagulability. Studies have shown that the administration of thromboxane inhibitors on a limited basis in dogs can be successful; omega-3 fatty acids may also be of benefit.

SPECIES

Canine

Perhaps the most controversial and difficult aspect of GN therapy is deciding whether to use immunosuppressive agents, and if so, determining which type is most suitable. Corticosteroids are indicated when an underlying corticosteroid-responsive disease is identified (i.e., SLE). The current view is that idiopathic GN in humans does not appear to be especially responsive to glucocorticoids, which contradicts earlier studies that suggested otherwise. By contrast, there is convincing evidence that cytotoxic therapy with cyclophosphamide or chlorambucil has benefit in idiopathic membranous GN, especially when instituted early on in the disease. Other drugs that can be used are chlorambucil, cyclophosphamide, and cyclosporine. Many of the human studies that have evaluated chlorambucil use also involved some months of treatment with pulsed methylprednisolone to reduce of the risk of leukopenia as a result of taking chlorambucil.

BREED

Labrador Retriever

SEX

Spayed Female

AGE

8 Years

References:

WEIGHT

50 Pounds

Grauer GF. Canine glomerulonephritis: new thoughts on proteinuria and treatment. *J Small Anim Pract* 2005;46:469-70.

INTERPRETED BY

Eric Lindquist, DMV
DABVP, Cert. IVUSS

Grauer GF. Measurement, interpretation, and implications of proteinuria and albuminuria. *Vet Clin North Am Small Anim Pract* 2007;37:283-95.

IMAGING PERFORMED BY

Shari Reffi, CVT

Harley L, Langston C. Proteinuria in dogs and cats. *Can Vet J* 2012;53:631-38.

HOSPITAL NAME

Shohola

Lees GE, Brown SA, Elliott J, Grauer GE, Vaden SL. Assessment and management of proteinuria in dogs and cats: 2004 ACVIM Forum Consensus Statement (Small Animal). *J Vet Intern Med* 2005;19:377-85.

REFERRING VET

Dr. DeMeo

Littman MP. Protein-losing nephropathy in small animals. *Vet Clin North Am Small Anim Pract* 2011;41:31-62.

INVOICE

16568

DATE

7/11/22