SonoPath

Clinical Sonography & Telecytology

EDUCATIONAL TELECONSULTATION SERVICES™

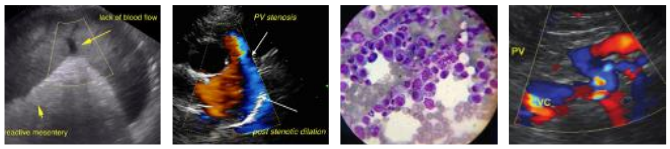

SonoPath.com™
1-800-838-4268 info@sonopath.com

PATIENT

Beaumont Ferrer

SPECIES

Canine

BREED

Pomeranian

SEX

Neutered Male

AGE

14 Years 8 Months

WEIGHT

15 Years

INTERPRETED BY

Eric Lindquist, DMV DABVP, Cert. IVUSS

IMAGING PERFORMED BY

Jessica Miller

HOSPITAL NAME

Banfield PH of Bridgewater

REFERRING VET

Dr. Baker

INVOICE

16571

DATE

7/11/22

PRESENTING CLINICAL SIGNS

History: Episodes of lethargy, limping (6/11). Hx of hyperadrenocorticism- not currently on meds do to concern for Addison's. Current meds: maropitant, sucralfate, omeprazole

Abnormal PE/Chem/CBC/UA Results: ALKP 1904, Chole 388 UA: protein 300 SG: 1.026

ULTRASONOGRAPHIC EXAMINATION OF THE ABDOMEN

Urinary System

The **urinary bladder**, trigone, and pelvic urethra presented normal thicknesses and normal tone. The ureters were not visible which is normal. No uroliths or sediment were visualized, and anechoic urine was present. No evidence of inflammatory or neoplastic changes were noted. Ureteral papillae were normal. The pelvic urethra was imaged 3.0 cm beyond the cystourethral junction. The residual prostate measured 4.0 mm.

The **kidneys** revealed largely normal size and structure, corticomedullary definition and ratio (cortex 1/3 of medulla) were essentially maintained with some mild age-related loss of curvilinear patterns regarding the capsule and C/M junction. The cortices presented largely uniform texture with some increased echogenicity expected for his age patient. Medullary structure differed distinctly from that of the cortex. Slight pyelectasia was noted. Occasional cortical cysts were noted. The right kidney measured 5.5 cm. The left kidney measured 5.2 cm.

Adrenal Glands

The **adrenal glands** appeared slightly enlarged and swollen. No evidence of focal capsular expansion or invasion into the phrenic veins were noted. No overt suspicion of neoplasia was noted. This is considered likely a hyperplastic change associated with stress or adrenal endocrinopathy (PDH). If isosthenuria is persistently present and the patient morphologically suggests Cushing's disease then ACTH testing would be indicated. The left adrenal gland measured 1.86 cm x 0.61 cm at the caudal pole and 0.66 cm at the cranial pole. The right adrenal gland measured 1.79 cm x 0.63 cm at the caudal pole and 0.91 cm at the cranial pole.

Spleen

The **spleen** was normal size and relatively normal contour with multifocal hyperechoic areas of mineralization. This is a benign change; however, can be related to Cushing's disease or other endocrinopathies.

Liver

The **liver** revealed heterogeneous changes. Gallbladder debris was noted. Echogenic debris or tissue proliferation was noted in the common bile duct. This change is consistent with mucoduct, however, proliferative tissue, such as carcinoma, cannot be completely ruled out. The common bile duct is excessive at 6.0 mm, which technically is a surgical bile duct. The common bile duct was followed to the duodenal papilla, where a minor cystic structure was noted. A separate nodular change and thickening was noted at the duodenal papilla, measuring approximately 2.0 cm x 1.0 cm, color flow assessment revealed that this is a tissue proliferation, however, the other portions of echogenic debris within the common bile duct may be mucus.

Gastrointestinal

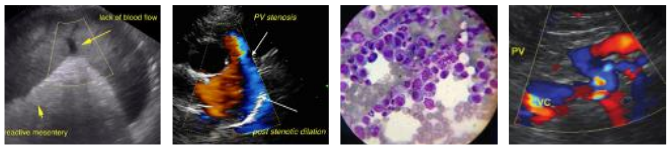

SonoPath.com
1-800-838-4268 info@sonopath.com

PATIENT

Beaumont Ferrer

SPECIES

Canine

BREED

Pomeranian

SEX

Neutered Male

AGE

14 Years 8 Months

WEIGHT

15 Years

INTERPRETED BY

Eric Lindquist, DMV
DABVP, Cert. IVUSS

IMAGING PERFORMED BY

Jessica Miller

HOSPITAL NAME

Banfield PH of Bridgewater

REFERRING VET

Dr. Baker

INVOICE

16571

DATE

7/11/22

The **stomach** itself was unremarkable. Soft stool was noted in the colon.

Pancreas

The base and limbs of the **pancreas** were observed to be largely isoechoic to surrounding omental fat. Pancreatic duct and capsular contour were acceptably normal and parenchyma respected normal curvilinear patterns. No overt evidence of active inflammatory or neoplastic disease was noted.

ULTRASONOGRAPHIC FINDINGS

- Mild bilateral adrenal hypertrophy
- Heterogeneous liver with gallbladder debris and common bile duct tumor at the duodenal papilla, mucoduct or proliferative tumor within the remainder of the common bile duct.
- Splenic mineralization
- Age-related renal changes

INTERPRETATION OF THE FINDINGS & FURTHER RECOMMENDATIONS

PDH/Cushings is likely underlying, however, the common bile duct pathology is most important. I recommend surgical exploratory with expectations of bile duct deviation procedure, if possible, if surgically rectifiable. The presentation is evident. Prognosis is very guarded.

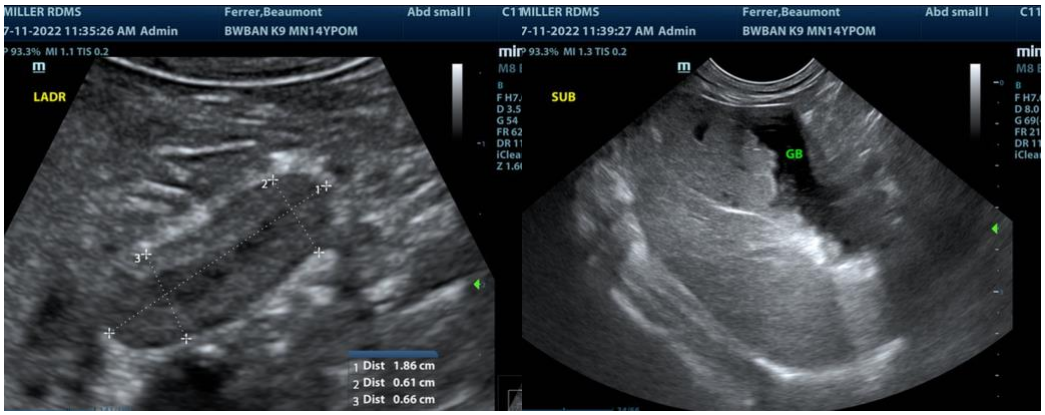

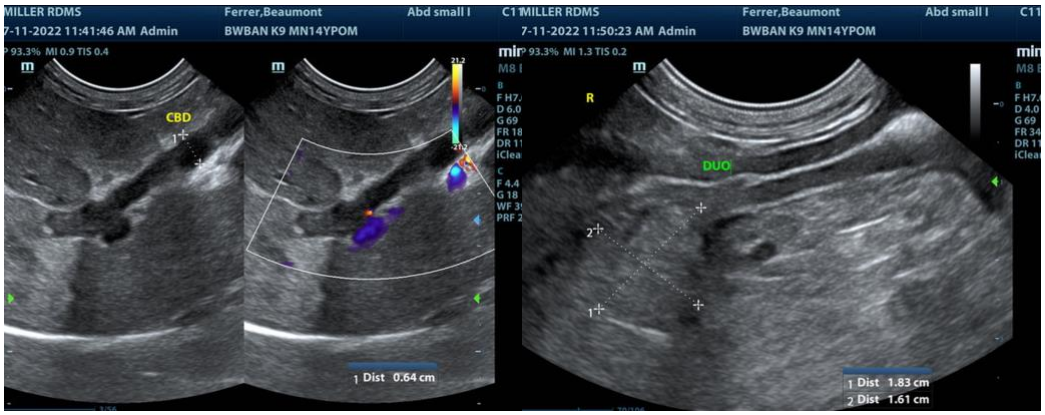

SonoPath

Clinical Sonography & Telecytology

EDUCATIONAL TELECONSULTATION SERVICES™

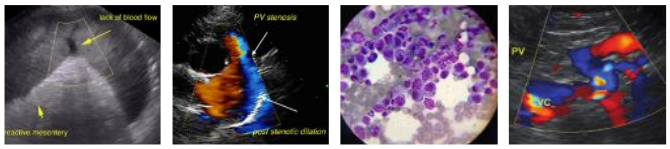

SonoPath.com™
1-800-838-4268 info@sonopath.com

PATIENT

Beaumont Ferrer

SPECIES

Canine

BREED

Pomeranian

SEX

Neutered Male

AGE

14 Years 8 Months

WEIGHT

15 Years

INTERPRETED BY

Eric Lindquist, DMV
DABVP, Cert. IVUSS

IMAGING PERFORMED BY

Jessica Miller

HOSPITAL NAME

Banfield PH of Bridgewater

REFERRING VET

Dr. Baker

INVOICE

16571

DATE

7/11/22

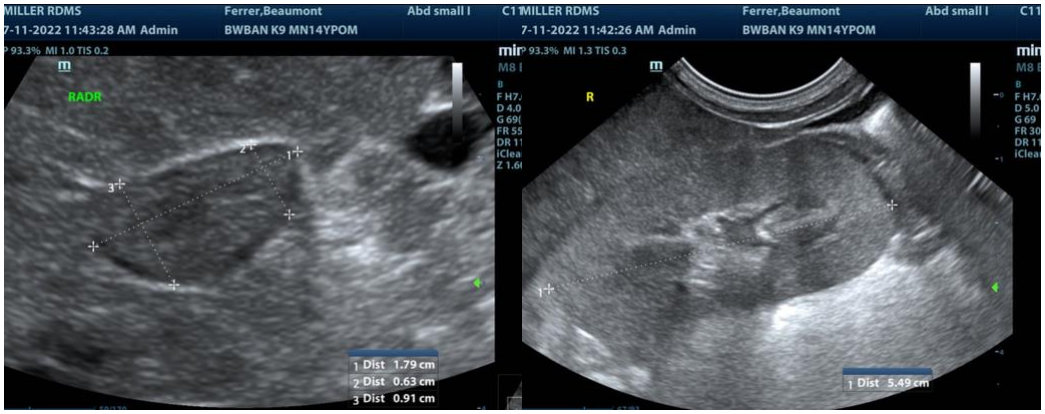

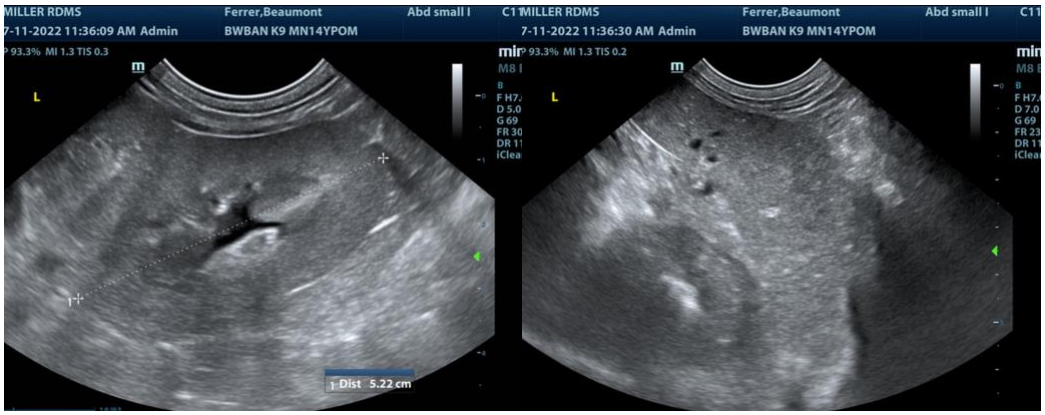

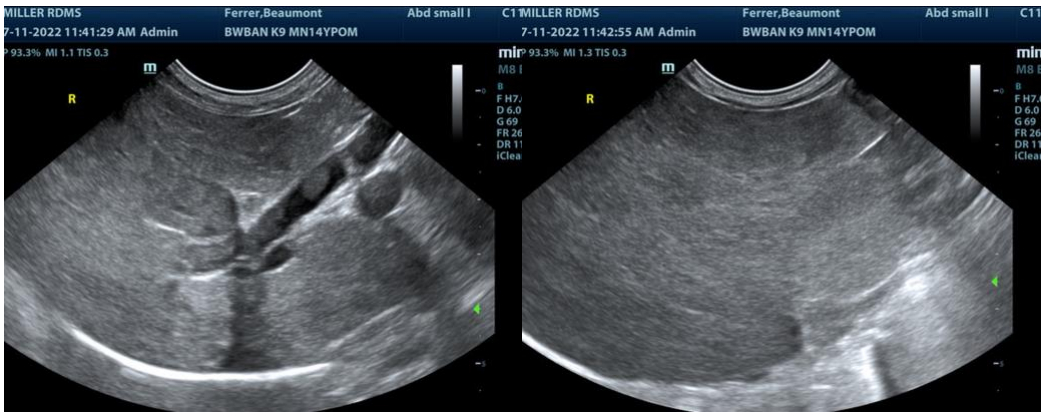

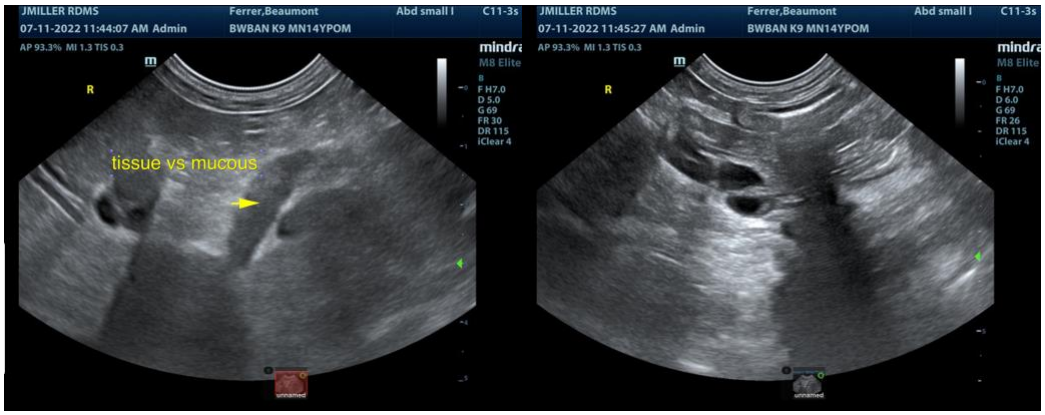

SonoPath
Clinical Sonography & Telecytology

EDUCATIONAL TELECONSULTATION SERVICES™

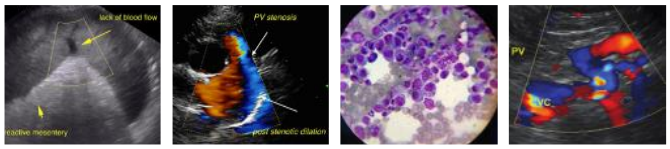

SonoPath.com
1-800-838-4268 info@sonopath.com

PATIENT

Beaumont Ferrer

SPECIES

Canine

BREED

Pomeranian

SEX

Neutered Male

AGE

14 Years 8 Months

WEIGHT

15 Years

INTERPRETED BY

Eric Lindquist, DMV DABVP, Cert. IVUSS

IMAGING PERFORMED BY

Jessica Miller

HOSPITAL NAME

Banfield PH of Bridgewater

REFERRING VET

Dr. Baker

INVOICE

16571

DATE

7/11/22

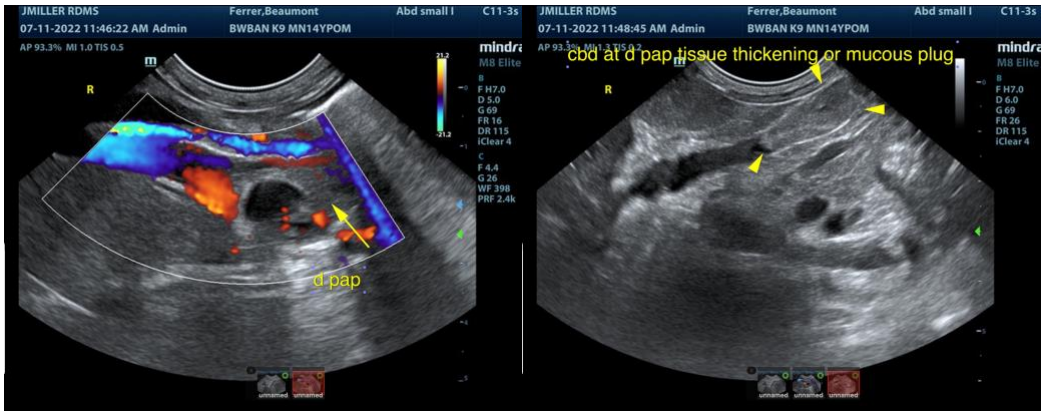

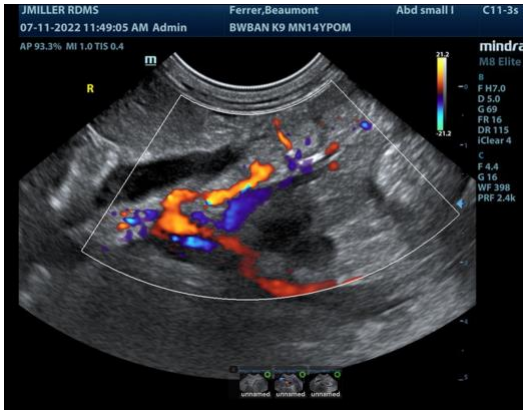

The information and recommendations provided are based on the images presented by the referring veterinarian. No evaluation can be communicated regarding pathology that was not visible in the image/video clips provided.

Thank you for this referral. If the clinical or image interpretation does not parallel your findings or if I can be of any further assistance please contact me.

Eric Lindquist, DMV, DABVP, Cert. IVUSS, CEO of SonoPath.com
info@SonoPath.com