



PATIENT	PRESENTING CLINICAL SIGNS
Pepper Wallman	losing weight, lethargic, didnt want to eat for a stretch of time and then started eating and then would stop again, excessive drinking, straining in box, abdominal mass on lactulose 1mL BID
SPECIES	Abnormal PE/Chem/CBC/UA Results: 7/9/23 : WBC - 25.7(hi), RBC - 3.5(lo), Neu- 94(hi), Lymph - 4(lo), hemoglobin- 5.5(lo) HCT- 19(lo) MCHC-29(lo), Platelet cnt- 750(hi), EOS-1(lo) , Abs. Neu- 24158(hi), calc- 14.8(hi), mag - 2.7(hi), MA/K - 30(lo), Chol- 253(hi), abs. lymph- 1028(lo), T4- 0.7(lo), Urea Nit- 88(hi), BUN/Creat- 37(hi)
Feline	
BREED	ULTRASONOGRAPHIC EXAMINATION OF THE ABDOMEN
DSH	Urinary System
SEX	The urinary bladder, trigone, and pelvic urethra presented normal thicknesses and normal tone. The ureters were not visible which is normal. No uroliths or sediment were visualized, and anechoic urine was present. No evidence of inflammatory or neoplastic changes were noted. Ureteral papillae were normal.
FS	
AGE	The kidneys revealed largely normal size and structure, corticomedullary definition and ratio (cortex 1/3 of medulla) were essentially maintained with mild age-related loss of curvilinear patterns regarding the capsule and C/M junction. The cortices presented largely uniform texture with some increased echogenicity expected for his age patient. Medullary structure differed distinctly from that of the cortex and no evidence of pelvic dilation was present. The left kidney measured 3.0 cm in length. The right kidney measured 3.0 cm in length.
15yr	
WEIGHT	Adrenal Glands
4.6lb	The left and right adrenal glands were not definitively visualized. No obvious pathology was present in the area of the bilateral adrenal glands.
INTERPRETED BY	Spleen
Eric Lindquist, DMV DABVP, Cert. IVUSS	The spleen was displaced out of view.
IMAGING PERFORMED BY	Liver
Heather	The liver was hypoechoic and mildly irregular. The gallbladder presented acceptably thin walls with primarily anechoic content. The cystic and common bile ducts were normal. No pathological hepatic lymphadenopathy was evident. No overt structural evidence of inflammatory, infiltrative or regenerative pathology was evident.
HOSPITAL NAME	Gastrointestinal
Animal Care Clinic of Flanders	Examination of the gastrointestinal tract revealed an ileocecal junction infiltrative mass measuring ~ 5.0 cm length x 4.0 cm width. Multiple undifferentiated enlarged hypoechoic lymph nodes with regional inflammation was present. This pathology extended through the pancreas with overlaying distorted lymph nodes. Other portions of the small intestine were unremarkable.
REFERRING VET	Pancreas
Dr. Hargadon	The base and limbs of the pancreas were observed to be largely isoechoic to surrounding omental fat. Pancreatic duct and capsular contour were acceptably normal, and parenchyma respected normal curvilinear patterns. No overt evidence of active inflammatory or neoplastic disease was noted.
INVOICE	
14354ag	
DATE	
07/10/2023	



PATIENT

Pepper Wallman

ULTRASONOGRAPHIC FINDINGS

- Multicentric aggressive neoplasia involving lymph nodes, intestine and possibly liver.

SPECIES

Feline

INTERPRETATION OF THE FINDINGS & FURTHER RECOMMENDATIONS

FNA of the affected lymph nodes/liver is indicated. This is an aggressive process.

BREED

DSH

SEX

FS

AGE

15yr

WEIGHT

4.6lb

INTERPRETED BY

Eric Lindquist, DMV
DABVP, Cert. IVUSS

IMAGING PERFORMED BY

Heather

HOSPITAL NAME

Animal Care Clinic of
Flanders

REFERRING VET

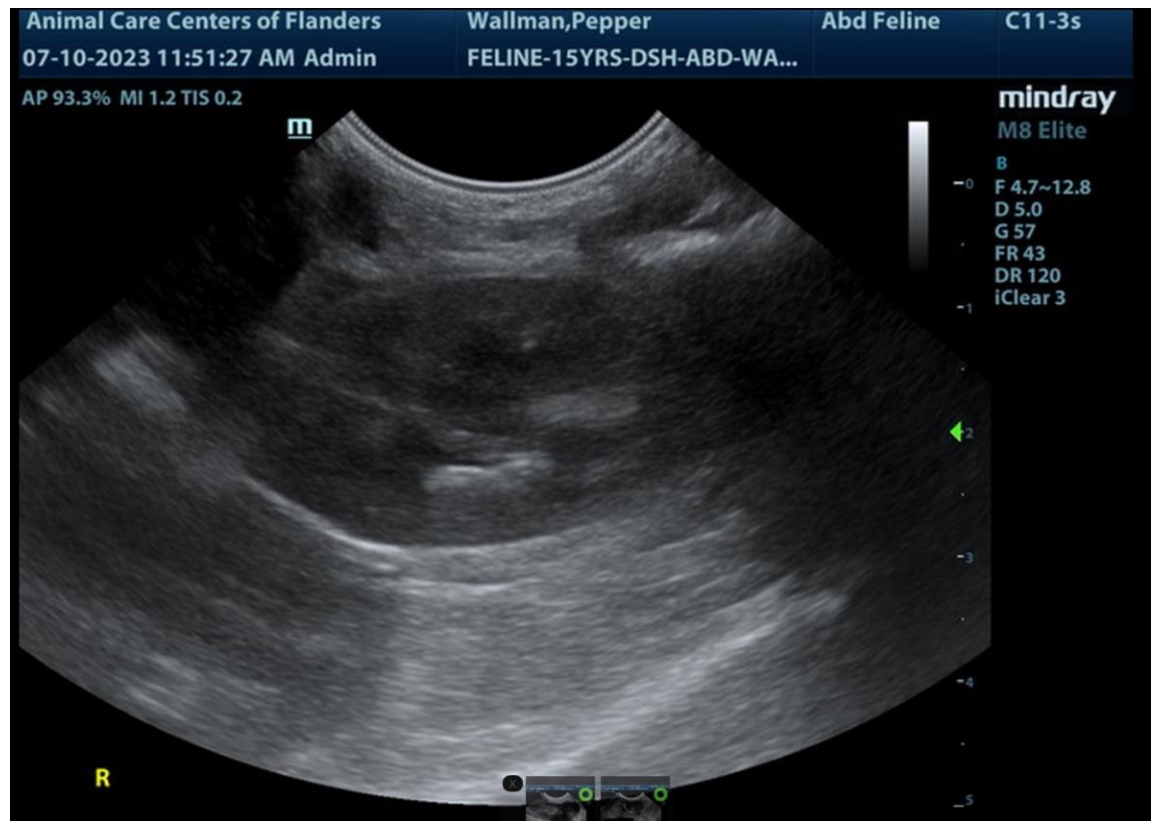Dr. Hargadon

INVOICE

14354ag

DATE

07/10/2023





PATIENT
Pepper Wallman

SPECIES

Feline

BREED

DSH

SEX

FS

AGE

15yr

WEIGHT

4.6lb

INTERPRETED BY

Eric Lindquist, DMV
DABVP, Cert. IVUSS

IMAGING PERFORMED BY

Heather

HOSPITAL NAME

Animal Care Clinic of
Flanders

REFERRING VET

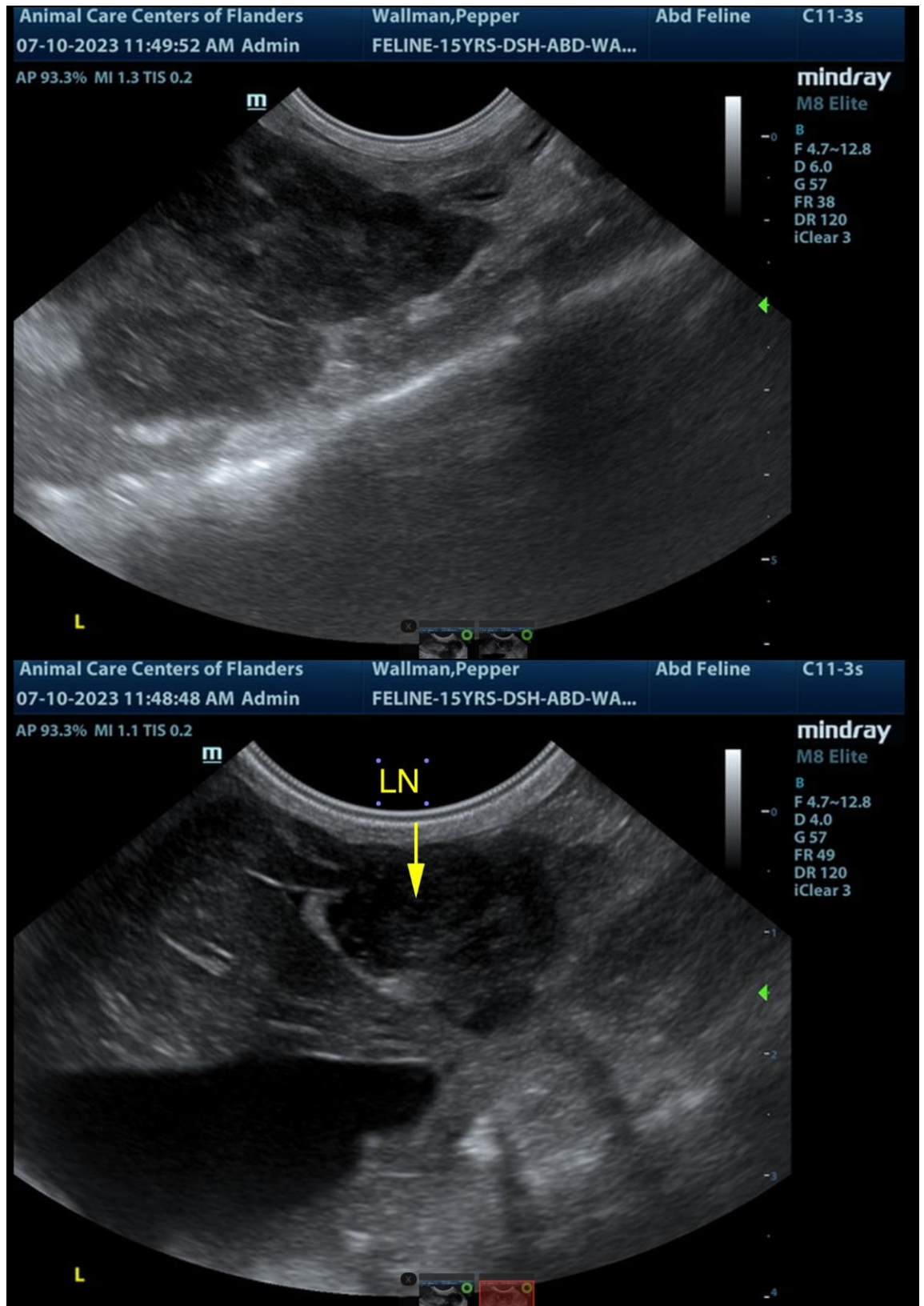
Dr. Hargadon

INVOICE

14354ag

DATE

07/10/2023





PATIENT

Pepper Wallman

SPECIES

Feline

BREED

DSH

SEX

FS

AGE

15yr

WEIGHT

4.6lb

INTERPRETED BY

Eric Lindquist, DMV
DABVP, Cert. IVUSS

IMAGING PERFORMED BY

Heather

HOSPITAL NAME

Animal Care Clinic of
Flanders

REFERRING VET

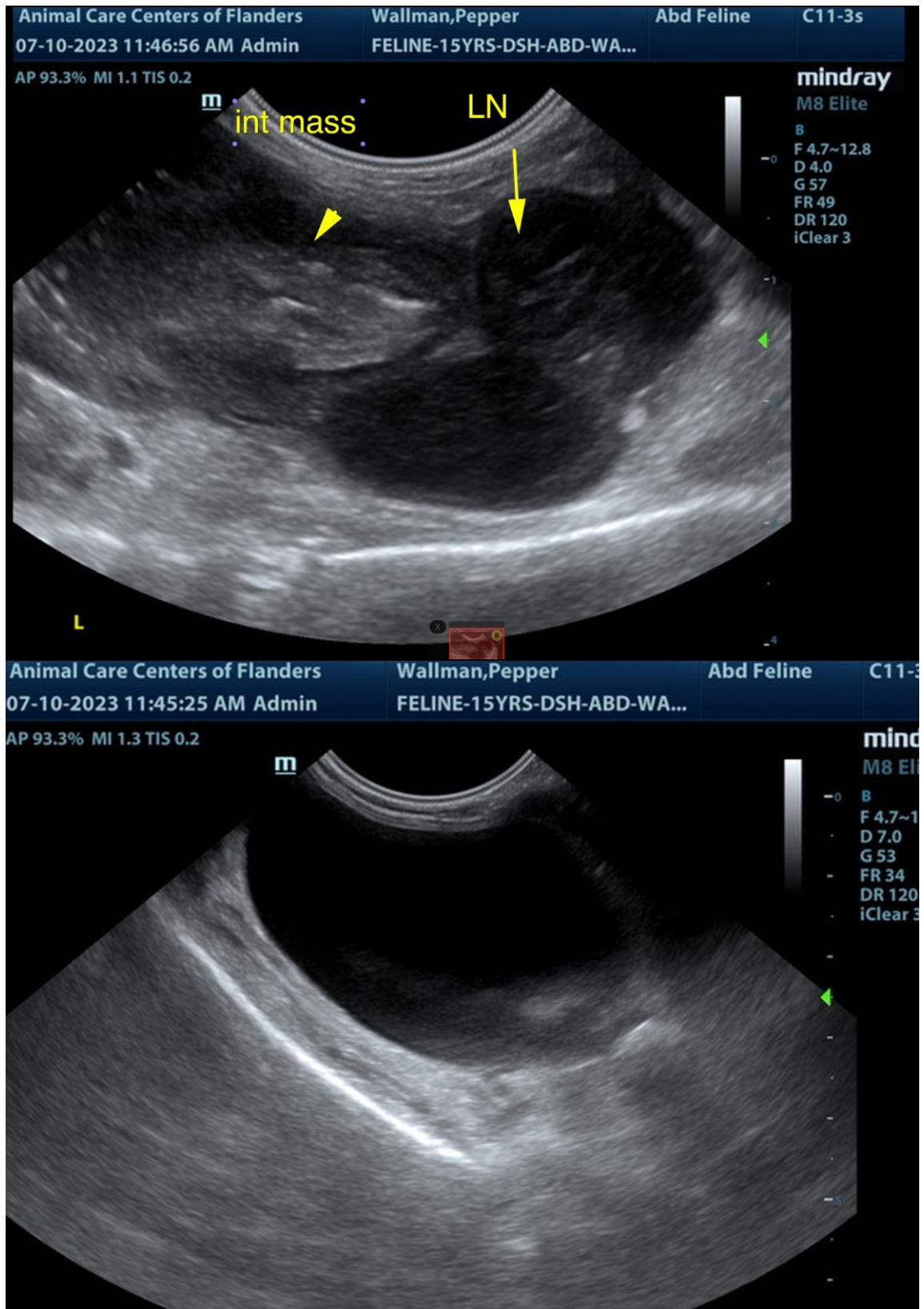
Dr. Hargadon

INVOICE

14354ag

DATE

07/10/2023



Eric Lindquist DMV, DABVP (CFM), Cert. IVUSS
CEO/Founde



PATIENT

Pepper Wallman

The information and recommendations provided are based on the images presented by the referring veterinarian/sonographer. No evaluation can be communicated regarding pathology that was not visible in the image/video clips provided.

SPECIES

Feline

Thank you for this referral. If the clinical or image interpretation does not parallel your findings or if I can be of any further assistance, please contact me.

BREED

DSH

Eric Lindquist, DMV, DABVP, Cert. IVUSS, CEO of SonoPath.com
Eric.Lindquist@SonoPath.com

SEX

FS

AGE

15yr

WEIGHT

4.6lb

INTERPRETED BY

Eric Lindquist, DMV
DABVP, Cert. IVUSS

**IMAGING
PERFORMED BY**

Heather

HOSPITAL NAME

Animal Care Clinic of
Flanders

REFERRING VET

Dr. Hargadon

INVOICE

14354ag

DATE

07/10/2023