



PATIENT PRESENTING CLINICAL SIGNS

Cllover Walton

History: Presented for pre-dental exam. No concerning history. previous exam September 2022 was unremarkable.

SPECIES

Abnormal PE/Chem/CBC/UA Results: Grade 3/6 heart murmur, PMI left apex. Strong synchronous pulses with no arrhythmia. CBC/Chem pending. Thoracic radiographs unremarkable. VHS= 11. No left atrial enlargement visible.

Canine

BREED

ULTRASONOGRAPHIC EXAMINATION OF THE HEART

Cavalier King Charles Spaniel

The echocardiogram in this patient demonstrated normal **left atrial** size based on 3 different LA measurement methods. Chamber volumes and echogenicity were normal. The cranial and caudal **mitral** valve leaflets presented vegetative thickening consistent with endocardiosis. Doppler indicated measurable insufficiency. The **left ventricle** presented thicknesses with linear contour and was not dilated nor restricted. The **myocardium** presented normal echogenicity without subjective evidence of significant fibrotic or ischemic disease. **Contractility** of the ventricular walls was adequate and in normal range for this patient evidenced by the fractional shortening measurement and subjective evaluation of the different regions of the myocardium. The **left ventricular outflow** tract demonstrated normal laminar flow and subjective structural integrity. The **right atrium** and auricle revealed normal size, structure and content. No evidence of masses was noted or chamber overload. **Tricuspid** valvular assessment demonstrated adequate linear morphology. The **right ventricle** was of normal size (1/3 diameter of LV), chordae structure, myocardial echogenicity and thickness. Minor **pulmonic** insufficiency was noted. No visible **pericardial** or free pleura fluid was noted. No echographically detectable evidence of infiltrative disease was visible. The cranial **mediastinum and pericardial regions** were free of masses in the visible window.

SEX

Spayed female

AGE

6 years

WEIGHT

7.4 kg

INTERPRETED BY

Eric Lindquist, DMV DABVP, Cert. IVUSS

IMAGING PERFORMED BY

Dr. Varga

HOSPITAL NAME

Shuswap VC

REFERRING VET

Dr. Varga

CANINE CARDIAC PARAMETERS	MR VMAX (m/s)	TR VMAX (m/s)	LA/AO (Boon method)	LA/AO (Heart Base;)	FS (%)	EF (%)	EPSS (cm)
NORMAL PARAMETER	4.5-5.5	<2.7	1.3	Up to 1.6	28-40	40-100	<0.6
PATIENT			1.1	1.3	32	63	0.1
CANINE CARDIAC PARAMETERS	HR (BPM)	AV VMAX (m/s)	PV MAX (m/s)	BODY WEIGHT (kg)	LA (2D short axis Base view) (cm)	LVIDd (Avg; 2D and m-mode short axis) (cm)	LVIDs (Avg; 2D and m-mode short axis) (cm)
NORMAL PARAMETER	50-100	0.7-1.7	0.7-1.6	BELOW	BELOW	BELOW	BELOW
PATIENT			0.7	7.4 kg	2.67 max	2.24	

INVOICE

76006

DATE

7/10/23



PATIENT

Clover Walton

SPECIES

Canine

BREED

Cavalier King Charles
Spaniel

SEX

Spayed female

AGE

6 years

WEIGHT

7.4 kg

INTERPRETED BY

Eric Lindquist, DMV
DABVP, Cert. IVUSS

IMAGING PERFORMED BY

Dr. Varga

HOSPITAL NAME

Shuswap VC

REFERRING VET

Dr. Varga

INVOICE

76006

DATE

7/10/23

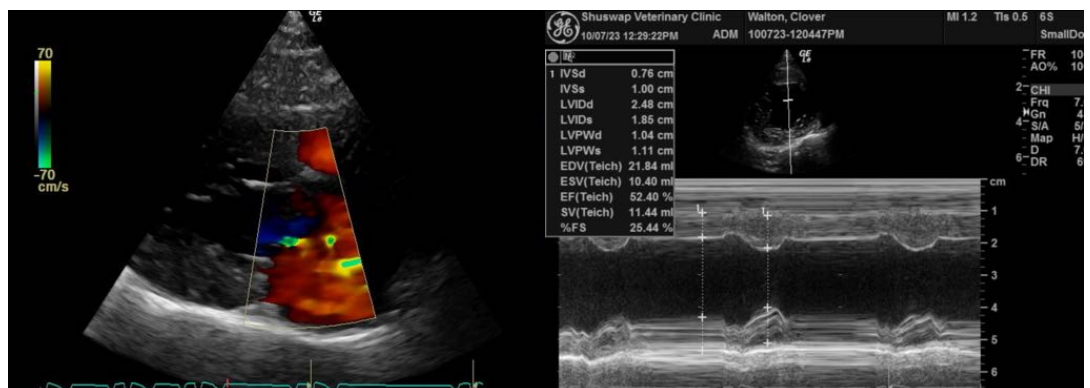
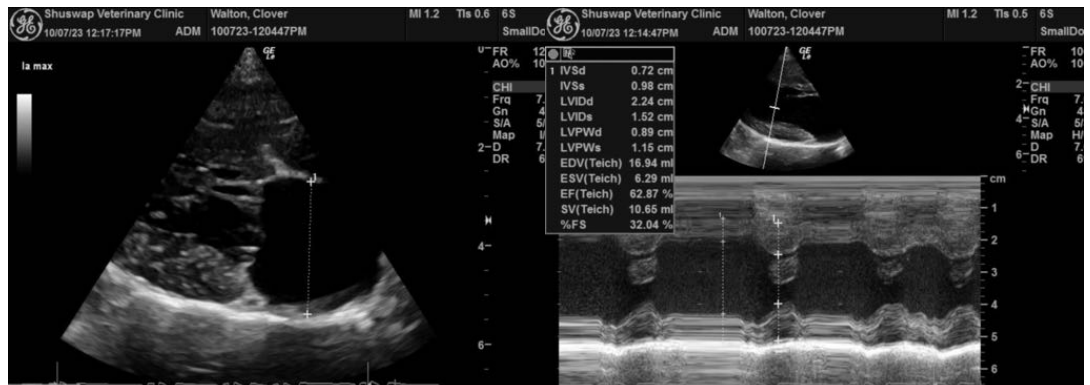ULTRASONOGRAPHIC FINDINGS

Mitral insufficiency, stage B1 valvular disease.

INTERPRETATION OF THE FINDINGS & FURTHER RECOMMENDATIONS

No treatment is necessary at this time.

The heart is stable without clinical disease. No overt contraindication for anesthesia of brief to moderate duration. I suggest Torbutrol premed, Propofol induction, Isoflo maintenance or similar protocol if anesthesia is desired. Blood pressure recommended if not already performed and target white coat negative systolic pressure of < 160 mmHg. If higher than this ACE-inhibitor is suggested to reach this level. Recheck echocardiogram is recommended in 6 months, earlier if murmur grade increases or clinical signs initiate.





PATIENT

Clover Walton

SPECIES

Canine

BREED

Cavalier King Charles
Spaniel

SEX

Spayed female

AGE

6 years

WEIGHT

7.4 kg

INTERPRETED BY

Eric Lindquist, DMV
DABVP, Cert. IVUSS

**IMAGING
PERFORMED BY**

Dr. Varga

HOSPITAL NAME

Shuswap VC

REFERRING VET

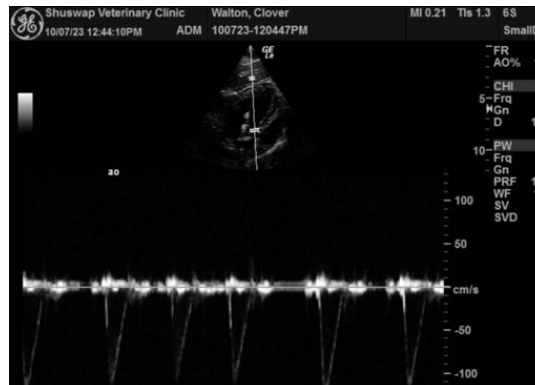
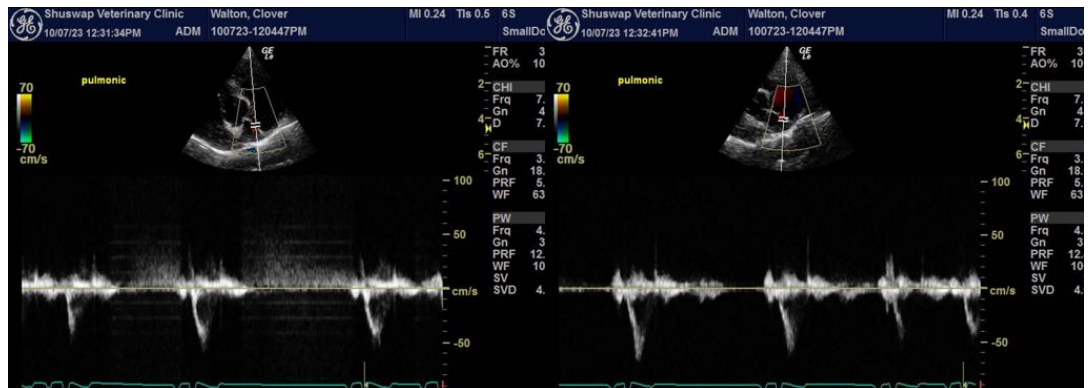Dr. Varga

INVOICE

76006

DATE

7/10/23



The information and recommendations provided are based on the images presented by the referring veterinarian/sonographer. No evaluation can be communicated regarding pathology that was not visible in the image/video clips provided.

Thank you for this referral. If the clinical or image interpretation does not parallel your findings or if I can be of any further assistance please contact me.

Eric Lindquist, DMV, DABVP, Cert. IVUSS, CEO of SonoPath.com
info@SonoPath.com