



**PATIENT**

Scarlett Fink

**SPECIES**

Canine

**BREED**

Dachshund

**SEX**

Spayed Female

**AGE**

10 Years

**WEIGHT**

10 Pounds

**INTERPRETED BY**

Eric Lindquist, DMV  
DABVP, Cert. IVUSS

**IMAGING PERFORMED BY**

Kelly Vazquez

**HOSPITAL NAME**

Marsh AH

**REFERRING VET**

Dr. Milwicki

**INVOICE**

16433

**DATE**

7/1/22

**PRESENTING CLINICAL SIGNS**

History: Chronic rhinitis/bronchitis. Coughing more recently. Radiographs - Suspected large main pulmonary artery could be due to idiopathic pulmonary hypertension, subclinical pulmonary stenosis, or heartworm disease. No radiographic evidence of pneumonia is found in this study. Mild nonspecific hepatomegaly Mild nonspecific hepatomegaly. Focal cranial abdominal peritoneal soft tissue nodule. Nonspecific heterogenous gastric, intestinal and colonic contents could represent normal ingesta. No small intestinal mechanical obstruction is seen. Current meds: hydrocodone, Albuterol inhaler, Potassium Citrate.

Abnormal PE/Chem/CBC/UA Results: Blood work: WNL.

**ULTRASONOGRAPHIC EXAMINATION OF THE HEART & ABDOMEN**

CANINE CARDIAC PARAMETERS	MR VMAX (m/s)	TR VMAX (m/s)	LA/AO (Boon method)	LA/AO (Heart Base; Swe)	FS (%)	EF (%)	EPSS (cm)
NORMAL PARAMETER	4.5-5.5	<2.7	1.3	<1.3	28-40	40-100	<0.6
PATIENT	--	--	1.1	1.2	37	69	0.1
CANINE CARDIAC PARAMETERS	HR (BPM)	AV VMAX (m/s)	PV MAX (m/s)	BODY WEIGHT (kg)	LA 2D short axis Base view (cm)	LVIDd Avg; 2D and m-mode short axis (cm)	LVIDs Avg; 2D and m-mode short axis (cm)
NORMAL PARAMETER	50-100	0.7-1.7	0.7-1.6				
PATIENT	105	--	.70	--	2.2	2.29	--

**Cardiac Presentation**

The echocardiogram in this patient demonstrated normal **left atrial** size based on 3 separate methods of LA evaluation. The cranial and caudal **mitral** valve leaflets presented normal linear structure, extension in systole, and union in diastole with normal kinesis. The **left ventricle** presented thicknesses with linear contour and was not dilated nor restricted. The **myocardium** presented normal echogenicity without subjective evidence of significant fibrotic or ischemic disease. **Contractility** of the ventricular walls was adequate and in normal range for this patient evidenced by the fractional shortening measurement and subjective evaluation of the different regions of the myocardium. The **left ventricular outflow** tract demonstrated normal laminar flow and subjective structural integrity. The **right atrium** and auricle revealed normal size, structure and content. No evidence of masses was noted. **Tricuspid** valvular assessment demonstrated adequate linear morphology and kinesis. The **right ventricle** was of normal size (1/3 diameter of LV), chordae structure, myocardial echogenicity and thickness. **Pulmonary outflow** tract assessment revealed normal valve structure, laminar flow, and diameter (approx. 1:1 pa/ao ratio). No visible **pericardial** or



**PATIENT**

free pleura fluid was noted. The cranial **mediastinum and pericardial and extra-cardiac regions** were free of masses in the visible window.

Scarlett Fink

**Urinary System**

**SPECIES**

The **urinary bladder**, trigone, and pelvic urethra presented normal thicknesses and normal tone. The ureters were not visible which is normal. No uroliths or sediment were visualized and anechoic urine was present. No evidence of inflammatory or neoplastic changes were noted. Ureteral papillae were normal.

Canine

**BREED**

The **kidneys** revealed largely normal size and structure, corticomedullary definition and ratio (cortex 1/3 of medulla) were essentially maintained with some minor age-related loss of curvilinear patterns regarding the capsule and C/M junction. The cortices presented largely uniform texture with some increased echogenicity expected for his age patient. Medullary structure differed distinctly from that of the cortex and no evidence of pelvic dilation was present. Mineralization was present in the kidneys. The right kidney measured 4.05 cm. The left kidney measured 3.52 cm.

Dachshund

**SEX**

Spayed Female

**AGE**

10 Years

**Adrenal Glands**

Both **adrenal glands** were visualized and recognized as having normal shape, size, position and echogenicity for this breed. The phrenic vasculature, glandular echogenicity and detail were unremarkable. Capsule, cortex, and medullary definition were normal for this age patient. The right adrenal gland measured 1.14 cm x 0.49 cm at the caudal pole and 0.8 cm at the cranial pole. The left adrenal gland measured 1.32 cm x 0.43 cm at the caudal pole and 0.58 cm at the cranial pole.

**WEIGHT**

10 Pounds

**Spleen**

**INTERPRETED BY**

The **spleen** presented a smooth homogeneous parenchyma hyperechoic to liver and renal cortical parenchyma. The capsule was smooth without noticeable expansion or deviation from within the spleen or adjacent pathology. The splenic vasculature demonstrated normal volume without signs of congestion or thrombosis. No sonographic evidence of acute or chronic inflammatory, neoplastic, or infarctual changes were noted.

Eric Lindquist, DMV  
DABVP, Cert. IVUSS

**IMAGING PERFORMED BY**

**Liver**

The **liver** images from right and left intercostal as well as subcostal views revealed subjectively normal liver size, contour, and structure. Some minor age-related parenchymal remodeling was noted but likely not clinically significant at this time. Vascular and biliary tracts were of normal volume and no evidence of congestion was noted. The gallbladder presented some dependent debris with essentially normal contour. The cystic and common bile ducts were normal. No overt evidence of active inflammatory, infiltrative or regenerative pathology was noted but should be paired with current or past LE elevations regarding any clinical significance to this presentation. The hepatic lymph nodes were unremarkable.

Kelly Vazquez

**HOSPITAL NAME**

Marsh AH

**REFERRING VET**

Dr. Milwicki

**INVOICE**

16433

**DATE**

7/1/22



**PATIENT**

Scarlett Fink

upper gastrointestinal outflow due to primary or secondary pyloric hypertrophy, upper GI infiltrative disease, motor deficits, or a non-visualized foreign body. A prudent approach would be to rescan this patient at 24 hour NPO status to further review the non-visible regions if stomach primarily as well as assess any delayed outflow issue.

**SPECIES**

Canine

**Pancreas**

The base and limbs of the **pancreas** were observed to be largely isoechoic to surrounding omental fat. Pancreatic duct and capsular contour were acceptably normal and parenchyma respected normal curvilinear patterns. No overt evidence of active inflammatory or neoplastic disease was noted.

**BREED**

Dachshund

**ULTRASONOGRAPHIC FINDINGS**

**SEX**

Spayed Female

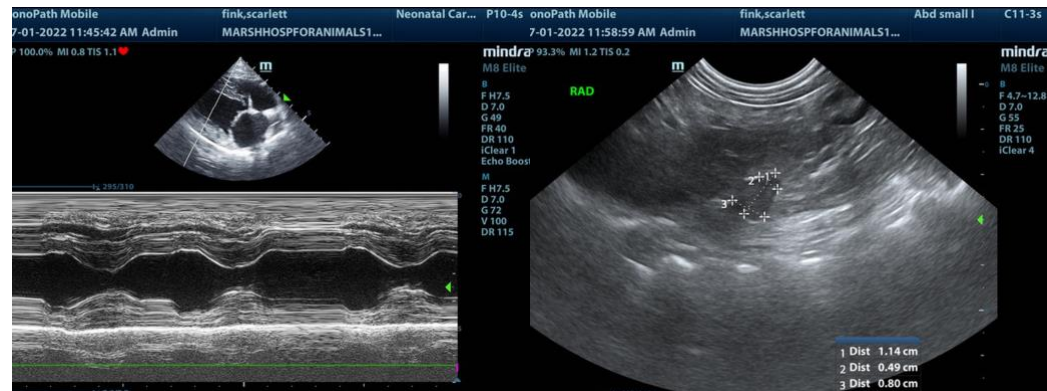
- Normal echocardiogram- the cough is not cardiogenic in this patient
- Age-related hepatic, pancreatic, and renal changes
- Partially full stomach

**INTERPRETATION OF THE FINDINGS & FURTHER RECOMMENDATIONS**

Primary respiratory protocol is recommended.

**AGE**

10 Years



**WEIGHT**

10 Pounds

**INTERPRETED BY**

Eric Lindquist, DMV  
DABVP, Cert. IVUSS

**IMAGING PERFORMED BY**

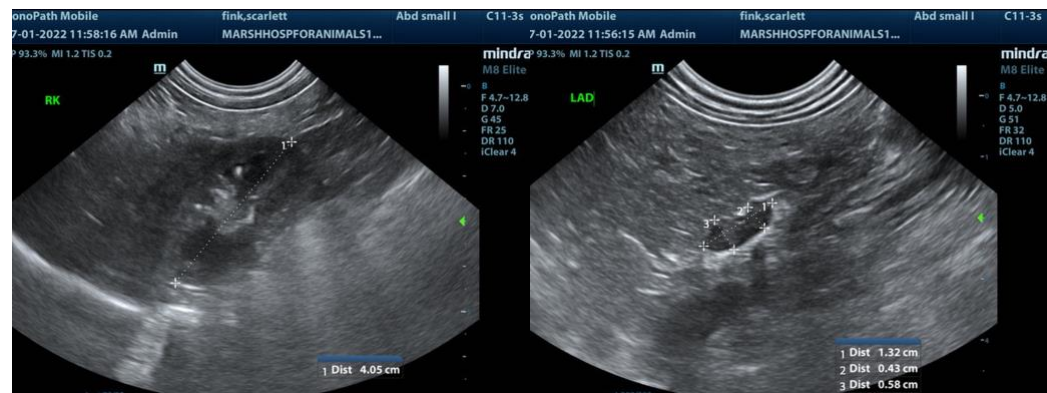
Kelly Vazquez

**HOSPITAL NAME**

Marsh AH

**REFERRING VET**

Dr. Milwicki



**INVOICE**

16433

**DATE**

7/1/22



**PATIENT**

Scarlett Fink

**SPECIES**

Canine

**BREED**

Dachshund

**SEX**

Spayed Female

**AGE**

10 Years

**WEIGHT**

10 Pounds

**INTERPRETED BY**

Eric Lindquist, DMV  
DABVP, Cert. IVUSS

**IMAGING PERFORMED BY**

Kelly Vazquez

**HOSPITAL NAME**

Marsh AH

**REFERRING VET**

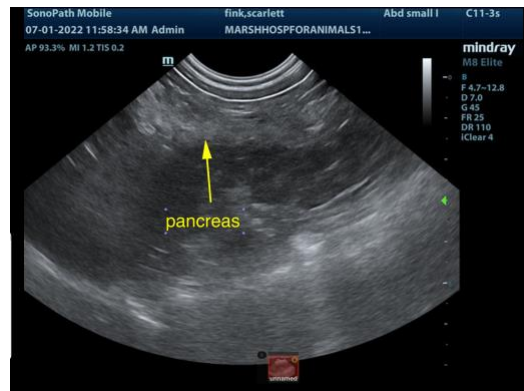
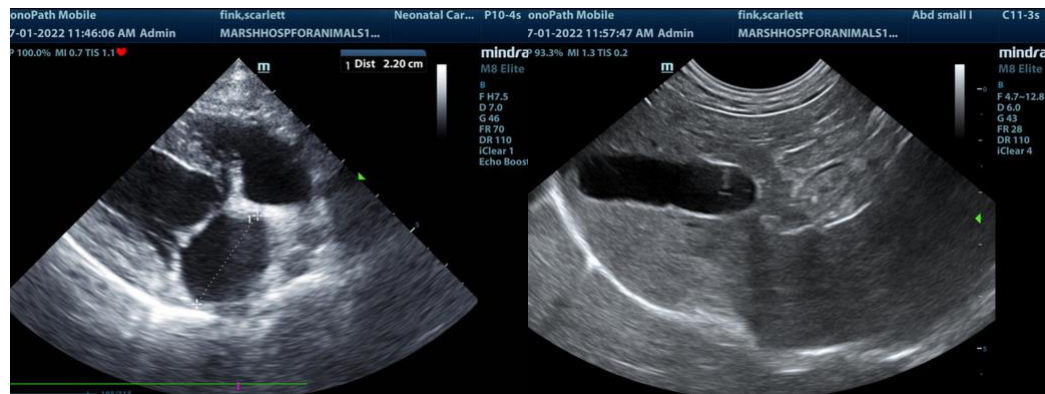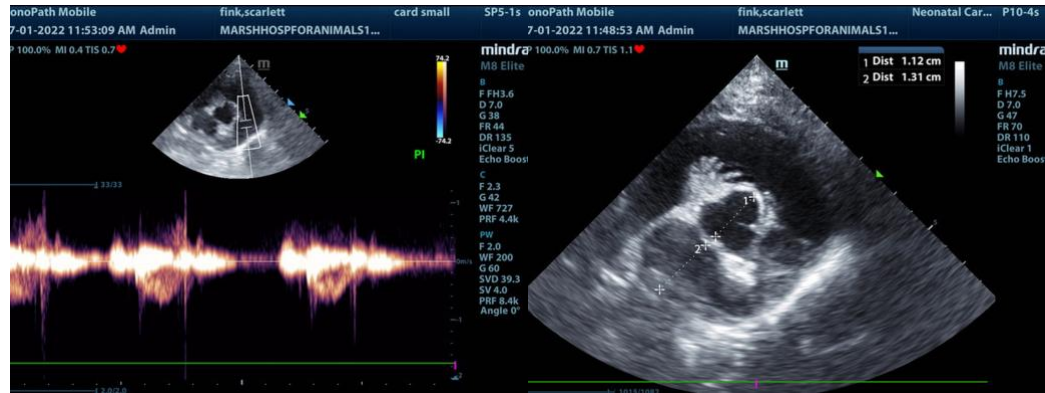
Dr. Milwicki

**INVOICE**

16433

**DATE**

7/1/22



The information and recommendations provided are based on the images presented by the referring veterinarian. No evaluation can be communicated regarding pathology that was not visible in the image/video clips provided.

Thank you for this referral. If the clinical or image interpretation does not parallel your findings or if I can be of any further assistance please contact me.

**Eric Lindquist**, DMV, DABVP, Cert. IVUSS, CEO of SonoPath.com  
info@SonoPath.com