

**DATE**

7/1/22

PRESENTING CLINICAL SIGNS**PATIENT**

Millie Bertling

History: Millie has ckd. For the past 4 years, she has had on and off urinary issues with stranguria, pollakiuria, hematuria. These seem to be cystitis episodes and will usually resolve with gabapentin and prazosin but since the end of April, she has had ongoing issues. U/A using kit4cat showed a pyuria with marked amounts of rods, also 3+ protein. Owner did not want to have cystocentesis done to get urine culture so did try on amoxicillin and it did not help. She has improved a little but has not resolved. Looking to assess for any evidence of pyelonephritis/uroliths/neoplasia that would potentially be a cause of these symptoms. Would also like to get a cystocentesis to obtain urine for a culture. Her last day of amoxicillin was 6/14.

SPECIES

Feline

Current Medications: gabapentin 50mg bid; phenoxybenzamine 5mg sid

BREED

DSH

Lab Results: See attached.

Date of Previous IntraPet Ultrasound: 5/1/2018. See attached.

Sedation: IV Torbugesic/PO Gabapentin.

Stat Report: Not requested.

SEX

Imaging Performed By: Stephanie Pearce RDCS, RVT.

Spayed Female

LIMITED ULTRASONOGRAPHIC EXAMINATION**AGE**

1/1/11

The **urinary bladder** presented concentric thickening, measuring up to 1.0 cm. No appreciable urine present at the time of the sonogram. It appears that some calculi were present in the bladder, yet contrast was minimal owing to lack of urine. Pericapsular inflammation was noted and trace amounts of free fluid.

WEIGHT

13 Pounds

The **kidneys** revealed normal size and structure, corticomedullary definition and ratio for this age. The cortices presented largely uniform texture with normal echogenic relationship to liver and spleen. Medullary structure differed distinctly from the cortex. The capsules were acceptably uniform without significant irregularities. Pyelectasia of the left kidney was persistent, measuring 0.5 cm, similar to the prior sonogram. The right kidney measured 3.88 cm. The left kidney measured 4.19 cm.

INTERPRETED BYEric Lindquist, DMV
DABVP, Cert. IVUSS**ULTRASONOGRAPHIC FINDINGS**

- Concentric bladder thickening with bladder sand and small calculi with regional inflammation
- Age-related renal changes with persistent left renal pyelectasia

HOSPITAL NAMECat Sense Feline
Hospital**INTERPRETATION OF THE FINDINGS & FURTHER RECOMMENDATIONS****REFERRING VET**

Dr. Sinclair

Given the pyuria, embedded bacteria within the bladder wall, bladder sand and renal pelvises, the likely sources of recurrence and persistence of infection, there is a potential for underlying bladder neoplasia in this patient. I recommend cystotomy, bladder wall biopsy, culture, sand analysis and culture. Intravenous antibiotics with IV fluid support may prove fruitful in this patient in order to treat embedded infection, followed by 4-6 weeks on antibiotics specifically based on culture results. The bladder is significantly worsened compared to the prior sonogram on 5/1/18.

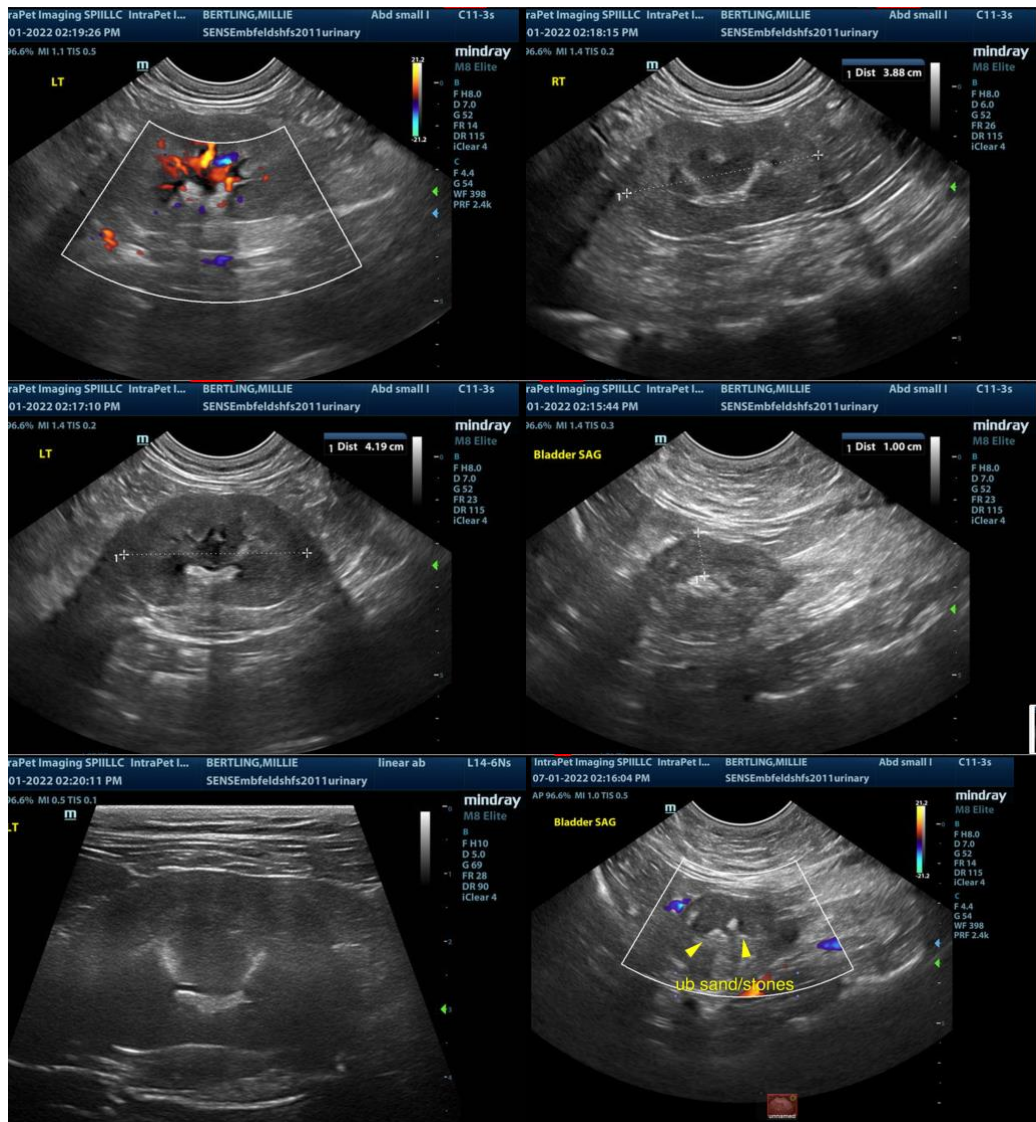
INVOICE

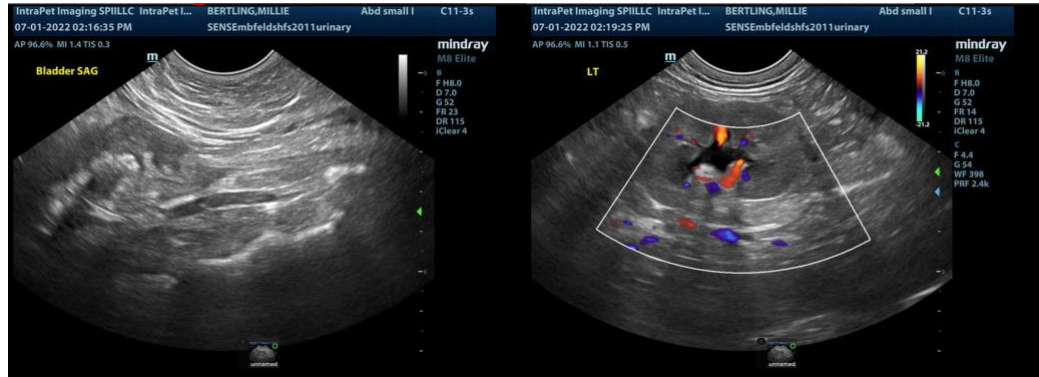
16440

Chronic UTI Protocol

I recommend **Enrofloxacin** (5-10 mg/kg SID PO) (In patients > 1 year of age) in late pm after urination to maximize urinary concentrations overnight. This assumes that culture supports this use. Repeat **culture** at 3-4 weeks and continue treatment at least 7-10 days post negative urinary sediment and negative culture.

Note: Negative culture does not necessarily mean lack of UTI. Other favorite antibiotics for chronic UTI include third generation Cefa (Ceftiafur or similar s.i.d. injectable) or Clavamox. If suspicion of occult urinary incontinence is present then **phenylpropanolamine (PPA)** (1-2 mg/kg BID) can be employed long term to enhance urethral tone.





The information and recommendations provided are based on the images presented by the referring veterinarian. No evaluation can be communicated regarding pathology that was not visible in the image/video clips provided.

Thank you for this referral. If the clinical or image interpretation does not parallel your findings or if I can be of any further assistance please contact me.

Eric Lindquist, DMV, DABVP, Cert. IVUSS, CEO of SonoPath.com
Eric.Lindquist@SonoPath.com