



PATIENT

Furiosa Smith

SPECIES

Feline

BREED

Domestic Shorthair

SEX

Spayed Female

AGE

2 years

WEIGHT

3.7 kg

INTERPRETED BY

Eric Lindquist, DMV
DABVP, Cert. IVUSS

IMAGING PERFORMED BY

Erin Wicks

HOSPITAL NAME

Shores VEC

REFERRING VET

Dr. Lupole

INVOICE

31404

DATE

7/1/22

PRESENTING CLINICAL SIGNS

Presented originally at our hospital 6/15/22 for NE for 48hr, crouching when walking, hiding, seems tender in kidney area. Previous Health Concerns: intermittent inappetence for 24 hrs at a time since 6mo old Had AUS with SonoPath and then transferred to VRC, they completed a second AUS and went in surgically. Rec AUS 2 weeks post op. SEE ATTACHED RECORDS FROM SPECIALIST.
Abnormal PE/Chem/CBC/UA Results: 6/15/22 Blood work – Glu 177, Tbili 0.6, Alb 3.6, HCT 52; Radiographs – R mid-abd poor detail, no signs of FB or obstruction, sl decreased detail mid abd; fast scan – very difficult to find R kidney, fluid filled structure in area of kidney, painful during scan See attached AUS from prev scan, AUS from VRC, SX report from VRC and culture.

ULTRASONOGRAPHIC EXAMINATION OF THE ABDOMEN

Urinary System

The **urinary bladder**, trigone, and pelvic urethra presented normal thicknesses and normal tone. The pelvic urethra was imaged 2.0 cm beyond the cystourethral junction. The ureters were not visible which is normal. No uroliths or sediment were visualized and anechoic urine was present. No evidence of inflammatory or neoplastic changes was noted. Ureteral papillae were normal.

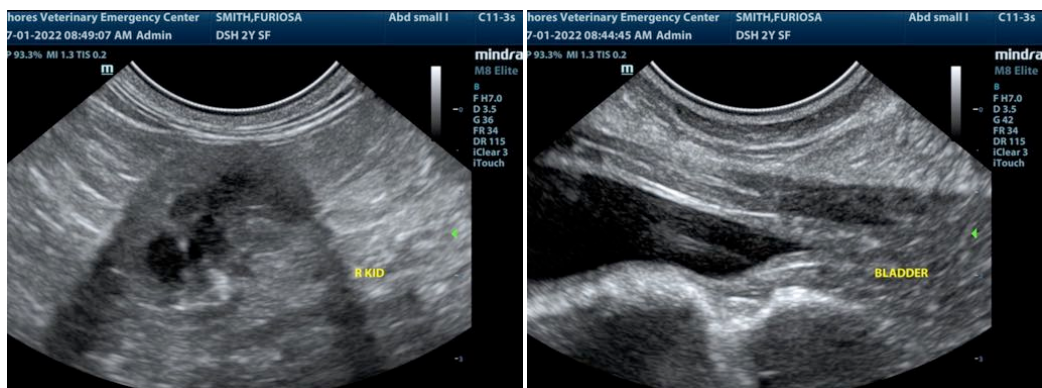
The right **kidney** was irregular in contour with disrupted corticomedullary definition and slight irregular pelvis. The right kidney revealed pyelectasia, minor cortical infarcts and slight pericapsular inflammatory pattern. The left kidney revealed moderate degenerative changes. The right kidney measured 2.86 cm. The left kidney measured 3.76 cm.

ULTRASONOGRAPHIC FINDINGS

Chronic nephrosis.

INTERPRETATION OF THE FINDINGS & FURTHER RECOMMENDATIONS

Palpation of the right kidney to assess for discomfort is indicated.





PATIENT

Furiosa Smith

SPECIES

Feline

BREED

Domestic Shorthair

SEX

Spayed Female

AGE

2 years

WEIGHT

3.7 kg

INTERPRETED BY

Eric Lindquist, DMV
DABVP, Cert. IVUSS

IMAGING PERFORMED BY

Erin Wicks

HOSPITAL NAME

Shores VEC

REFERRING VET

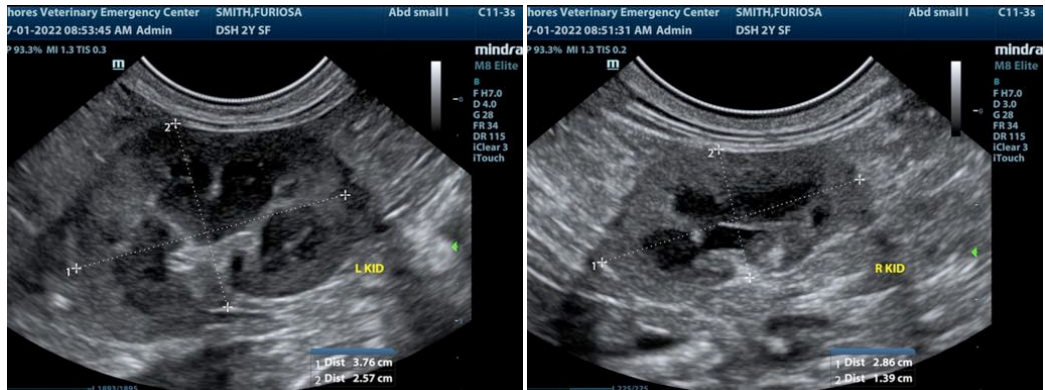
Dr. Lupole

INVOICE

31404

DATE

7/1/22



The information and recommendations provided are based on the images presented by the referring veterinarian/sonographer. No evaluation can be communicated regarding pathology that was not visible in the image/video clips provided.

Thank you for this referral. If the clinical or image interpretation does not parallel your findings or if I can be of any further assistance please contact me.

Eric Lindquist, DMV, DABVP, Cert. IVUSS, CEO of SonoPath.com
info@SonoPath.com