



PATIENT

Bear Webster

SPECIES

Canine

BREED

GSD X

SEX

Neutered Male

AGE

7 Years

WEIGHT

34.8 kg

INTERPRETED BY

Eric Lindquist, DMV

DABVP, Cert. IVUSS

IMAGING PERFORMED BY

Erin Wicks

HOSPITAL NAME

Shores VEC

REFERRING VET

Dr. Lupole

INVOICE

39168

DATE

7/1/22

PRESENTING CLINICAL SIGNS

Presented at our hospital for reduced appetite since Sunday. O states that P has not been vomiting or having diarrhea. O states that P has been in appetent since this AM. O states that P has been lethargic since Sunday. O states that P has been coughing since Sunday. No abdominal distension that O is aware of. Previous Health Concerns: GI issues Current Medications: Cerenia 60mg 2 tabs q24 Appetite/When did they eat last: reduced, ate this AM

Abnormal PE/Chem/CBC/UA Results: Epoc: nr Cortisol: nr Rads: prominent rugae; sl bunching of bowel in right upper quadrant and lower left quadrant

ULTRASONOGRAPHIC EXAMINATION OF THE ABDOMEN

Urinary System

The **urinary bladder**, trigone, and pelvic urethra presented normal thicknesses and normal tone. The ureters were not visible which is normal. No uroliths or sediment were visualized and anechoic urine was present. No evidence of inflammatory or neoplastic changes were noted. Ureteral papillae were normal. The pelvic urethra was imaged 2.0 cm beyond the cystourethral junction.

The **kidneys** revealed normal size and structure, corticomedullary definition and ratio for this age. The cortices presented largely uniform texture with normal echogenic relationship to liver and spleen. Medullary structure differed distinctly from the cortex and no evidence of pelvic dilation was present. The capsules were acceptably uniform without significant irregularities. The left kidney measured 7.6 cm. The right kidney measured 7.2 cm.

Adrenal Glands

Both **adrenal glands** were visualized and recognized as having normal shape, size, position and echogenicity for this breed. The phrenic vasculature, glandular echogenicity and detail were unremarkable. Capsule, cortex, and medullary definition were normal for this age patient. The left adrenal gland measured 2.54 cm x 0.61 cm at the cranial pole and 0.70 cm at the caudal pole.

Spleen

The **spleen** presented a smooth homogeneous parenchyma hyperechoic to liver and renal cortical parenchyma. The spleen was folded upon itself caudally. The capsule was smooth without noticeable expansion or deviation from within the spleen or adjacent pathology. The splenic vasculature demonstrated normal volume without signs of congestion or thrombosis. No sonographic evidence of acute or chronic inflammatory, neoplastic, or infarctual changes were noted.

Liver

The **liver** images submitted revealed subjectively normal liver size, contour, and structure. Parenchymal echogenicity was naturally coarse and hypoechoic to the spleen. Vascular and biliary tracts were of normal volume with no evidence of congestion. The gallbladder presented acceptably thin walls with primarily anechoic content. The cystic and common bile ducts were normal. No pathological hepatic lymphadenopathy was evident. No overt structural evidence of inflammatory, infiltrative or regenerative pathology was evident.

Gastrointestinal

The pylorus revealed soft shadowing material measuring approximately 2.0 cm. This may represent retention of ingesta and appears to be non-obstructive. The small intestine and colon were unremarkable.

Pancreas



PATIENT

Bear Webster

The base and limbs of the **pancreas** were observed to be largely isoechoic to surrounding omental fat. Pancreatic duct and capsular contour were acceptably normal and parenchyma respected normal curvilinear patterns. No overt evidence of active inflammatory or neoplastic disease was noted.

SPECIES

Canine

PRIMARY FINDINGS

- Minor retention of ingesta (slightly shadowing) in the pyloric outflow, non-obstructive.

INTERPRETATION OF THE FINDINGS & FURTHER RECOMMENDATIONS

Other causes of anorexia should be considered, depending upon the feeding history. Pain related anorexia, CNS and thoracic disease should be considered.

BREED

GSD X

SEX

Neutered Male

AGE

7 Years

WEIGHT

34.8 kg

INTERPRETED BY

Eric Lindquist, DMV
DABVP, Cert. IVUSS

IMAGING PERFORMED BY

Erin Wicks

HOSPITAL NAME

Shores VEC

REFERRING VET

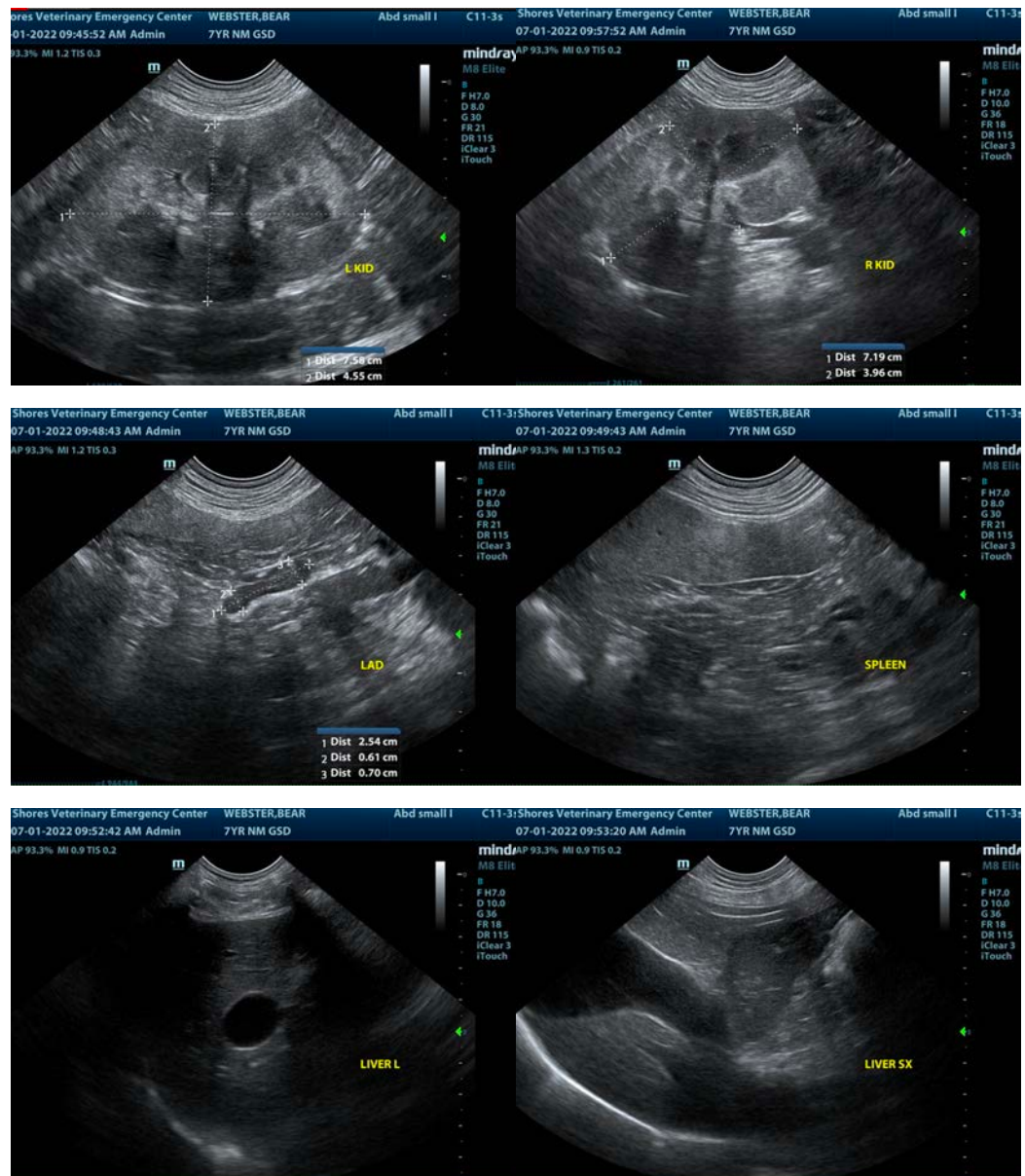
Dr. Lupole

INVOICE

39168

DATE

7/1/22





PATIENT

Bear Webster

SPECIES

Canine

BREED

GSD X

SEX

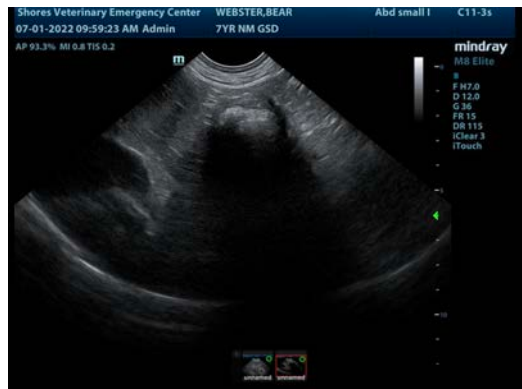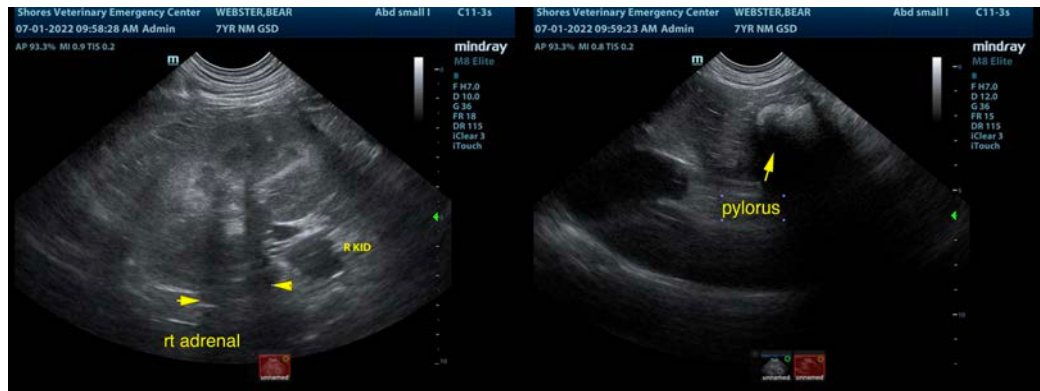Neutered Male

AGE

7 Years

WEIGHT

34.8 kg



INTERPRETED BY

Eric Lindquist, DMV

DABVP, Cert. IVUSS

IMAGING PERFORMED BY

Erin Wicks

HOSPITAL NAME

Shores VEC

REFERRING VET

Dr. Lupole

INVOICE

39168

DATE

7/1/22

The information and recommendations provided are based on the images presented by the referring veterinarian/sonographer. No evaluation can be communicated regarding pathology that was not visible in the image/video clips provided.

Thank you for this referral. If the clinical or image interpretation does not parallel your findings or if I can be of any further assistance please contact me.

Eric Lindquist, DMV, DABVP, Cert. IVUSS, CEO of SonoPath.com

info@SonoPath.com