



PATIENT PRESENTING CLINICAL SIGNS

Macie Attanasio acute onset bloat, fever

SPECIES ULTRASONOGRAPHIC EXAMINATION OF THE ABDOMEN

Canine **Urinary System**

BREED

Dachshund

The **urinary bladder**, trigone, and pelvic urethra presented normal thicknesses and normal tone. The ureters were not visible which is normal. No uroliths or sediment were visualized and anechoic urine was present. No evidence of inflammatory or neoplastic changes were noted. Ureteral papillae were normal.

SEX

Spayed Female

The **kidneys** revealed normal size and structure, corticomedullary definition and ratio for this age. The cortices presented largely uniform texture with normal echogenic relationship to liver and spleen. Medullary structure differed distinctly from the cortex and no evidence of pelvic dilation was present. The capsules were acceptably uniform without significant irregularities. The right kidney measured 5.53 cm. The left kidney measured 5.14 cm.

AGE

3 Years

Adrenal Glands

WEIGHT

24 Pounds

Both **adrenal glands** were visualized and recognized as having normal shape, size, position and echogenicity for this breed. The phrenic vasculature, glandular echogenicity and detail were unremarkable. Capsule, cortex, and medullary definition were normal for this age patient. The left adrenal gland measured 1.68 cm x 0.36 cm at the caudal pole and 0.49 cm at the cranial pole. The right adrenal gland measured 2.26 cm x 0.47 cm at the caudal pole and 0.88 cm at the cranial pole.

Spleen

INTERPRETED BY

Eric Lindquist, DMV

The **spleen** presented a smooth homogeneous parenchyma hyperechoic to liver and renal cortical parenchyma. The capsule was smooth without noticeable expansion or deviation from within the spleen or adjacent pathology. The splenic vasculature demonstrated normal volume without signs of congestion or thrombosis. No sonographic evidence of acute or chronic inflammatory, neoplastic, or infarctual changes were noted.

DABVP, Cert. IVUSS

IMAGING PERFORMED BY

Jenn

Liver

HOSPITAL NAME

Rockaway AH

The **liver** images submitted revealed subjectively normal liver size, contour, and structure. Parenchymal echogenicity was naturally coarse and hypoechoic to the spleen. Vascular and biliary tracts were of normal volume with no evidence of congestion. The gallbladder presented acceptably thin walls with primarily anechoic content. The cystic and common bile ducts were normal. No pathological hepatic lymphadenopathy was evident. No overt structural evidence of inflammatory, infiltrative or regenerative pathology was evident.

REFERRING VET

Dr. Maniar

Gastrointestinal

INVOICE

38542

The **stomach** was filled with soft shadowing luminal material. Post-prandial presentation likely. No overt obstruction. However, delayed outflow likely. The small intestine and colon were unremarkable. Transit of chyme appeared normal.

DATE

6/9/22

Pancreas

The base and limbs of the **pancreas** were observed to be largely isoechoic to surrounding omental fat. Pancreatic duct and capsular contour were acceptably normal and parenchyma respected normal curvilinear patterns. No overt evidence of active inflammatory or neoplastic disease was noted.



PATIENT

Macie Attanasio

ULTRASONOGRAPHIC FINDINGS

- Full stomach – likely excessive prandial intake or delayed outflow depending on when the patient ate prior to the sonogram.

SPECIES

Canine

INTERPRETATION OF THE FINDINGS & FURTHER RECOMMENDATIONS

Recommend conservative therapy with 12-18 hour NPO and recheck sonogram to assess if the material is persistently present. This likely represents ingesta. However, grass, stuffing or similar material are all possible.

BREED

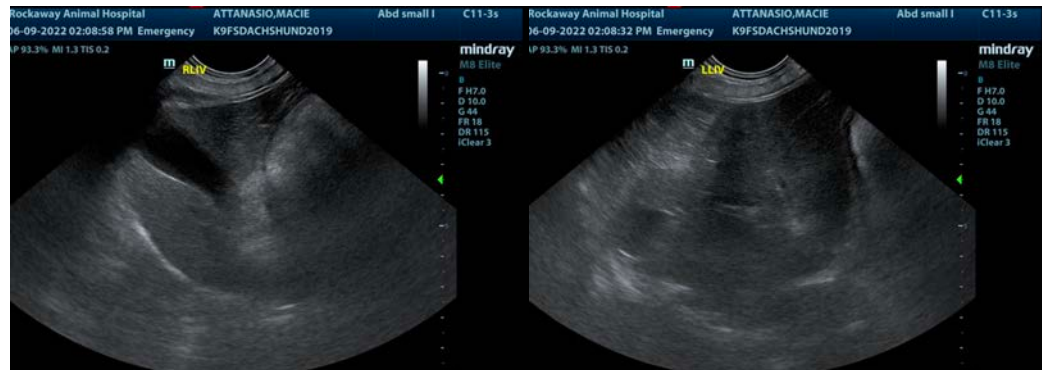
Dachshund

SEX

Spayed Female

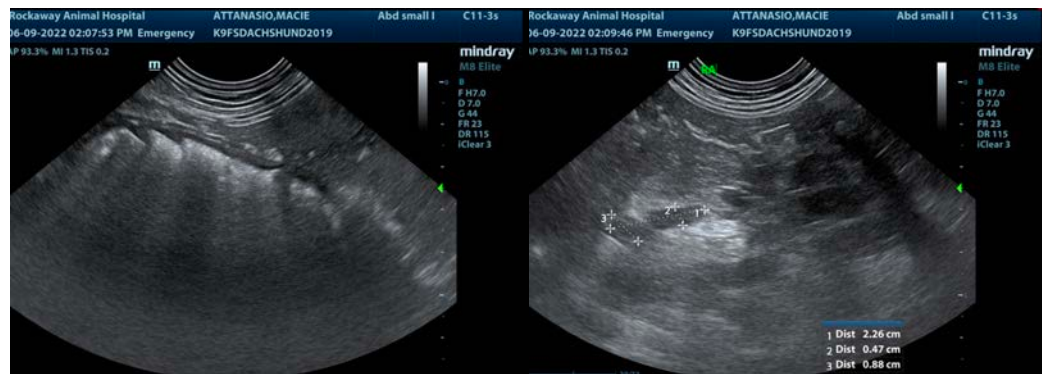
AGE

3 Years



WEIGHT

24 Pounds



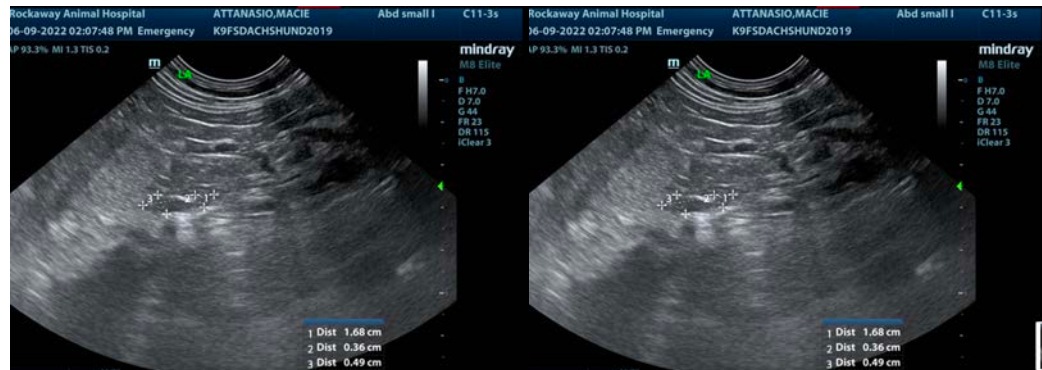
INTERPRETED BY

Eric Lindquist, DMV

DABVP, Cert. IVUSS

IMAGING PERFORMED BY

Jenn



HOSPITAL NAME

Rockway AH

REFERRING VET

Dr. Maniar

INVOICE

38542

DATE

6/9/22



PATIENT

Macie Attanasio

SPECIES

Canine

BREED

Dachshund

SEX

Spayed Female

AGE

3 Years

WEIGHT

24 Pounds

INTERPRETED BY

Eric Lindquist, DMV

DABVP, Cert. IVUSS

IMAGING PERFORMED BY

Jenn

HOSPITAL NAME

Rockaway AH

REFERRING VET

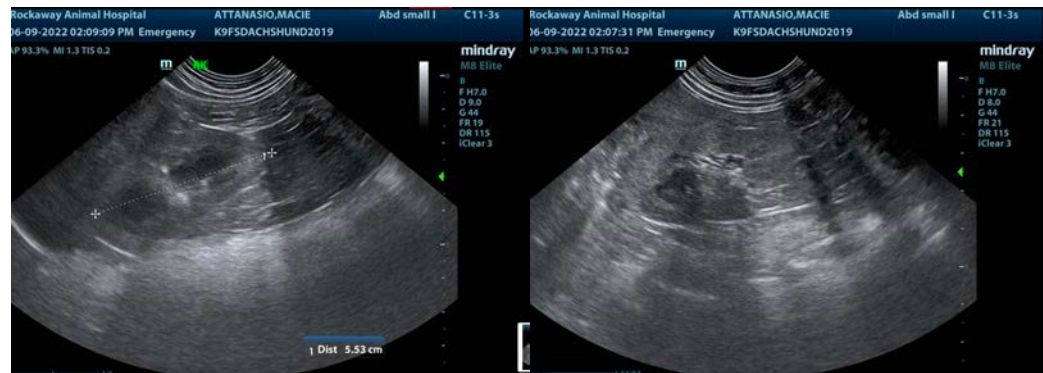
Dr. Maniar

INVOICE

38542

DATE

6/9/22



The information and recommendations provided are based on the images presented by the referring veterinarian/sonographer. No evaluation can be communicated regarding pathology that was not visible in the image/video clips provided.

Thank you for this referral. If the clinical or image interpretation does not parallel your findings or if I can be of any further assistance please contact me.

Eric Lindquist, DMV, DABVP, Cert. IVUSS, CEO of SonoPath.com

info@SonoPath.com