



PATIENT

Jack Sansone

PRESENTING CLINICAL SIGNS

History: FIV POSITIVE WEIGHT LOSS Cutaneous Eosinophilic Diseases ON THE PAWS
Abnormal PE/Chem/CBC/UA Results: CHEMISTRY- LOW CREATININE ALBUMIN /GLOBULIN-0.5
FIV POSITIVE

SPECIES

Feline

ULTRASONOGRAPHIC EXAMINATION OF THE ABDOMEN

Urinary System

The **urinary bladder**, trigone, and pelvic urethra presented normal thicknesses and normal tone. The ureters were not visible which is normal. No uroliths or sediment were visualized and anechoic urine was present. No evidence of inflammatory or neoplastic changes was noted. Ureteral papillae were normal.

BREED

Domestic Shorthair

SEX

Neutered male

The left **kidney** was severely enlarged with subcapsular halo and pericapsular inflammatory pattern on the left kidney. Regional inflammation was noted. The right kidney was mildly enlarged, yet structure was conserved. The right kidney measured 4.0 cm with minor loss of corticomedullary definition.

AGE

1 years

Adrenal Glands

Both **adrenal glands** were visualized and recognized as having normal shape, size, position and echogenicity for this breed. The phrenic vasculature, glandular echogenicity and detail were unremarkable. Capsule, cortex, and medullary definition were normal for this age patient.

WEIGHT

5.3 lbs

INTERPRETED BY

Eric Lindquist, DMV
DABVP, Cert. IVUSS

Spleen

The **spleen** presented a smooth homogeneous parenchyma hyperechoic to liver and renal cortical parenchyma. The capsule was smooth without noticeable expansion or deviation from within the spleen or adjacent pathology. The splenic vasculature demonstrated normal volume without signs of congestion or thrombosis. No sonographic evidence of acute or chronic inflammatory, neoplastic, or infarctual changes was noted. The spleen measured 0.8 cm.

IMAGING PERFORMED BY

Dr. Sharkaway

HOSPITAL NAME

Kew Gardens AH

Liver

The **liver** revealed mild coarse architecture and slightly increased portal markings. A minor amount of gallbladder debris was noted.

REFERRING VET

Dr. Sharkaway

Gastrointestinal

INVOICE

30954

A minor amount of non-shadowing, non-obstructive ingesta was noted in the **stomach**. Transit of chyme into the small intestine was normal. A small intestinal mass was also noted and measured approximately 6.0 cm. Regional inflammation was noted. Other areas of small intestinal thickening were present. Regional lymphadenopathy was noted.

DATE

6/9/22



PATIENT

Pancreas

Jack Sansone

The base and limbs of the **pancreas** were observed to be largely isoechoic to surrounding omental fat. Pancreatic duct and capsular contour were acceptably normal and parenchyma respected normal curvilinear patterns. No overt evidence of active inflammatory or neoplastic disease was noted.

SPECIES

Feline

ULTRASONOGRAPHIC FINDINGS

BREED

Intestinal and renal lymphoma patterns.

Domestic Shorthair

INTERPRETATION OF THE FINDINGS & FURTHER RECOMMENDATIONS

SEX

FNA of the left kidney and intestinal mass is recommended.

Neutered male

AGE

1 years

WEIGHT

5.3 lbs

INTERPRETED BY

Eric Lindquist, DMV
DABVP, Cert. IVUSS

IMAGING PERFORMED BY

Dr. Sharkaway

HOSPITAL NAME

Kew Gardens AH

REFERRING VET

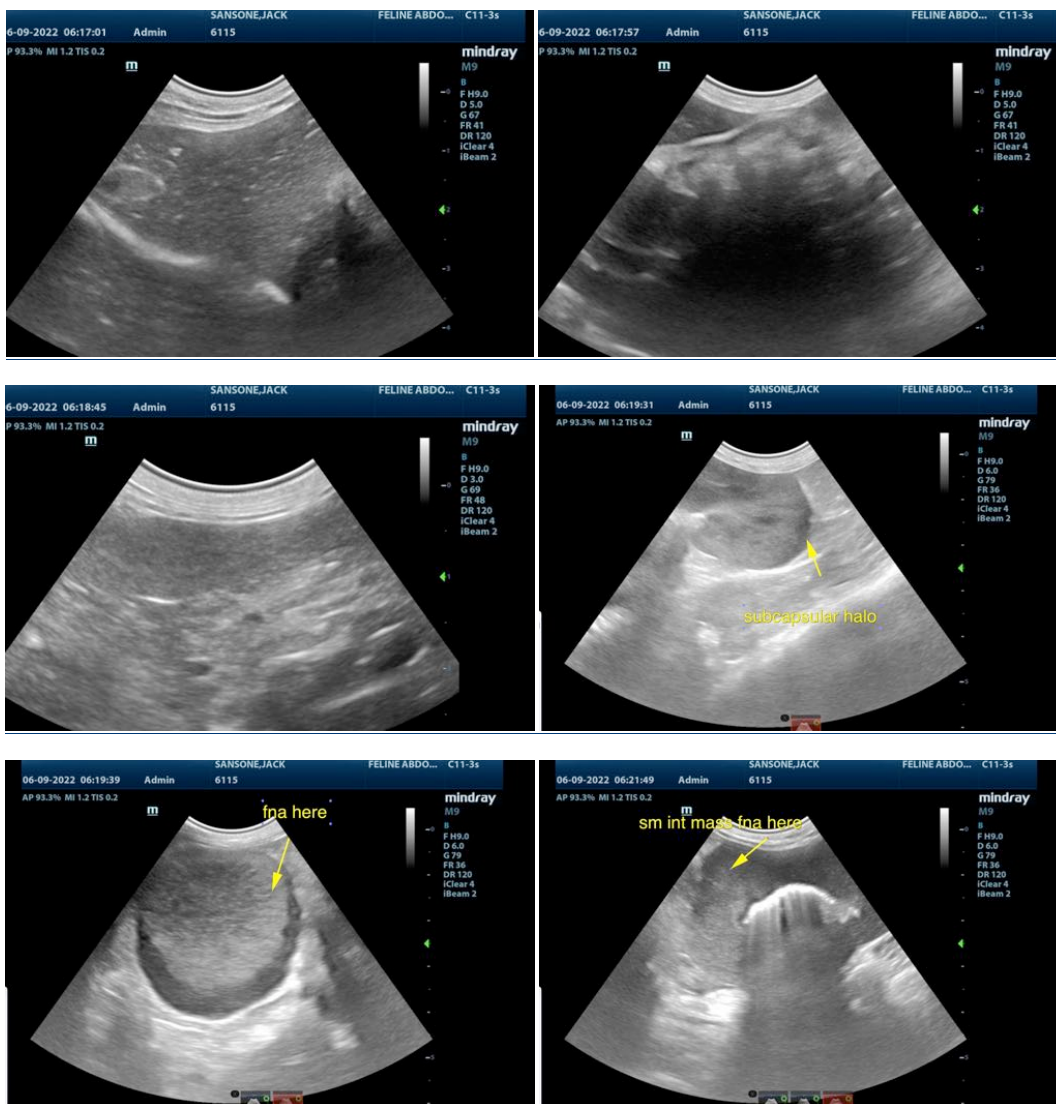
Dr. Sharkaway

INVOICE

30954

DATE

6/9/22





PATIENT

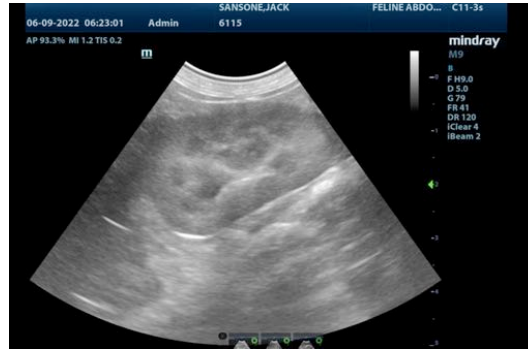Jack Sansone

SPECIES

Feline

BREED

Domestic Shorthair



SEX

Neutered male

The information and recommendations provided are based on the images presented by the referring veterinarian/sonographer. No evaluation can be communicated regarding pathology that was not visible in the image/video clips provided.

AGE


1 years

Thank you for this referral. If the clinical or image interpretation does not parallel your findings or if I can be of any further assistance please contact me.

Eric Lindquist, DMV, DABVP, Cert. IVUSS, CEO of SonoPath.com
info@SonoPath.com

WEIGHT

5.3 lbs



The following is an applicable excerpt from the *Curbside Guide to Diagnosis & Treatment of Sonographic Disease* offered by SonoPath.com Lindquist, Frank, and Modler.

INTERPRETED BY

Eric Lindquist, DMV
DABVP, Cert. IVUSS

An essential quick guide for every general practitioner and sonographer.

IMAGING PERFORMED BY

Dr. Sharkaway

<https://sonopath.com/products/curbside-guide-editing-due-release-12012015>

HOSPITAL NAME

Kew Gardens AH

Feline Lymphoma and Intestinal Neoplasia

REFERRING VET

Dr. Sharkaway

<http://www.sonopath.com/FelineGILSA>

<http://www.sonopath.com/FelineGICarcinoma>

INVOICE

30954

DATE

6/9/22



PATIENT

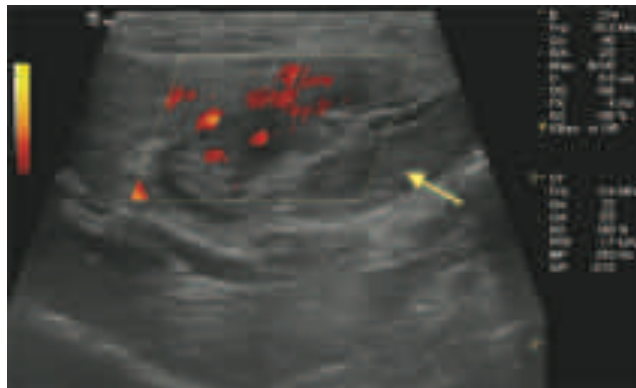
Jack Sansone

SPECIES

Feline

BREED

Domestic Shorthair



Short axis of the stomach in a cat with gastric lymphosarcoma. There is generalized circumfer wall thickening with transmural loss of wall lay (arrow). The power Doppler demonstrates severe hypervascularity within the gastric wall.

SEX

Neutered male

AGE

1 years

WEIGHT

5.3 lbs

Description: The gastrointestinal (GI) tract is a common site for lymphoma in cats. In addition to the GI form, the most prevalent feline lymphomas are leukemic and mediastinal. Multicentric lymphoma occurs less frequently in cats than in dogs. Researchers have documented an association between FeLV and the development of lymphoma in cats; the incidence registers somewhere between 12-80%, depending on the location of the lymphoma. Typically, the leukemic and mediastinal forms tend to occur in young cats with concurrent FeLV positive titers, while GI lymphoma occurs more frequently in older patients that present as FeLV negative. Yet, recent studies using PCR have demonstrated that the incidence of FeLV positivity in cases of GI lymphoma can be as high as 63%, putting into question previously held beliefs about the etiological patterns of the disease.

INTERPRETED BY

Eric Lindquist, DMV
DABVP, Cert. IVUS

IMAGING PERFORMED BY

Dr. Sharkaway

HOSPITAL NAME

Kew Gardens AH

Feline lymphoma in younger cats is typically of the intermediate to large cell variety. Older cats usually display small cell lymphoma, which is often difficult to differentiate from lymphocytic inflammatory disease or hyperplasia. B cell lymphoma often derives from the gut-associated lymphoid tissue (GALT) and is the most common type of alimentary lymphoma in cats. Renal lymphoma is typically the large cell type and nearly always occurs bilaterally. It may be confirmed by dual renal ultrasound-guided FNA, and is often localized in the kidneys. Renal lymphoma may be associated with the alimentary form and/or nasal lymphoma. Hepatic lymphoma is also usually the large cell form and is the most common type of feline liver tumor; it is especially prevalent in older cats. Mediastinal lymphoma originates in the thymus and is found mostly in younger FeLV-positive cats.

REFERRING VET

Dr. Sharkaway

INVOICE

30954

DATE

6/9/22

Clinical Signs: Older, domestic shorthair cats tend to be those most commonly affected by GI lymphoma. Nondescript symptoms include weight loss, diarrhea, vomiting, and anorexia; lethargy may or may not be present. Bloodwork can often be unremarkable; however, hypoalbuminemia is the most prevalent finding (present in 50% of cases). A palpable abdominal mass is present in approximately one third of cases, while another third typically presents with thickened bowel loops. A modified transudate or chylous effusion ascites may develop due to lymphatic obstruction. If the lymphoma metastasizes from the thoracic duct into the thorax, then a similar effusion may occur within the thoracic cavity; the resultant respiratory signs and pleural effusion will be evident on radiographs. Over half of the cases present clinically with normal abdominal palpation. Radiographs are also often of little diagnostic relevance for this disease until a visible mass or obstructive pattern develops.



PATIENT

Jack Sansone

SPECIES

Feline

BREED

Domestic Shorthair

SEX

Neutered male

AGE

1 years

WEIGHT

5.3 lbs

Diagnostics: Ultrasound diagnostics make early detection quite reliable, and the reliability increases when the GI tract has been properly prepared (this requires the patient to have fasted for 12 hours prior to the ultrasound). Fine needle aspirates or guided biopsies may be obtained in order to stage and differentiate this disease from chronic inflammatory disorders (i.e., inflammatory bowel disease [IBD]) or other neoplasia (i.e., adenocarcinoma, mast cell tumor). Endoscopy is also quite dependable; however, vague changes may or may not be noted in the mucosa. These lesions include irregular mucosae, pallor, friability, erosions, and ulcers. Occasionally, a discrete mass may be seen, but usually a mucosal biopsy is necessary for differentiation.

There are different grades of GI lymphoma: i) low grade alimentary lymphoma (LGAL); ii) poorly differentiated (lymphoblastic or high grade alimentary lymphoma [HGAL]); and iii) intermediate grade alimentary lymphoma (IGAL). Tumor locations tend to differ according to the grade of lymphoma present. Ninety percent of lymphocytic lymphoma involves the small intestine only, while the remaining cases involve the small intestine as well as gastric tissue. Lymphoblastic lymphoma cases that affect the small intestine exclusively occur 50% of the time, while one-third of cases involves the stomach exclusively; the remaining cases affect both organs. In one study of 67 cases, 75% were defined as lymphocytic and 25% as lymphoblastic upon histological examination. In fact, cytological diagnoses are achieved more frequently when assessing HGAL and IGAL; however, histology is often required to diagnose LGAL. Palpable abdominal masses are noted much more frequently in cases of HGAL and IGAL than in those of LGAL. Ultrasonography may show GI mural masses, diminished wall layering, or wall thickening. Anemia is more characteristic of HGAL and IGAL than LGAL.

INTERPRETED BY

Eric Lindquist, DMV
DABVP, Cert. IVUSS

IMAGING PERFORMED BY

Dr. Sharkaway

HOSPITAL NAME

Kew Gardens AH

REFERRING VET

Dr. Sharkaway

INVOICE

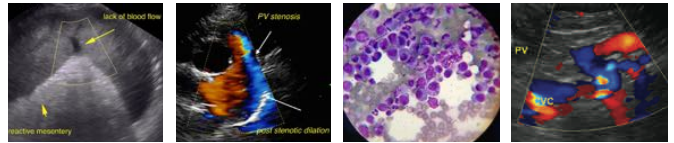
30954

DATE

6/9/22

Ultrasound-guided sampling is readily obtainable on most suspected organs (e.g. liver, spleen, kidney, pancreas, lymph nodes) and masses, but surgery may be indicated when a patient presents with diffusely thickened bowels and one must differentiate IBD from intestinal LSA. Although fine needle aspiration (FNA) is usually adequate for obtaining a cytological diagnosis, it can sometimes present a challenge when one is distinguishing between small cell lymphoma and hyperplasia; however, special staining, such as PARR, or the use of PCR can help clarify the difference. These tests also help differentiate monoclonal from polyclonal lymphoma, which can help practitioners refine their therapeutic protocols and prognoses. In cases where these tests do not provide sufficient information, core or surgical biopsy is necessary for differentiation.

The crypt of Lieberkühn (intestinal gland) is also vulnerable to adenocarcinoma, which accounts for 25-30% of all GI neoplasms. Luminal stricture occurs in approximately 25% of those affected. It typically affects cats between the ages of 8 and 11; the Siamese breed represents 71% of all cases. Seventy percent of cases occur in the small intestine (primarily the duodenum) and the remainder in the colon. Metastatic spread via the lymphatic system to the mesenteric lymph nodes occurs 50% of the time and carcinomatosis occurs 29% of the time; the lungs and liver are often affected. Surgical resection and anastomosis are the treatments of choice for adenocarcinoma and should be followed by chemotherapy with doxorubicin every 3 weeks for a total of 5-6 treatments. Prognosis varies, depending upon the study. In one study, a 10-month median life span was observed if metastasis was present at diagnosis (range 0-28 months). Characterization of the adenocarcinoma will dictate the prognosis: those with the tubular form



PATIENT	have a longer median survival time (MST) of 11 months compared to patients with the undifferentiated and mucinous types (4 months).
Jack Sansone	
SPECIES	Ultrasound and endoscopy can offer early detection of GI lymphoma and help to differentiate it from other diseases with similarly vague signs (i.e., IBD, pancreatitis, hepatic lipidosis, triaditis, and other neoplasia). These techniques also allow one to determine if surgical intervention is necessary (i.e., as opposed to medical therapy for IBD or chemotherapy for diffuse lymphoma). For instance, cases of adenocarcinoma and lymphoblastic lymphoma tend to obstruct the intestinal lumen more readily than lymphocytic lymphoma and would therefore require surgical bowel resection. Definition and staging of the disease is facilitated noninvasively through biopsy procedures. These enable the practitioner to determine the course of treatment, ascertain a prognosis, and arrive at a rapid conclusion. Moreover, a sampling of the liver—the most frequent site of metastatic spread—may be performed simultaneously to assess further the extent of the pathology.
Feline	
BREED	
Domestic Shorthair	
SEX	
Neutered male	
AGE	Treatment: Small cell lymphocytic lymphoma is typically treated with oral chemotherapy, which includes administering prednisone (1-2 mg/kg PO Q24hr, then 1 mg/kg Q48hr) and chlorambucil (20mg/m ² PO Q14 days). Alternative protocols also exist: prednisone can be given at 10 mg/cat/day and chlorambucil at 15 mg/m ² once a day for 3 days and repeated at three-week intervals. Different studies have demonstrated the success of these protocols, which are well tolerated and have resulted in remission rates of 69% with an MST of 20.5 months (range 5.8-49 months). Rare adverse side effects to the chemotherapy include gastrointestinal signs, anorexia, and leukopenia. Remission is usually achieved within 3 weeks and may be assessed and quantified by ultrasound examination. In the case of recurrence, rescue chemotherapy can be implemented with cyclophosphamide.
1 years	
WEIGHT	
5.3 lbs	
INTERPRETED BY	
Eric Lindquist, DMV DABVP, Cert. IVUSS	
IMAGING PERFORMED BY	A more aggressive approach is recommended for cats with lymphoblastic lymphoma; it entails using combination chemotherapy, such as cyclophosphamide, vincristine, and prednisone, with or without doxorubicin. Yet, remission rates are much lower for patients with lymphoblastic lymphoma than those with small cell lymphoma. In one study, the MST was reported to be 2.7 months for lymphoblastic cases. The presence of abdominal masses is more common with lymphoblastic lymphoma, and patients with this type of cancer may therefore also require surgical resection. Consultation with an oncologist is strongly advised.
Dr. Sharkaway	
HOSPITAL NAME	
Kew Gardens AH	
REFERRING VET	
Dr. Sharkaway	
INVOICE	
30954	
DATE	
6/9/22	



PATIENT

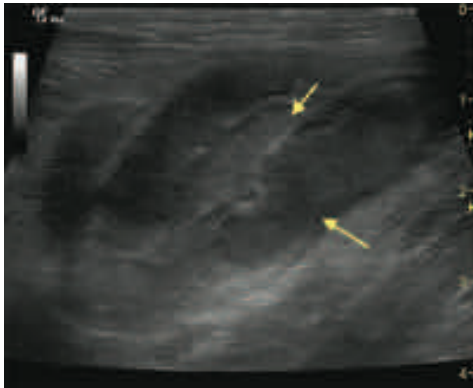
Jack Sansone

SPECIES

Feline

BREED

Domestic Shorthair



Long axis of the stomach in a cat with gastric lymphosarcoma. There is severe irregular centripetal wall thickening with partial loss of wall layering (large arrow) and a hypoechoic mass occupying the gastric fundus. The gastric lumen with minor amount of echogenic chyme is indicated by the small arrow.

SEX

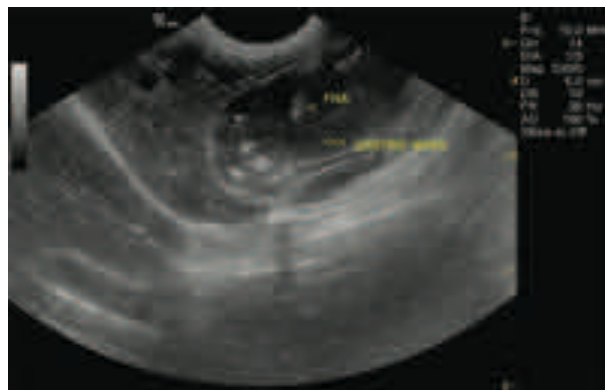Neutered male

AGE

1 years

WEIGHT

5.3 lbs



Short axis of the stomach of the same cat as in previous image during ultrasound guided fine needle aspiration of the gastric wall. The echogenic needle tip is seen within the hypoechoic luminal mass lesion. Note the hyperechoic area within the mass to the left of the needle tip consistent with air introduced during previous sampling of that region.

INTERPRETED BY

Eric Lindquist, DMV
DABVP, Cert. IVUS

IMAGING PERFORMED BY

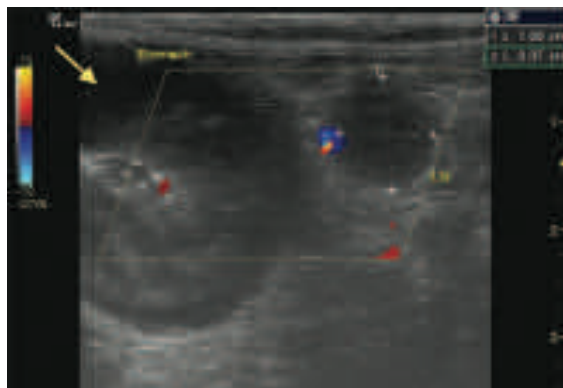
Dr. Sharkaway

HOSPITAL NAME

Kew Gardens AH

REFERRING VET

Dr. Sharkaway



Short axis of the stomach in a cat with gastric lymphosarcoma. The gastric lymph node (LN) shows enlargement, rounding, and disrupted length to width ratio, and decreased echogenicity compatible with lymphomatous infiltration. Note the circumferential thickening and loss of layering of the gastric wall (arrow).

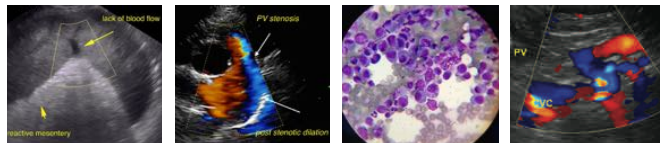
INVOICE

30954

DATE

6/9/22

References:



PATIENT

Jack Sansone

Barrs V, Beatty J. Feline alimentary **lymphoma**: 2. Further diagnostics, therapy and prognosis. *J Feline Med Surg* 2012;14(3):191-201.

SPECIES

Feline

Fondacaro J, Richter K, Carpenter J, et al. [Feline gastrointestinal lymphoma: 67 cases \(1988-1996\)](#). *Eur J Comp Gastroenterol* 1999;4(2):5-11.

BREED

Domestic Shorthair

Russel KJ, Beatty JA, Dhand N, et al. Feline low-grade alimentary lymphoma: how common is it? *J Feline Med Surg* 2012;14(12):910-12.

SEX

Neutered male

Stein TJ, Pellin M, Steinberg H, and Chun R. Treatment of feline gastrointestinal small-cell lymphoma with chlorambucil and glucocorticoids. *J Am Anim Hosp Assoc* 2010;46(6):413-17.

AGE

1 years

Twomey LN, Alleman AR. Cytological diagnosis of feline lymphoma. *Comp Cont Educ Pract Vet* 2005;27:17-31.

WEIGHT

5.3 lbs

Wilson H. Feline alimentary lymphoma: demystifying the enigma. *Top Companion Anim Med* 2008;23(4):177-84.

INTERPRETED BY

Eric Lindquist, DMV
DABVP, Cert. IVUSS

IMAGING PERFORMED BY

Dr. Sharkaway

HOSPITAL NAME

Kew Gardens AH

REFERRING VET

Dr. Sharkaway

INVOICE

30954

DATE

6/9/22