



**PATIENT**

Daphne Casper

**SPECIES**

Canine

**BREED**

Cocker Spaniel

**SEX**

Spayed Female

**AGE**

12 Years

**WEIGHT**

13.6 kg

**INTERPRETED BY**

Eric Lindquist, DMV

DABVP, Cert. IVUSS

**IMAGING PERFORMED BY**

Erin Wicks

**HOSPITAL NAME**

Shores VEC

**REFERRING VET**

Dr. Nelson

**INVOICE**

38544

**DATE**

6/9/22

**PRESENTING CLINICAL SIGNS**

Presented at our hospital for urinating blood since Monday. Had procedure done Wednesday at Cornell to flush the bladder per owner. Patient is having an increase in urination and it seems to be almost all blood and has a slimy consistency sometimes. In last 2 visits to Cornell patient also had a high blood pressure. Previous Health Concerns: heart murmur; high blood pressure; chronic bladder infection for 2 years; scar tissue in throat from debarking, 2nd degree A/V block Current Medications: incurin; meloxicam; Xanax Appetite/When did they eat last: normal ate today Abnormal PE/Chem/CBC/UA Results: BP: 241/127, 249/125 Hypertension

**ULTRASONOGRAPHIC EXAMINATION OF THE ABDOMEN**

**Urinary System**

The **urinary bladder** presented concentric wall thickening, sand accumulation and mucus debris. Minimal amount of urine present in the bladder. Polypoid changes noted, consistent with potential transitional cell carcinoma versus severe chronic cystitis. The sand appeared to be luminal and not mural. Iliac lymph nodes were unremarkable.

The **kidneys** revealed normal size and structure, corticomedullary definition and ratio for this age. The cortices presented largely uniform texture with normal echogenic relationship to liver and spleen. Medullary structure differed distinctly from the cortex and no evidence of pelvic dilation was present. The capsules were acceptably uniform without significant irregularities. The left kidney measured 5.4 cm. The right kidney measured 5.65 cm. Mineralization noted in both kidneys, non-obstructive.

**Adrenal Glands**

Both **adrenal glands** were visualized and recognized as having normal shape, size, position and echogenicity for this breed. The phrenic vasculature, glandular echogenicity and detail were unremarkable. Capsule, cortex, and medullary definition were normal for this age patient. The left adrenal gland measured 2.44 cm x 0.44 cm at the cranial pole and 0.52 cm at the caudal pole.

**Spleen**

The **spleen** presented a smooth homogeneous parenchyma hyperechoic to liver and renal cortical parenchyma. The capsule was smooth without noticeable expansion or deviation from within the spleen or adjacent pathology. The splenic vasculature demonstrated normal volume without signs of congestion or thrombosis. No sonographic evidence of acute or chronic inflammatory, neoplastic, or infarctual changes were noted.

**Liver**

The **liver** images submitted revealed subjectively normal liver size, contour, and structure. Parenchymal echogenicity was naturally coarse and hypoechoic to the spleen. Vascular and biliary tracts were of normal volume with no evidence of congestion. The gallbladder presented acceptably thin walls with primarily anechoic content. The cystic and common bile ducts were normal. No pathological hepatic lymphadenopathy was evident. No overt structural evidence of inflammatory, infiltrative or regenerative pathology was evident.

**Gastrointestinal**

A minor amount of non-shadowing, non-obstructive ingesta was noted in the **stomach**. Transit of chyme into the small intestine was normal. Curvilinear patterns were maintained throughout the GI tract. No evidence of pathology. Small and large intestine demonstrated normal luminal chyme and stool



**PATIENT**

Daphne Casper

consistency respectively. No obstructive or overt infiltrative disease was noted. No associated abnormal lymphatic activity was noted.

**Pancreas**

**SPECIES**

Canine

The base and limbs of the **pancreas** were observed to be largely isoechoic to surrounding omental fat. Pancreatic duct and capsular contour were acceptably normal and parenchyma respected normal curvilinear patterns. No overt evidence of active inflammatory or neoplastic disease was noted.

**BREED**

Cocker Spaniel

**ULTRASONOGRAPHIC FINDINGS**

- Severe chronic cystitis with sand versus transitional cell carcinoma

**INTERPRETATION OF THE FINDINGS & FURTHER RECOMMENDATIONS**

**SEX**

Spayed Female

Cystoscopy would be ideal in this patient. Cytospin of a free catch urine sample warranted to assess for abnormal transitional cells. Otherwise, surgical approach with the objective of bladder biopsies and bladder lavage and culture could be considered. The pathology appears to be localized to the bladder itself. No evidence of metastatic disease. A primary cause of systemic hypertension is not evident.

**AGE**

12 Years

**WEIGHT**

13.6 kg

**INTERPRETED BY**

Eric Lindquist, DMV

DABVP, Cert. IVUSS

**IMAGING PERFORMED BY**

Erin Wicks

**HOSPITAL NAME**

Shores VEC

**REFERRING VET**

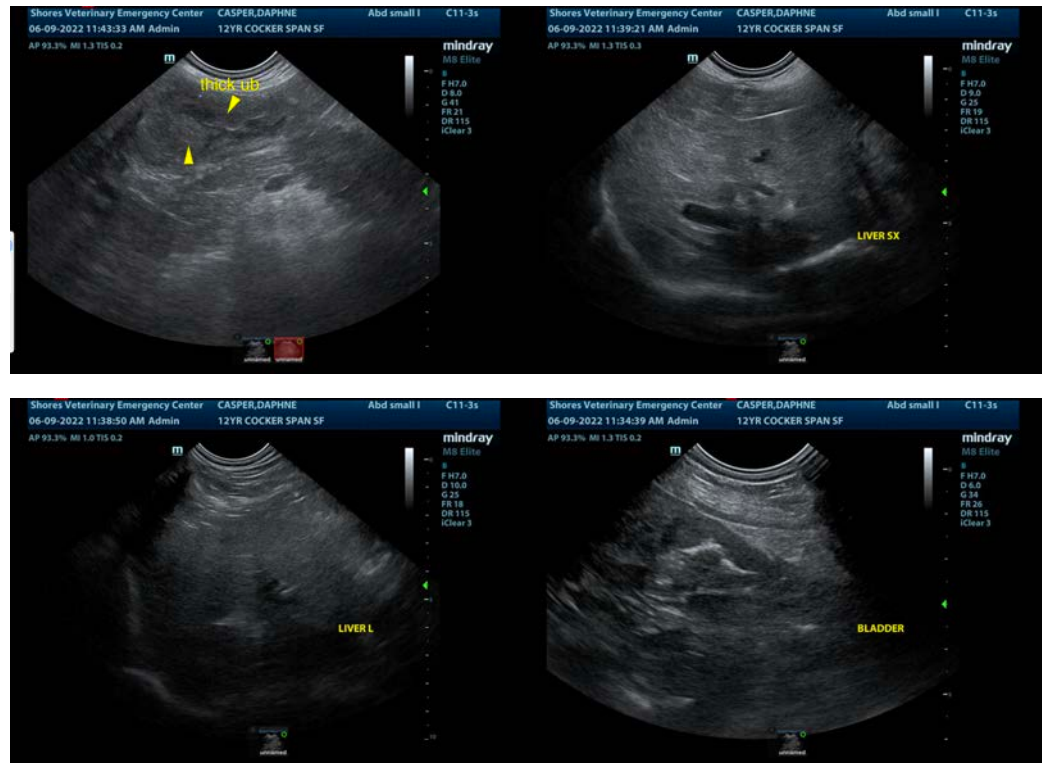
Dr. Nelson

**INVOICE**

38544

**DATE**

6/9/22





**PATIENT**

Daphne Casper

**SPECIES**

Canine

**BREED**

Cocker Spaniel

**SEX**

Spayed Female

**AGE**

12 Years

**WEIGHT**

13.6 kg

**INTERPRETED BY**

Eric Lindquist, DMV  
DABVP, Cert. IVUSS

**IMAGING PERFORMED BY**

Erin Wicks

**HOSPITAL NAME**

Shores VEC

**REFERRING VET**

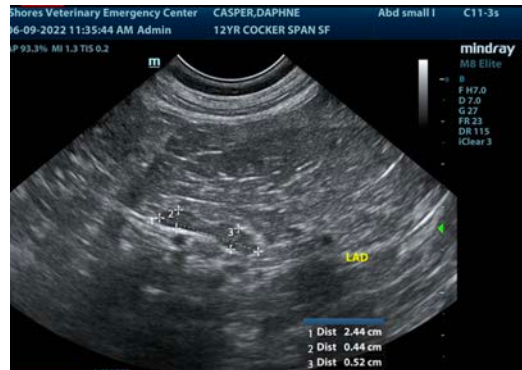
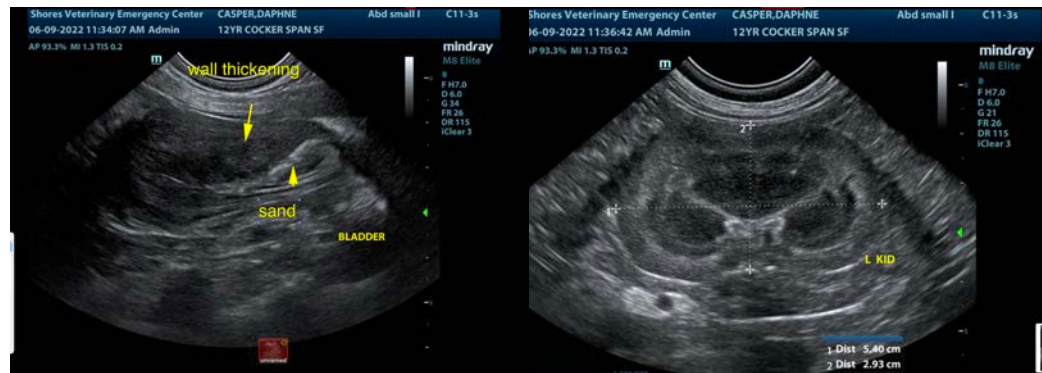
Dr. Nelson

**INVOICE**

38544

**DATE**

6/9/22



The information and recommendations provided are based on the images presented by the referring veterinarian/sonographer. No evaluation can be communicated regarding pathology that was not visible in the image/video clips provided.

Thank you for this referral. If the clinical or image interpretation does not parallel your findings or if I can be of any further assistance please contact me.

Eric Lindquist, DMV, DABVP, Cert. IVUSS, CEO of SonoPath.com

[info@SonoPath.com](mailto:info@SonoPath.com)



The following is an applicable excerpt from the *Curbside Guide to Diagnosis & Treatment of Sonographic Disease* offered by [SonoPath.com](http://SonoPath.com) Lindquist, Frank, Lobetti, and Modler.

An essential quick guide for every general practitioner and sonographer.

<https://sonopath.com/products/curbside-guide-editing-due-release-12012015>

**Systemic Hypertension**

<http://www.sonopath.com/Hypertension>



**PATIENT**

Daphne Casper

**SPECIES**

Canine

**BREED**

Cocker Spaniel

**SEX**

Spayed Female

**AGE**

12 Years

**WEIGHT**

13.6 kg

**INTERPRETED BY**

Eric Lindquist, DMV

DABVP, Cert. IVUS

**IMAGING PERFORMED BY**

Erin Wicks

**HOSPITAL NAME**

Shores VEC

**REFERRING VET**

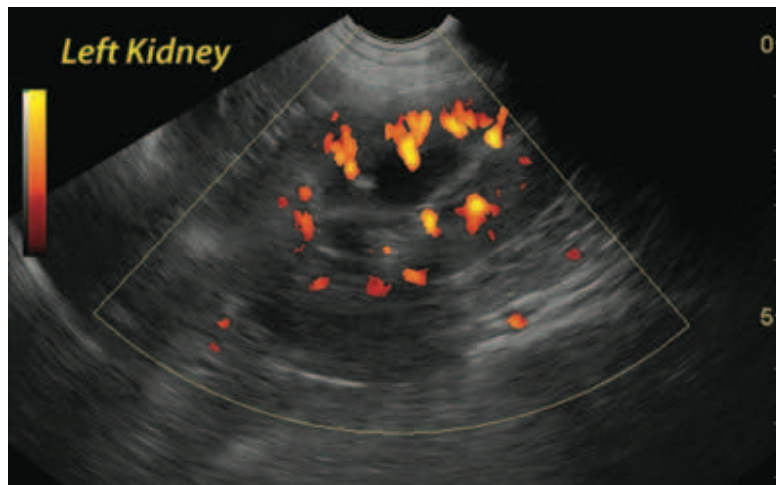Dr. Nelson

**INVOICE**

38544

**DATE**

6/9/22



Long axis of the left kidney in a hypertensive dog with nephritis and protein losing nephropathy. The Power Doppler shows a high perfusion intensity within the interlobar and arcuate vessels. Also note the abnormal presence of excessive renal cortical perfusion. Acute PLN cases often have unremarkable structural renal changes sonographically.

**Description:** Systemic hypertension refers to the persistent elevation of systemic blood pressure (BP) and is classified as either primary (essential or idiopathic) or secondary. Persistent damage caused by hypertension is typically noted in effector organs such as the eyes, central nervous system (CNS), heart, and kidneys. In cats, the most common diseases associated with systemic hypertension are chronic kidney disease and hyperthyroidism, whereas the same condition in dogs more typically results in chronic kidney disease (especially proteinuric renal disease), hyperadrenocorticism, diabetes mellitus, and pheochromocytoma. Less typical causes of systemic hypertension in both species include hyperaldosteronism, acromegaly, and the use of hypertensive medications (e.g. phenylpropanolamine and excessive thyroxine supplementation).

**Clinical Signs:** Although hypertension is often clinically silent, ophthalmologic changes are usually the most obvious signs. Ophthalmologic changes secondary to hypertension are better described in cats than in dogs, and include intraocular hemorrhage, hypertensive retinopathy, hypertensive choroidopathy, and hypertensive optic neuropathy. CNS signs can include seizures, vascular accidents, and changes in mentation. Congestive heart failure secondary to hypertensive cardiac changes is rare, but affected animals may exhibit increased sensitivity to fluid administration.

**Diagnostics:** Blood pressure values obtained during diagnostic evaluation must be assessed in conjunction with other clinical findings, such as retinal detachment as well as a history of polyuria and polydipsia, as these associated findings may point to the cause of the hypertension or indicate hypertension-associated organ damage. A single high blood pressure value should never be used to diagnose systemic hypertension in the absence of other clinical data, as patient distress or stress may artificially elevate blood pressure. Current recommendations suggest that a systolic blood pressure greater than 160 mm Hg is indicative of hypertension; however, the use of antihypertensive medications may not be warranted if blood pressure elevations are mild and underlying etiologies addressed. The minimum database should include physical examination, funduscopic examination, CBC, serum chemistry profile, urinalysis with urine protein quantification, and serum T4 assay in cats. Measuring the blood pressure in separate moments throughout the day in a quiet, non “white coat effect” environment, in a



**PATIENT**

Daphne Casper

home environment, or potentially with light opioid sedation (Buprenorphine 0.01 mg/kg) can also be considered when looking for hypertension. Empirically, in our experience, this opioid approach tends to be an effective approach when assessing for hypertension in excited patients. However, a complete comparative study is warranted.

**SPECIES**

Canine

**Treatment:** First, the use of any hypertensive medications should be discontinued immediately. Drug groups that can be used to control hypertension include angiotensin-converting enzyme (ACE) inhibitors (enalapril or benazepril 0.5 mg/kg PO BID), calcium channel blockers (amlodipine 0.625 mg PO Q24hr for cats and 0.1 mg/kg PO Q24hr for dogs), and beta blockers (atenolol 6.25-12.5 mg PO BID for cats and 0.25-1 mg/kg PO BID for dogs). Medications from different groups may be additionally administered if the original medication is not sufficiently controlling the condition.

**BREED**

Cocker Spaniel

**SEX**

Spayed Female

**AGE**

12 Years

**WEIGHT**

13.6 kg

**INTERPRETED BY**

Eric Lindquist, DMV

DABVP, Cert. IVUSS

**IMAGING PERFORMED BY**

Erin Wicks

**HOSPITAL NAME**

Shores VEC

**REFERRING VET**

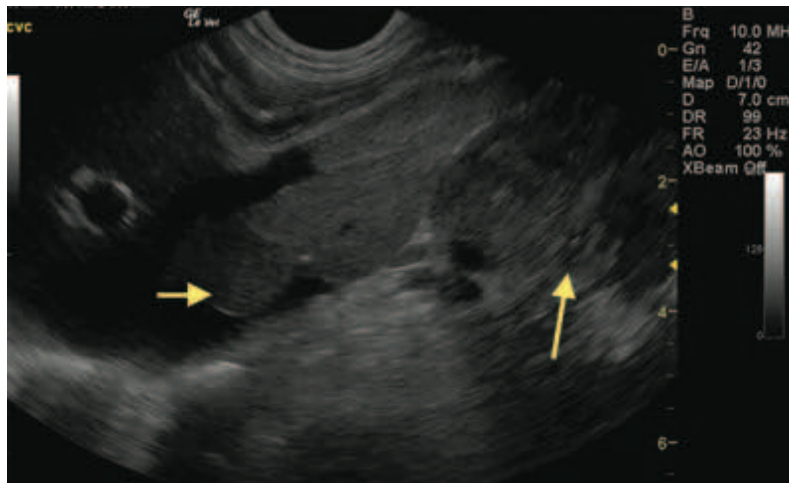
Dr. Nelson

**INVOICE**

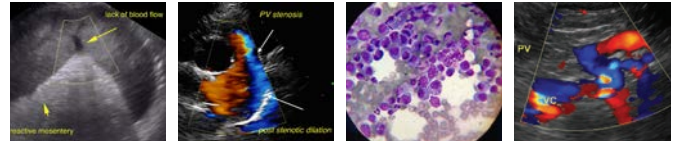
38544

**DATE**

6/9/22



Long axis of the right adrenal gland and caudal vena cava in a dog with a pheochromocytoma and hypertension. The enlarged heterogenous adrenal gland is seen on the image right (large arrow). There is tumoral invasion (small arrow) into the caudal vena cava via the phrenicoabdominal vein. The echogenic tumor material occupies the caval lumen entirely. Note the significant centrifugal mass effect of the intravascular tumor on the vessel wall as indicated by focal widening of the caval diameter. Part of the right liver lobes and descending duodenum are seen on the image left and in the near field.



**PATIENT**

Daphne Casper

**SPECIES**

Canine

**BREED**

Cocker Spaniel

**SEX**

Spayed Female

**AGE**

12 Years

**WEIGHT**

13.6 kg

**INTERPRETED BY**

Eric Lindquist, DMV

DABVP, Cert. IVUSS

**IMAGING PERFORMED BY**

Erin Wicks

**HOSPITAL NAME**

Shores VEC

**REFERRING VET**

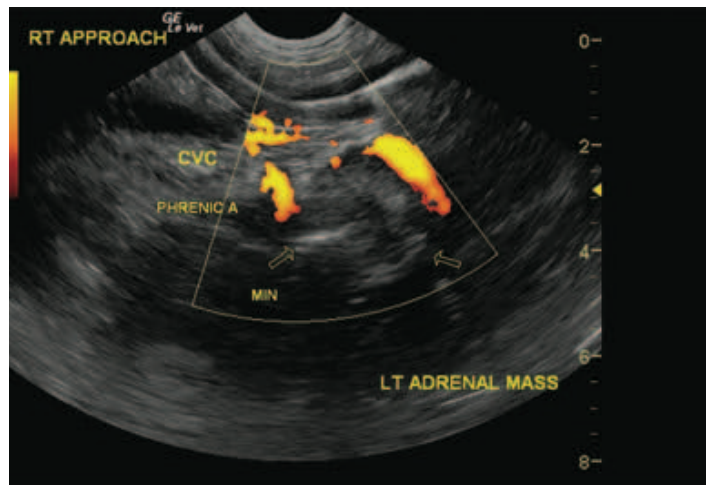
Dr. Nelson

**INVOICE**

38544

**DATE**

6/9/22



Long axis of a left-sided adrenal mass as imaged using a right lateral sonographic approach in a hypertensive dog. The enlarged heterogenous left-sided adrenal tumor is seen deep to the descending duodenum and caudal vena cava. Note the presence of multifocal mineralizations (MIN) within the tumor and the left phrenicoabdominal artery passing atop of the mass lesion.

**References:**

Brown S, et al. Guidelines for the identification, evaluation, and management of systemic hypertension in dogs and cats. *J Vet Intern Med* 2007;21:542-58.

Michell AR, Bodey AR, Caulfield M. Evolution, essential hypertension and the high arterial pressures in certain athletic breeds of dogs. *Vet J* 2011; 88:125-27.

Jepson RE, Elliott J, Brodbelt D, Syme HM. Effect of control of systolic blood pressure on survival in cats with systemic hypertension. *J Vet Intern Med* 2007;21:402-09.

Steele JL, Henik RA, Stepien RL. Effects of angiotensin-converting enzyme inhibition on plasma aldosterone concentration, plasma renin activity and blood pressure in spontaneously hypertensive cats with chronic renal disease. *Vet Ther* 2002;3:157-66.