



PATIENT

Mango Malcom

SPECIES

Feline

BREED

Domestic Longhair

SEX

Spayed female

AGE

3 years

WEIGHT

5.5 kg

INTERPRETED BY

Eric Lindquist, DMV
DABVP, Cert. IVUSS

IMAGING PERFORMED BY

Pamela Veldman

HOSPITAL NAME

Taylor VC

REFERRING VET

Dr. S Nain

INVOICE

78444

DATE

6/8/26

PRESENTING CLINICAL SIGNS

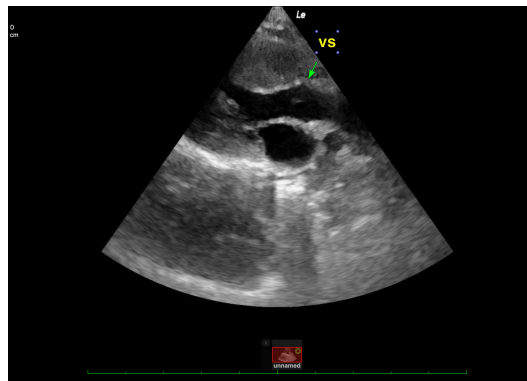
History: Follow up regarding concern for potential VSD, additional view with color performed along ventricular septum.

ULTRASONOGRAPHIC EXAMINATION OF THE HEART

The ventricular septum was further imaged in this patient and appears to be complete. There was no dropout noted and no evidence of VSD.

ULTRASONOGRAPHIC FINDINGS

No obvious evidence of ventricular septal defect based on the images provided.



The information and recommendations provided are based on the images presented by the referring veterinarian/sonographer. No evaluation can be communicated regarding pathology that was not visible in the image/video clips provided.

Thank you for this referral. If the clinical or image interpretation does not parallel your findings or if I can be of any further assistance please contact me.

Eric Lindquist, DMV, DABVP (CFM), Cert. IVUSS, CEO of SonoPath.com

info@SonoPath.com