



PATIENT

Lilly Catlin

SPECIES

Feline

BREED

Domestic Medium Hair

SEX

Spayed female

AGE

13 years

WEIGHT

7 lbs

INTERPRETED BY

Eric Lindquist, DMV
DABVP, Cert. IVUSS

IMAGING PERFORMED BY

Ray Caughman

HOSPITAL NAME

Dogwood AH

REFERRING VET

Dr. Caughman

INVOICE

78414

DATE

6/8/26

PRESENTING CLINICAL SIGNS

History: History of weight loss since 8/2025. Was 9 lbs then. Always has ravenous appetite.
Abnormal PE/Chem/CBC/UA Results: WBC 26k with neutrophilia, monocytosis, eosinophilia and basophilia. Increased total protein and globulin and decreased albumin

ULTRASONOGRAPHIC EXAMINATION OF THE ABDOMEN

Urinary System

The **urinary bladder**, trigone, and pelvic urethra presented normal thicknesses and normal tone. The ureters were not visible which is normal. No uroliths or sediment were visualized and anechoic urine was present. No evidence of inflammatory or neoplastic changes was noted. Ureteral papillae were normal.

The **kidneys** revealed normal size and structure, corticomedullary definition and ratio for this age. The cortices presented largely uniform texture with normal echogenic relationship to liver and spleen. Medullary structure differed distinctly from the cortex and no evidence of pelvic dilation was present. The capsules were acceptably uniform without significant irregularities. The left kidney measured 3.2 cm. The right kidney measured 3.5 cm.

Adrenal Glands

Both **adrenal glands** were visualized and recognized as having normal shape, size, position and echogenicity for this breed. The phrenic vasculature, glandular echogenicity and detail were unremarkable. Capsule, cortex, and medullary definition were normal for this age patient. The left adrenal gland measured 0.24 cm and the right adrenal gland measured 0.2 cm.

Spleen

The **spleen** presented a smooth homogeneous parenchyma hyperechoic to liver and renal cortical parenchyma. The capsule was smooth without noticeable expansion or deviation from within the spleen or adjacent pathology. The splenic vasculature demonstrated normal volume without signs of congestion or thrombosis. No sonographic evidence of acute or chronic inflammatory, neoplastic, or infarctual changes was noted.

Liver

The **liver** images submitted revealed subjectively normal liver size, contour, and structure. Parenchymal echogenicity was naturally coarse and hypoechoic to the spleen. Vascular and biliary tracts were of normal volume with no evidence of congestion. The gallbladder presented acceptably thin walls with primarily anechoic content. The cystic and common bile ducts were normal. No pathological hepatic lymphadenopathy was evident. No overt structural evidence of inflammatory, infiltrative or regenerative pathology was evident.



PATIENT

Lilly Catlin

SPECIES

Feline

BREED

Domestic Medium Hair

SEX

Spayed female

AGE

13 years

WEIGHT

7 lbs

INTERPRETED BY

Eric Lindquist, DMV
DABVP, Cert. IVUSS

IMAGING PERFORMED BY

Ray Caughman

HOSPITAL NAME

Dogwood AH

REFERRING VET

Dr. Caughman

INVOICE

78414

DATE

6/8/26

Gastrointestinal

The **gastrointestinal tract** revealed minor variable thickening and echogenic submucosal changes most consistent with low grade end result of chronic GI disease such as IBD and may be related to malassimilation of nutrients if any weight loss is present. No obvious neoplastic patterns were noted and luminal content as unremarkable. The mesenteric lymph nodes were reactive and measured up to 0.7 x 3.6 cm in length.

Pancreas

The base and limbs of the **pancreas** were observed to be largely isoechoic to surrounding omental fat. Pancreatic duct and capsular contour were acceptably normal and parenchyma respected normal curvilinear patterns. No overt evidence of active inflammatory or neoplastic disease was noted.

ULTRASONOGRAPHIC FINDINGS

Mild, diffuse intestinal thickening.

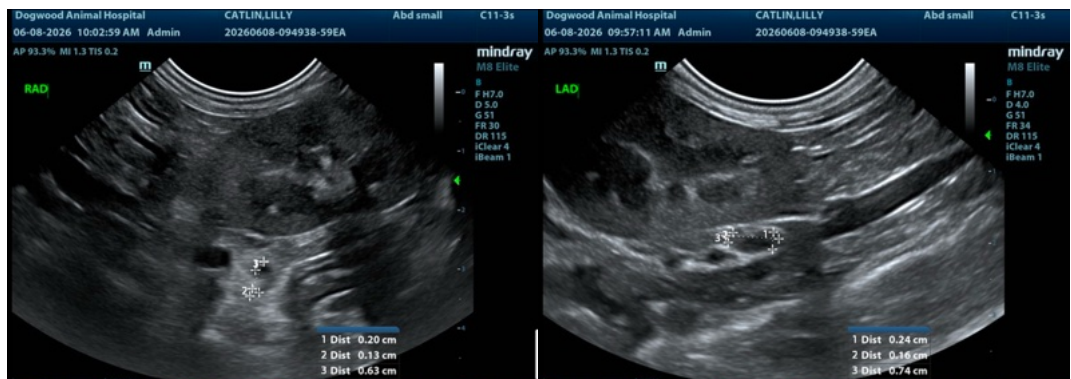
Reactive lymphadenitis, chronic IBD GI pattern.

Otherwise, unremarkable abdomen with age related abdominal changes.

INTERPRETATION OF THE FINDINGS & FURTHER RECOMMENDATIONS

I cannot rule out emerging round cell neoplasia in this patient; however, no overt neoplastic criteria is present. Full thickness intestinal lymph node biopsies would be ideal. Malassimilation is a strong potential in this patient.

Maldigestion panel, three view chest radiographs and full CNS examination is recommended to examine for occult disease that could be responsible for the weight loss. Evaluation for competitive eating environments should also be considered.





PATIENT

Lilly Catlin

SPECIES

Feline

BREED

Domestic Medium Hair

SEX

Spayed female

AGE

13 years

WEIGHT

7 lbs

INTERPRETED BY

Eric Lindquist, DMV
DABVP, Cert. IVUSS

IMAGING PERFORMED BY

Ray Caughman

HOSPITAL NAME

Dogwood AH

REFERRING VET

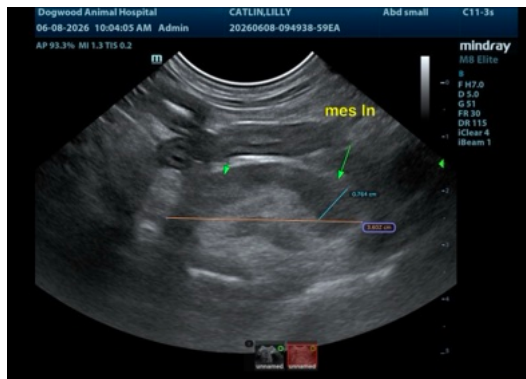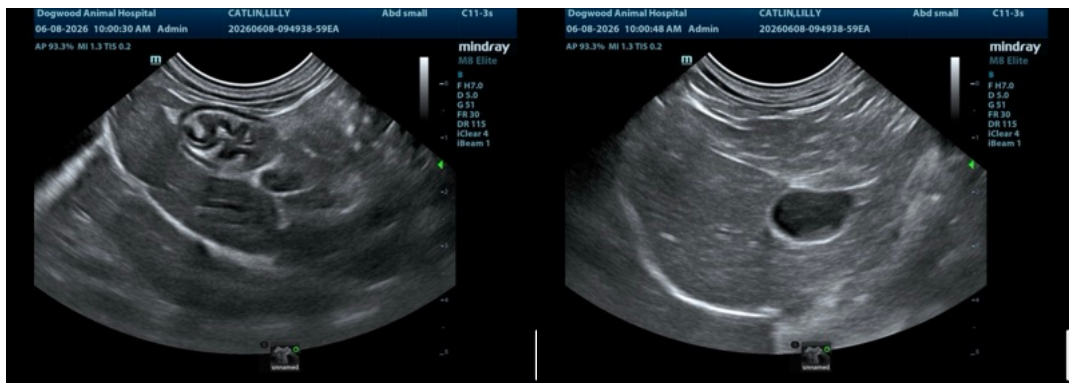
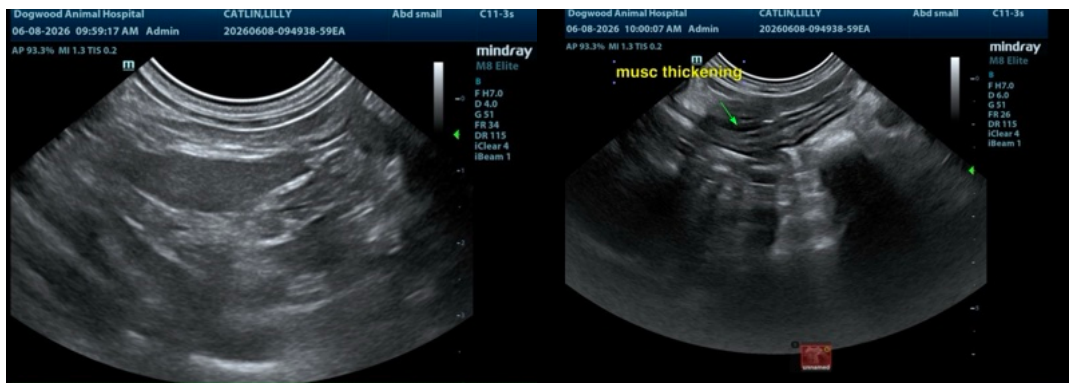
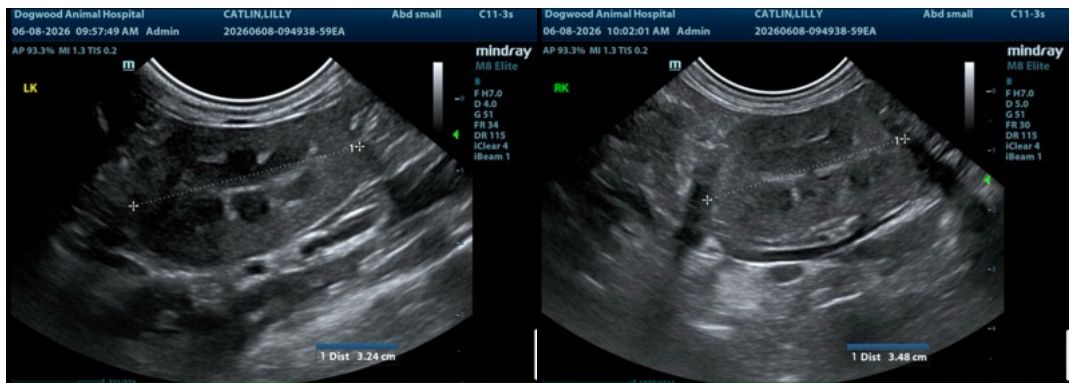
Dr. Caughman

INVOICE

78414

DATE

6/8/26





PATIENT

Lilly Catlin

SPECIES

Feline

BREED

Domestic Medium Hair

SEX

Spayed female

AGE

13 years

WEIGHT

7 lbs

INTERPRETED BY

Eric Lindquist, DMV
DABVP, Cert. IVUSS

IMAGING PERFORMED BY

Ray Caughman

HOSPITAL NAME

Dogwood AH

REFERRING VET

Dr. Caughman

INVOICE

78414

DATE

6/8/26

The information and recommendations provided are based on the images presented by the referring veterinarian/sonographer. No evaluation can be communicated regarding pathology that was not visible in the image/video clips provided.

Thank you for this referral. If the clinical or image interpretation does not parallel your findings or if I can be of any further assistance please contact me.

Eric Lindquist, DMV, DABVP (CFM), Cert. IVUSS, CEO of SonoPath.com

info@SonoPath.com