



PATIENT PRESENTING CLINICAL SIGNS

Zoey Billone History: Progression of heart murmur. Currently 4/6. Began vetmedin 1 week ago

SPECIES ULTRASONOGRAPHIC EXAMINATION OF THE HEART

Canine

BREED

Bichon Mix

SEX

Spayed Female

AGE

13 years

WEIGHT

13.5 lbs

INTERPRETED BY

Eric Lindquist, DMV
DABVP, Cert. IVUSS

IMAGING PERFORMED BY

Dr. Rodriguez

HOSPITAL NAME

Foxfield VS

REFERRING VET

Dr. Rodriguez

INVOICE

30916

DATE

6/8/22

The echocardiogram in this patient demonstrated normal **left atrial** size based on 3 separate methods of LA evaluation. The cranial and caudal **mitral valve** leaflets presented normal linear structure, extension in systole, and union in diastole with normal kinesis. The **left ventricle** presented thicknesses with linear contour and was not dilated nor restricted. The **myocardium** presented normal echogenicity without subjective evidence of significant fibrotic or ischemic disease. **Contractility** of the ventricular walls was adequate and in normal range for this patient evidenced by the fractional shortening measurement and subjective evaluation of the different regions of the myocardium. The **left ventricular outflow** tract demonstrated normal laminar flow and subjective structural integrity. The **right atrium** and auricle revealed normal size, structure and content. No evidence of masses was noted. **Tricuspid** valvular assessment demonstrated adequate linear morphology and kinesis. The **right ventricle** was of normal size (1/3 diameter of LV), chordae structure, myocardial echogenicity and thickness. **Pulmonary outflow** tract assessment revealed normal valve structure, laminar flow, and diameter (approx. 1:1 pa/ao ratio). No visible **pericardial** or free pleura fluid was noted. The cranial **mediastinum and pericardial and extra-cardiac regions** were free of masses in the visible window. An occasional arrhythmia was noted in this patient.

CANINE CARDIAC PARAMETERS	MR VMAX (m/s)	TR VMAX (m/s)	LA/AO (Boon method)	LA/AO (Heart Base; Swe)	FS (%)	EF (%)	EPSS (cm)
NORMAL PARAMETER	4.5-5.5	<2.7	1.3	<1.3	28-40	40-100	<0.6
PATIENT	6.0		1.15	1.7	40	80	0.13
CANINE CARDIAC PARAMETERS	HR (BPM)	AV VMAX (m/s)	PV MAX (m/s)	BODY WEIGHT	LA (2D short axis Base view) (cm)	LVIDd (Avg; 2D and m-mode short axis) (cm)	LVIDs (Avg; 2D and m-mode short axis) (cm)
NORMAL PARAMETER	50-100	0.7-1.7	0.7-1.6				
PATIENT		1.9		13.5 lbs	2.57	1.93	

ULTRASONOGRAPHIC FINDINGS

Compensated valvular disease.

INTERPRETATION OF THE FINDINGS & FURTHER RECOMMENDATIONS

B1: The heart is stable without clinical disease. No overt contraindication for anesthesia of brief to moderate duration. I suggest Torbutrol premed, Propofol induction, Isoflurane maintenance or similar protocol if anesthesia is desired. Blood pressure recommended if not already performed and target



PATIENT

Zoey Billone

white coat negative systolic pressure of < 160 mmHg. If higher than this ACE-inhibitor is suggested to reach this level. Recheck echocardiogram is recommended in 6 months, earlier if murmur grade increases or clinical signs initiate.

SPECIES

Canine

Unless the patient demonstrated significant changes radiographically I do not believe that Pimobendan is indicated at this time. Pimobendan could be stopped and recheck sonogram could be considered after 5 days to assess any changes. However, this appears to be compensated.

BREED

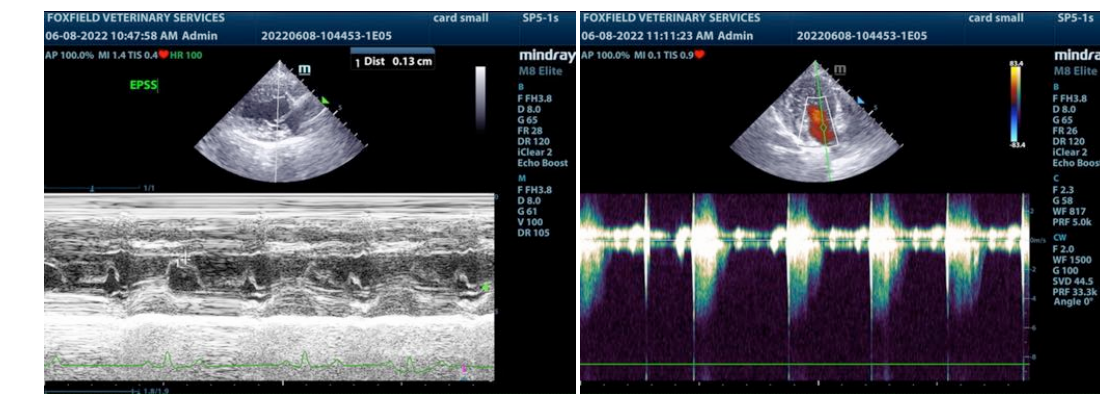
Bichon Mix

SEX

Spayed Female

AGE

13 years

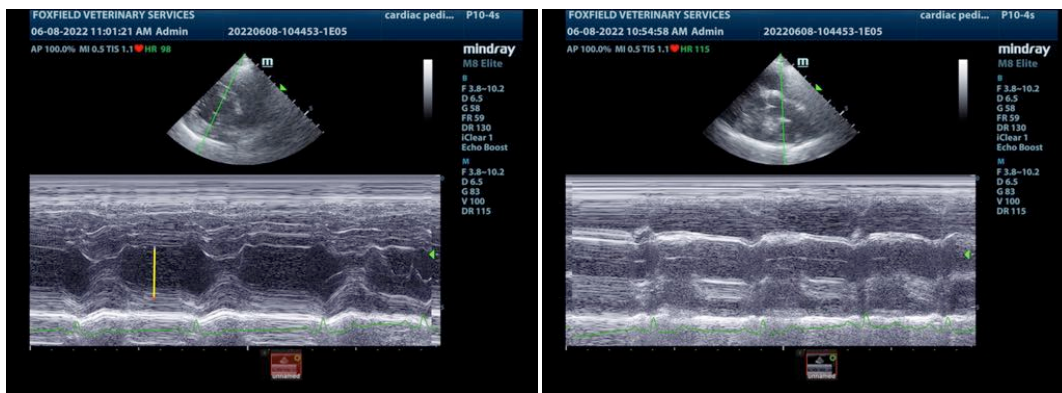


WEIGHT

13.5 lbs

INTERPRETED BY

Eric Lindquist, DMV
DABVP, Cert. IVUS



IMAGING PERFORMED BY

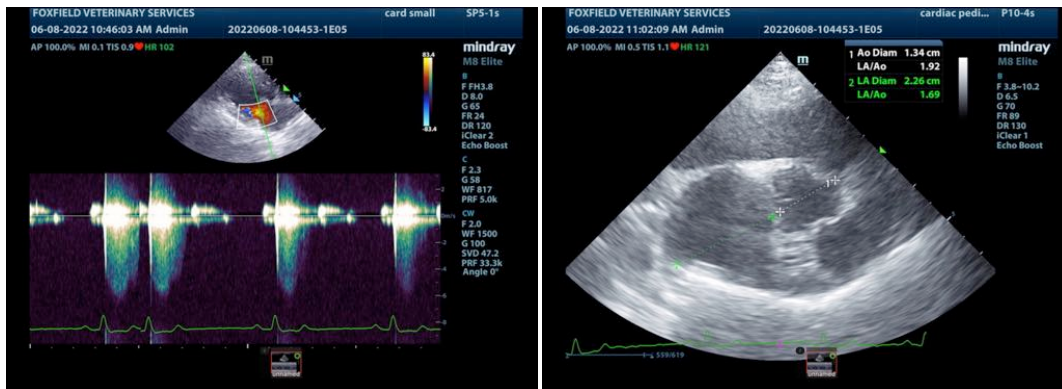
Dr. Rodriguez

HOSPITAL NAME

Foxfield VS

REFERRING VET

Dr. Rodriguez



INVOICE

30916

DATE

6/8/22



PATIENT

Zoey Billone

SPECIES

Canine

BREED

Bichon Mix

SEX

Spayed Female

AGE

13 years

WEIGHT

13.5 lbs

INTERPRETED BY

Eric Lindquist, DMV
DABVP, Cert. IVUSS

IMAGING PERFORMED BY

Dr. Rodriguez

HOSPITAL NAME

Foxfield VS

REFERRING VET

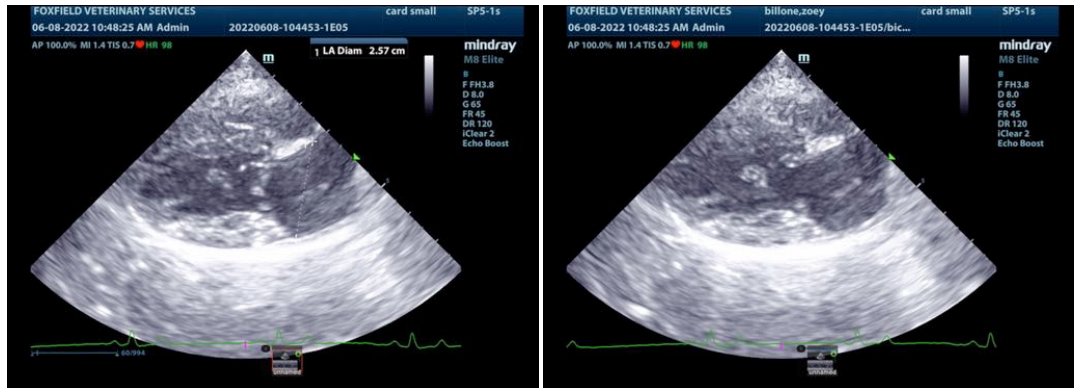
Dr. Rodriguez

INVOICE

30916

DATE

6/8/22



The information and recommendations provided are based on the images presented by the referring veterinarian/sonographer. No evaluation can be communicated regarding pathology that was not visible in the image/video clips provided.

Thank you for this referral. If the clinical or image interpretation does not parallel your findings or if I can be of any further assistance please contact me.

Eric Lindquist, DMV, DABVP, Cert. IVUSS, CEO of SonoPath.com
info@SonoPath.com