



**PATIENT**

Toby Elghammer

**SPECIES**

Feline

**BREED**

Domestic Medium hair

**SEX**

Neutered male

**AGE**

11 years

**WEIGHT**

11.5 lbs

**INTERPRETED BY**

Eric Lindquist, DMV  
DABVP, Cert. IVUSS

**IMAGING PERFORMED BY**

Carissa Rhoades

**HOSPITAL NAME**

Elizabeth AH

**REFERRING VET**

Dr. Anderson

**INVOICE**

30928

**DATE**

6/8/22

**PRESENTING CLINICAL SIGNS**

**History:** Toby has had chronic vomiting for months. He had dark colored vomit on 4/25/22 treated with cerenia and sucralfate. For the last few days he has been vomiting with some blood tinge to it. He vomits at least once a day and usually at night. **PE:** Stage II Dental disease. Some muscle atrophy over spine. 1/2 # weight loss since April. Full Panel in early April: Mild elevation in Creatinine and large elevation in spec fPL. NSAID was normal late April.

**Abnormal PE/Chem/CBC/UA Results:** PE: Stage II Dental disease. Some muscle atrophy over spine. 1/2 # weight loss since April. Full Panel in early April: Mild elevation in Creatinine and large elevation in spec fPL. NSAID was normal late April. USG 1.015 in April.

**ULTRASONOGRAPHIC EXAMINATION OF THE ABDOMEN**

**Urinary System**

The **urinary bladder**, trigone, and pelvic urethra presented normal thicknesses and normal tone. The ureters were not visible which is normal. No uroliths or sediment were visualized and anechoic urine was present. No evidence of inflammatory or neoplastic changes was noted. Ureteral papillae were normal.

The **kidneys** revealed largely normal size and structure, corticomedullary definition and ratio (cortex 1/3 of medulla) were essentially maintained with some age-related loss of curvilinear patterns regarding the capsule and C/M junction. The cortices presented largely uniform texture with some increased echogenicity expected for this age patient. Medullary structure differed distinctly from that of the cortex and no evidence of pelvic dilation was present. The left kidney measured 3.5 cm. The right kidney measured 3.5 cm.

**Adrenal Glands**

Both **adrenal glands** were visualized and recognized as having normal shape, size, position and echogenicity for this breed. The phrenic vasculature, glandular echogenicity and detail were unremarkable. Capsule, cortex, and medullary definition were normal for this age patient. The left adrenal gland measured 0.4 cm. The right adrenal gland measured 0.42 cm.

**Spleen**

The **spleen** presented a smooth homogeneous parenchyma hyperechoic to liver and renal cortical parenchyma. The capsule was smooth without noticeable expansion or deviation from within the spleen or adjacent pathology. The splenic vasculature demonstrated normal volume without signs of congestion or thrombosis. No sonographic evidence of acute or chronic inflammatory, neoplastic, or infarctual changes was noted.

**Liver**

The **liver** images submitted revealed subjectively normal liver size, contour, and structure. Parenchymal echogenicity was naturally coarse and hypoechoic to the spleen. Vascular and biliary tracts were of normal volume with no evidence of congestion. The gallbladder presented acceptably thin walls with primarily anechoic content. The cystic and common bile ducts were normal. No pathological hepatic



**PATIENT**

Toby Elghammer

lymphadenopathy was evident. No overt structural evidence of inflammatory, infiltrative or regenerative pathology was evident.

**SPECIES**

Feline

**Gastrointestinal**

Examination of the **gastrointestinal tract** revealed a stomach and intestine free of stasis, of normal wall thickness, acceptable curvilinear mural detail, and peristaltic activity. Small and large intestine demonstrated normal luminal chyme and stool consistency respectively. No obstructive or overt infiltrative disease was noted. No associated abnormal lymphatic activity was noted.

**BREED**

Domestic Medium hair

**Pancreas**

**SEX**

Neutered male

The base and limbs of the **pancreas** were observed to be largely isoechoic to surrounding omental fat. Pancreatic duct and capsular contour were acceptably normal and parenchyma respected normal curvilinear patterns. No overt evidence of active inflammatory or neoplastic disease was noted.

**AGE**

11 years

**ULTRASONOGRAPHIC FINDINGS**

Structurally unremarkable abdomen.

**WEIGHT**

11.5 lbs

Moderate degenerative renal changes.

**INTERPRETED BY**

Eric Lindquist, DMV  
DABVP, Cert. IVUSS

**INTERPRETATION OF THE FINDINGS & FURTHER RECOMMENDATIONS**

There is no evidence of pathology. Occult parasitism, structurally insignificant inflammatory bowel and food intolerance are all potentials in this patient. Pre renal and renal disease may be playing a role.

**IMAGING PERFORMED BY**

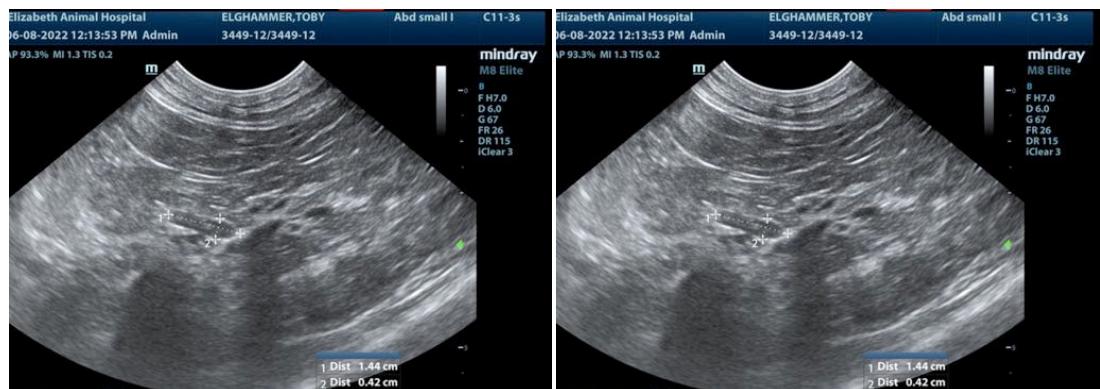
Carissa Rhoades

**HOSPITAL NAME**

Elizabeth AH

**REFERRING VET**

Dr. Anderson



**INVOICE**

30928

**DATE**

6/8/22



**PATIENT**

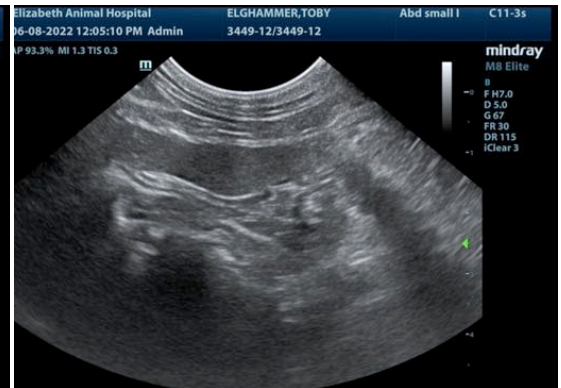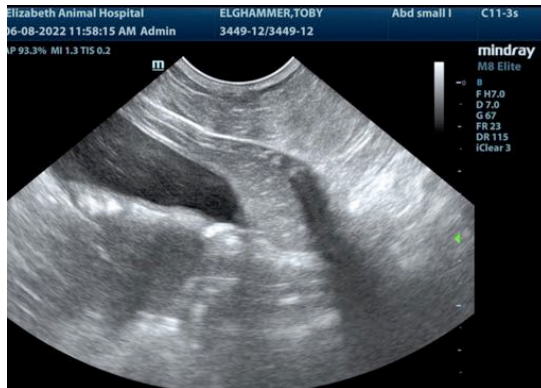Toby Elghammer

**SPECIES**

Feline

**BREED**

Domestic Medium hair



**SEX**

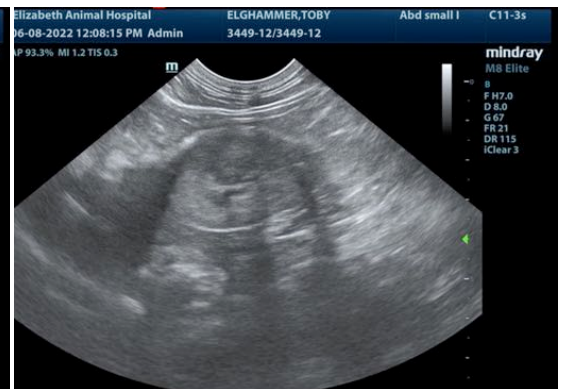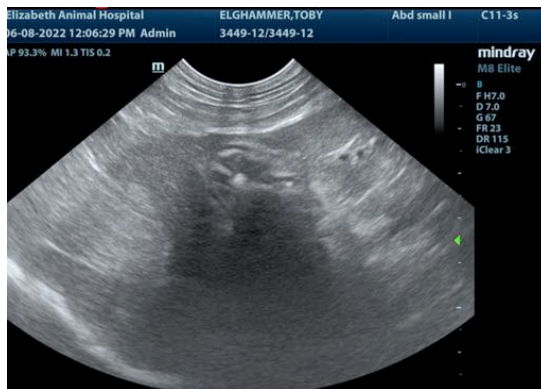Neutered male

**AGE**

11 years

**WEIGHT**

11.5 lbs



**INTERPRETED BY**

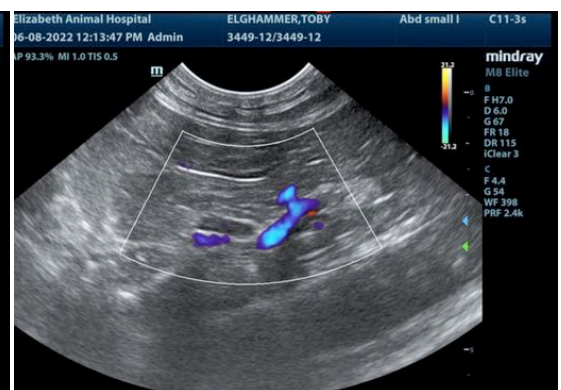
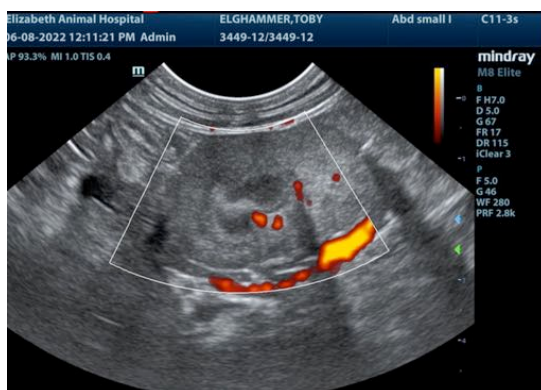
Eric Lindquist, DMV  
DABVP, Cert. IVUSS

**IMAGING PERFORMED BY**

Carissa Rhoades

**HOSPITAL NAME**

Elizabeth AH



**REFERRING VET**

Dr. Anderson

**INVOICE**

30928

**DATE**

6/8/22

The information and recommendations provided are based on the images presented by the referring veterinarian/sonographer. No evaluation can be communicated regarding pathology that was not visible in the image/video clips provided.

Thank you for this referral. If the clinical or image interpretation does not parallel your findings or if I can be of any further assistance please contact me.



**PATIENT**

Eric Lindquist, DMV, DABVP, Cert. IVUSS, CEO of SonoPath.com  
info@SonoPath.com

Toby Elghammer

**SPECIES**

Feline

**BREED**

Domestic Medium hair

**SEX**

Neutered male

**AGE**

11 years

**WEIGHT**

11.5 lbs

**INTERPRETED BY**

Eric Lindquist, DMV  
DABVP, Cert. IVUSS

**IMAGING  
PERFORMED BY**

Carissa Rhoades

**HOSPITAL NAME**

Elizabeth AH

**REFERRING VET**

Dr. Anderson

**INVOICE**

30928

**DATE**

6/8/22