



PATIENT

Mike Stewart

SPECIES

Canine

BREED

Boxer Pitbull Mix

SEX

Neutered male

AGE

7 years

WEIGHT

68 lb

INTERPRETED BY

Eric Lindquist, DMV
DABVP, Cert. IVUSS

IMAGING PERFORMED BY

Dr. Ebersole

HOSPITAL NAME

Scanvet

REFERRING VET

Dr. Fortin

INVOICE

309230

DATE

6/8/22

PRESENTING CLINICAL SIGNS

History: History of skin allergies, on Cytopoint. Recent onset of not eating in the morning, stomach gurgling, eating grass and general low energy. Did not do well with hypoallergenic diet trial (Hydrolyzed). No improvement with acid reducers or gas-x.

Abnormal PE/Chem/CBC/UA Results: BW, redrawn today, previously WNL. RADS, done today after US.

ULTRASONOGRAPHIC EXAMINATION OF THE ABDOMEN

Urinary System

The **urinary bladder**, trigone, and pelvic urethra presented normal thicknesses and normal tone. The ureters were not visible which is normal. No uroliths or sediment were visualized and anechoic urine was present. No evidence of inflammatory or neoplastic changes was noted. Ureteral papillae were normal.

The **kidneys** revealed normal size and structure, corticomedullary definition and ratio for this age. The cortices presented largely uniform texture with normal echogenic relationship to liver and spleen. Medullary structure differed distinctly from the cortex and no evidence of pelvic dilation was present. The capsules were acceptably uniform without significant irregularities. The right kidney measured 6.6 cm. The left kidney measured 6.2 cm.

Adrenal Glands

Both **adrenal glands** were visualized and recognized as having normal shape, size, position and echogenicity for this breed. The phrenic vasculature, glandular echogenicity and detail were unremarkable. Capsule, cortex, and medullary definition were normal for this age patient. The left adrenal gland measured 0.6 cm at the caudal pole and 0.48 cm at the cranial pole. The right adrenal gland measured 2.52 x 0.84 cm at the cranial pole and 0.61 cm at the caudal pole.

Spleen

The **spleen** in this patient was mildly enlarged with uniform parenchyma and was folded upon itself cranially. This is a positional variant and is not pathological. There was no evidence of significant disease.

Liver

The **liver** revealed slight coarse architecture. The liver had normal vascularity. The gallbladder and common bile duct were unremarkable.

Gastrointestinal

A minor amount of non-shadowing, non-obstructive ingesta was noted in the **stomach**. Transit of chyme into the small intestine was normal. Curvilinear patterns were maintained throughout the GI tract. No evidence of pathology. Small and large intestine demonstrated normal luminal chyme and stool



PATIENT

Mike Stewart

consistency respectively. No obstructive or overt infiltrative disease was noted. No associated abnormal lymphatic activity was noted.

SPECIES

Canine

Pancreas

The base and limbs of the **pancreas** were observed to be largely isoechoic to surrounding omental fat. Pancreatic duct and capsular contour were acceptably normal and parenchyma respected normal curvilinear patterns. No overt evidence of active inflammatory or neoplastic disease was noted.

BREED

Boxer Pitbull Mix

ULTRASONOGRAPHIC FINDINGS

SEX

Neutered male

Minor hepatic remodeling.

Folded spleen.

Full stomach.

AGE

7 years

INTERPRETATION OF THE FINDINGS & FURTHER RECOMMENDATIONS

No specific therapy is recommended in this patient.

WEIGHT

68 lb

INTERPRETED BY

Eric Lindquist, DMV
DABVP, Cert. IVUSS

IMAGING PERFORMED BY

Dr. Ebersole

HOSPITAL NAME

Scanvet

REFERRING VET

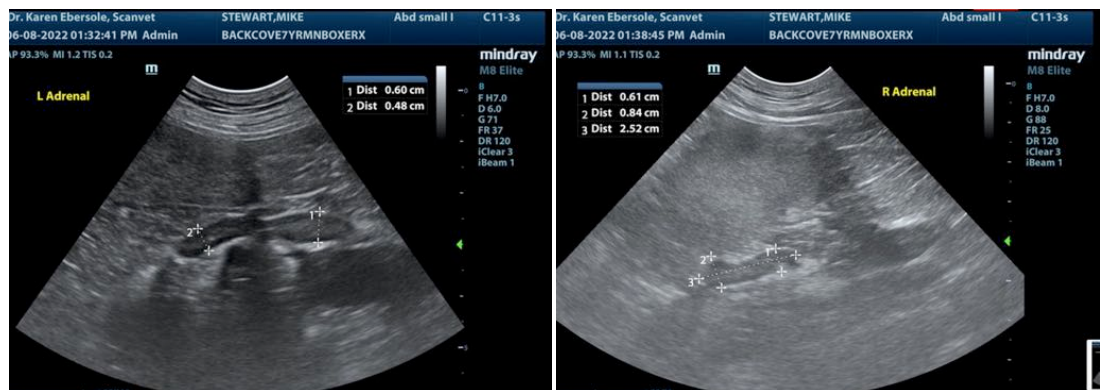
Dr. Fortin

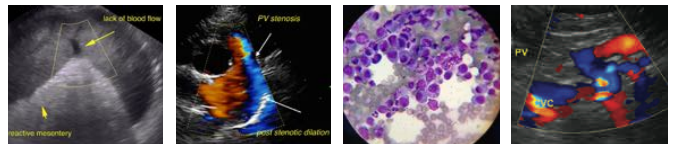
INVOICE

309230

DATE

6/8/22





PATIENT

Mike Stewart

SPECIES

Canine

BREED

Boxer Pitbull Mix

SEX

Neutered male

AGE

7 years

WEIGHT

68 lb

INTERPRETED BY

Eric Lindquist, DMV
DABVP, Cert. IVUSS

IMAGING PERFORMED BY

Dr. Ebersole

HOSPITAL NAME

Scanvet

REFERRING VET

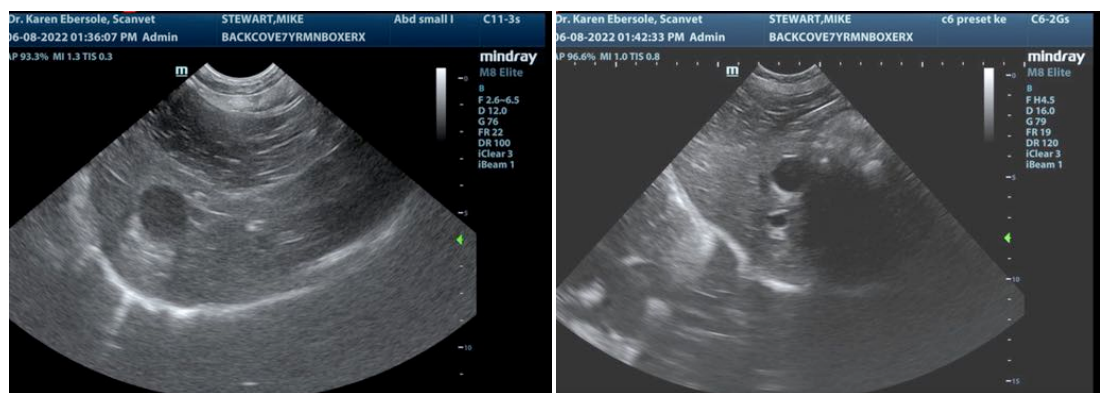
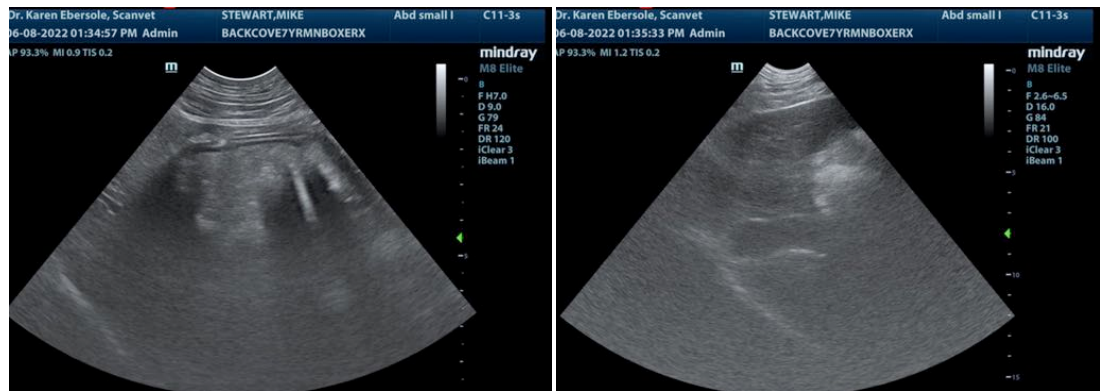
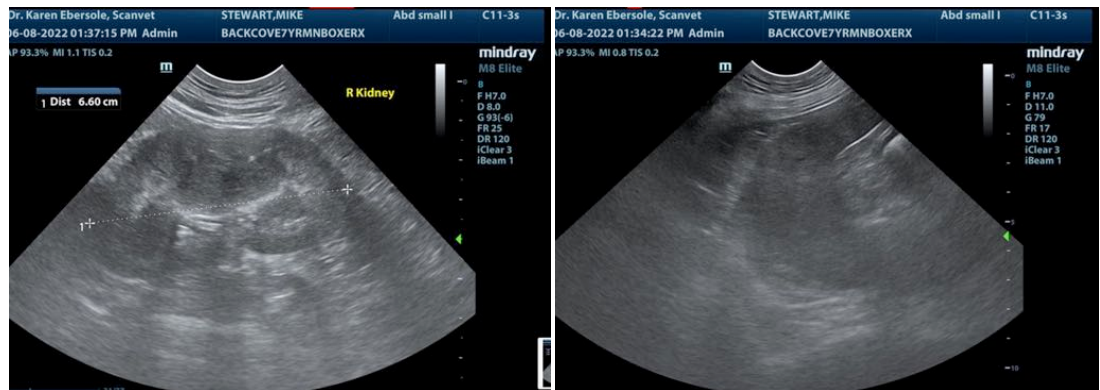
Dr. Fortin

INVOICE

309230

DATE

6/8/22



The information and recommendations provided are based on the images presented by the referring veterinarian/sonographer. No evaluation can be communicated regarding pathology that was not visible in the image/video clips provided.

Thank you for this referral. If the clinical or image interpretation does not parallel your findings or if I can be of any further assistance please contact me.

Eric Lindquist, DMV, DABVP, Cert. IVUSS, CEO of SonoPath.com



PATIENT

info@SonoPath.com

Mike Stewart

SPECIES

Canine

BREED

Boxer Pitbull Mix

SEX

Neutered male

AGE

7 years

WEIGHT

68 lb

INTERPRETED BY

Eric Lindquist, DMV
DABVP, Cert. IVUSS

**IMAGING
PERFORMED BY**

Dr. Ebersole

HOSPITAL NAME

Scanvet

REFERRING VET

Dr. Fortin

INVOICE

309230

DATE

6/8/22