



**PATIENT**

DJ Bob Holt

**SPECIES**

Canine

**BREED**

French Bulldog

**SEX**

MN

**AGE**

1 year

**WEIGHT**

25 pounds

**INTERPRETED BY**

Eric Lindquist, DMV  
DABVP, Cert. IVUSS

**IMAGING  
PERFORMED BY**

Mack

**HOSPITAL NAME**

Northside Veterinary  
Clinic

**REFERRING VET**

Dr. Mack

**INVOICE**

10752ag

**DATE**

06/08/2022

**PRESENTING CLINICAL SIGNS**

History: history of cyst / abscess behind the left eye. Treated with prednisone 10mg bid , was previously on Baytril then switched to Clindamycin 150mg BID , on omeprazole 20mg BID . Patient will be seen by specialist (waiting for appt) Depressed and vomiting started 2 days ago  
Abnormal PE/Chem/CBC/UA Results: CPL - + ALt -291 Lipase -2043 Phos 7.9 retic- hbg- 29.8

**ULTRASONOGRAPHIC EXAMINATION OF THE ABDOMEN**

**Urinary System**

The urinary bladder, trigone, and pelvic urethra presented normal thicknesses and normal tone to a depth of 2 cm. The ureters were not visible which is normal. No uroliths or sediment were visualized and anechoic urine was present. No evidence of inflammatory or neoplastic changes were noted. Ureteral papillae were normal.

The kidneys revealed normal size and structure, corticomedullary definition and ratio for this age. The cortices presented largely uniform texture with normal echogenic relationship to liver and spleen. Medullary structure differed distinctly from the cortex and no evidence of pelvic dilation was present. The capsules were acceptably uniform without significant irregularities. The left kidney measured 4.0 cm in length. The right kidney measured 4.0 cm in length.

The residual prostate was uniform measuring 5.0 mm.

**Adrenal Glands**

Both adrenal glands were visualized and recognized as having normal shape, size, position and echogenicity for this breed. The phrenic vasculature, glandular echogenicity and detail were unremarkable. Capsule, cortex, and medullary definition were normal for this age patient. The right adrenal gland measured 0.6 cm.

**Spleen**

The spleen presented a smooth homogeneous parenchyma hyperechoic to liver and renal cortical parenchyma. The capsule was smooth without noticeable expansion or deviation from within the spleen or adjacent pathology. The splenic vasculature demonstrated normal volume without signs of congestion or thrombosis. No sonographic evidence of acute or chronic inflammatory, neoplastic, or infarctual changes were noted.

**Liver**

The liver images submitted revealed subjectively normal liver size, contour, and structure. Parenchymal echogenicity was naturally coarse and hypoechoic to the spleen. Vascular and biliary tracts were of normal volume with no evidence of congestion. The gallbladder presented acceptably thin walls with primarily anechoic content. The cystic and common bile ducts were normal. No pathological hepatic lymphadenopathy was evident. No overt structural evidence of inflammatory, infiltrative or regenerative pathology was evident.

**Gastrointestinal**

Examination of the gastrointestinal tract revealed a stomach and intestine free of stasis, of normal wall thickness, acceptable curvilinear mural detail, and peristaltic activity. Small and large intestine



**PATIENT**

DJ Bob Holt

demonstrated normal luminal chyme and stool consistency respectively. No obstructive or overt infiltrative disease was noted. No associated abnormal lymphatic activity was noted.

**Pancreas**

**SPECIES**

Canine

The base and limbs of the pancreas were observed to be largely isoechoic to surrounding omental fat. Pancreatic duct and capsular contour were acceptably normal and parenchyma respected normal curvilinear patterns. No overt evidence of active inflammatory or neoplastic disease was noted.

**BREED**

French Bulldog

**ULTRASONOGRAPHIC FINDINGS**

- Structurally unremarkable abdomen

**SEX**

**INTERPRETATION OF THE FINDINGS & FURTHER RECOMMENDATIONS**

MN

No evidence of abdominal pathology related to the clinical history was observed on today's scan. No contraindication to anesthetic procedures if necessary.

**AGE**

1 year

Prednisone could be suppressing more significant presentation in this patient yet no evidence of structural disease noted.

**WEIGHT**

25 pounds

**INTERPRETED BY**

Eric Lindquist, DMV  
DABVP, Cert. IVUSS

**IMAGING PERFORMED BY**

Mack

**HOSPITAL NAME**

Northside Veterinary  
Clinic

**REFERRING VET**

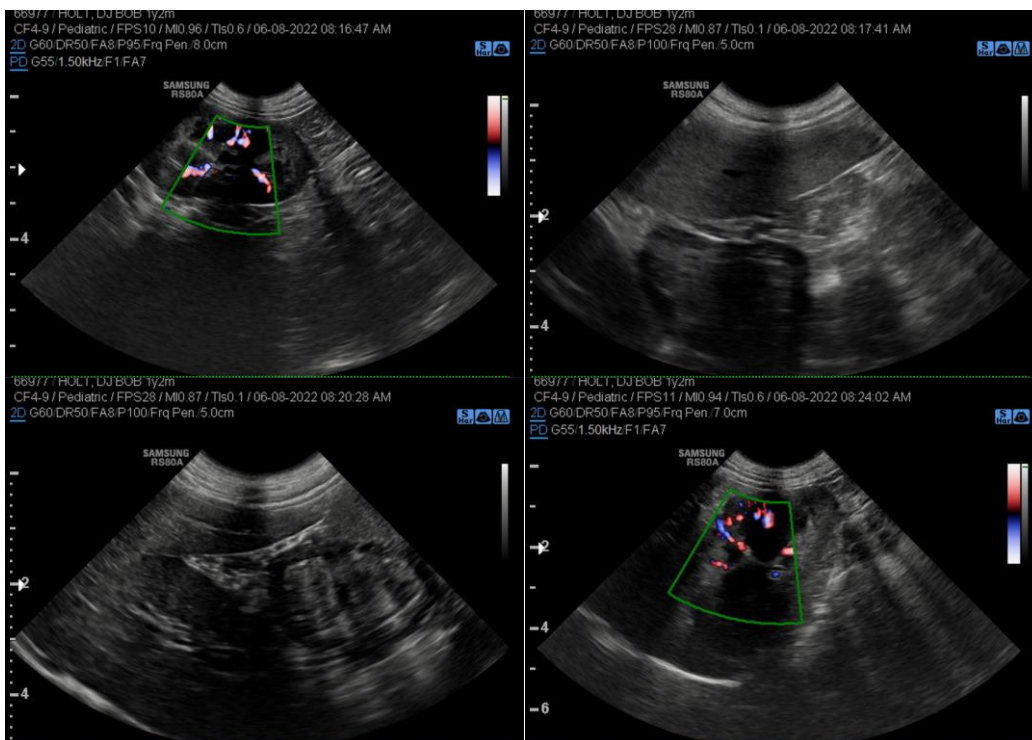
Dr. Mack

**INVOICE**

10752ag

**DATE**

06/08/2022





**PATIENT**

DJ Bob Holt

**SPECIES**

Canine

**BREED**

French Bulldog

**SEX**

MN

**AGE**

1 year

**WEIGHT**

25 pounds

**INTERPRETED BY**

Eric Lindquist, DMV  
DABVP, Cert. IVUSS

**IMAGING  
PERFORMED BY**

Mack

**HOSPITAL NAME**

Northside Veterinary  
Clinic

**REFERRING VET**

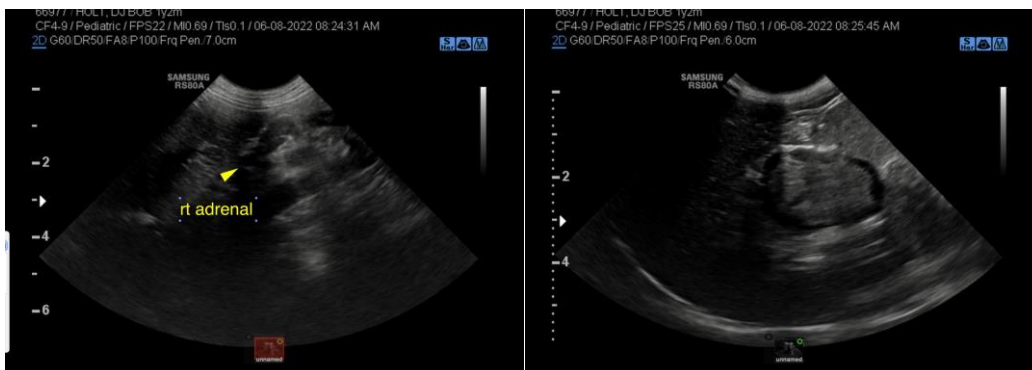
Dr. Mack

**INVOICE**

10752ag

**DATE**

06/08/2022



The information and recommendations provided are based on the images presented by the referring veterinarian. No evaluation can be communicated regarding pathology that was not visible in the image/video clips provided.

Thank you for this referral. If the clinical or image interpretation does not parallel your findings or if I can be of any further assistance please contact me.

**Eric Lindquist, DMV, DABVP, Cert. IVUSS, CEO of SonoPath.com**  
Eric.Lindquist@SonoPath.com