



**DATE PRESENTING CLINICAL SIGNS**

06/07/26 Patient History: The patient began vomiting multiple times Friday  
She has been observed drinking large amounts of water followed by dry heaving.

**PATIENT** Softer stool or accidents were found in her crate, which is abnormal for her.  
She has not eaten since breakfast yesterday, though she did accept a small cookie last night.

Sadie Fishman The owner reports a history of chewing on a mat months ago and possible exposure to a piece of plastic.

**SPECIES** The patient was at a dog park yesterday and appeared normal prior to the onset of clinical signs.

Canine Lifestyle: Visits dog parks.

Medical History & Diagnoses:

Canine Last estrous cycle was approximately 3/6/2026 - 3/20/2026

**BREED** Treatments: Cerenia 2.5ml administered SQ. After blood pressure was found to be 48mmHg systolic,  
IV catheter was placed and a fluid bolus of 250ml/15min was initiated (10ml/kg)

Golden Retriever Current Medications: 2 fluid boluses (10 ml/kg) then plasmalyte @5 ml/kg/hr

**SEX** Fentanyl 5 mcg/kg/hr

Unasyn 50 mg/kg iv q 8 hours

Intact Female Enrofloxacin 10 mg/kg iv q 24 hours

Maropitant 1 mg/kg iv q 24 hours

Ondansetron 0.5 mg/kg iv q 8 hours

**AGE** Labwork Results: Labwork not submitted. Reported as--Blood Glucose: 158 mg/dL

04/06/25 CBC/Chemistry/cPL: The CBC was consistent with a stress leukogram (lymphocytopenia,  
eosinopenia). The total white blood cell count was within normal limits. Chemistry showed a mild  
hepatocellular hepatopathy, a mild hyperglycemia, a mildly elevated cholesterol, a mildly elevated  
albumin, a mildly elevated phosphorus, and a mildly low calcium, chloride, and sodium.

**WEIGHT**

24.4 kg

cPL was negative (<100ng/ml).

Abdominal Radiographs: Findings include distended fluid-filled loops, a mildly gas-distended stomach,  
and hyperechoic material within the colon. No obvious foreign body was visualized in the pylorus. The  
findings are suspicious for an obstructive pattern or pyometra.

Recheck radiographs suggest functional ileus with granular FB material, no obstruction.

Date of Previous IntraPet Ultrasound: No previous.

Sedation: Not required to complete full diagnostic ultrasound.

Stat Report: Requested.

Imaging Performed by: Andi Parkinson, BS, RDMS.

**INTERPRETED BY**

Eric Lindquist, DMV,  
DABVP(CFM), Cert.  
IVUSS

**HOSPITAL NAME**

VEG Pikesville

**ULTRASONOGRAPHIC EXAMINATION OF THE ABDOMEN**

**REFERRING VET**

Dr. King

**Urinary System**

The **urinary bladder**, trigone, and pelvic urethra presented normal thicknesses and normal tone. The ureters  
were not visible which is normal. No uroliths or sediment were visualized, and anechoic urine was present.

No evidence of inflammatory or neoplastic changes were noted. Ureteral papillae were normal. Foley  
catheter was placed in the proper position.

**INVOICE**

16412

The ovaries and uterus were unremarkable. The right ovary measured 1.2 cm. The uterus measured 1.0 cm.

The **kidneys** revealed normal size and structure, corticomedullary definition and ratio for this age. The  
cortices presented largely uniform texture with normal echogenic relationship to liver and spleen. Medullary  
structure differed distinctly from the cortex and no evidence of pelvic dilation was present. The capsules

were acceptably uniform without significant irregularities. The left kidney measured 6.64 cm in length. The right kidney measured 7.02 cm in length.

### ***Adrenal Glands***

Both **adrenal glands** were visualized and recognized as having normal shape, size, position and echogenicity for this breed. The phrenic vasculature, glandular echogenicity and detail were unremarkable. Capsule, cortex, and medullary definition were normal for this age patient. The left adrenal gland measured 2.55 cm x 0.45 cm width at the cranial pole and 0.38 cm width at the caudal pole. The right adrenal gland measured 2.75 cm x 0.95 cm width at the cranial pole and 0.58 cm width at the caudal pole.

### ***Spleen***

The **spleen** presented a smooth homogeneous parenchyma hyperechoic to liver and renal cortical parenchyma. The capsule was smooth without noticeable expansion or deviation from within the spleen or adjacent pathology. The splenic vasculature demonstrated normal volume without signs of congestion or thrombosis. No sonographic evidence of acute or chronic inflammatory, neoplastic, or infarctual changes were noted. The spleen was folded upon itself caudally.

### ***Liver***

The **liver** images submitted revealed subjectively normal liver size, contour, and structure. Parenchymal echogenicity was naturally coarse and hypoechoic to the spleen. Vascular and biliary tracts were of normal volume with no evidence of congestion. The gallbladder presented acceptably thin walls with primarily anechoic content. The cystic and common bile ducts were normal. No pathological hepatic lymphadenopathy was evident. No overt structural evidence of inflammatory, infiltrative or regenerative pathology was evident.

### ***Gastrointestinal***

The **stomach** was over distended with anechoic fluid. The pylorus was thickened without loss of mural detail. No evidence of obstruction, however, hyperechoic mucosal remodeling was present consistent with mucosal ulcerative disease and muscularis hypertrophy. The small intestine was unremarkable until the level of the distal ileum just prior to the ileocecal junction with some fluid dilation present yet no evidence of obstruction. The colon revealed hard stool or possible passed foreign body embedded in the colon. No overt GI obstructive pattern was present.

### ***Pancreas***

The base and limbs of the **pancreas** were observed to be largely isoechoic to surrounding omental fat. Pancreatic duct and capsular contour were acceptably normal and parenchyma respected normal curvilinear patterns. No overt evidence of active inflammatory or neoplastic disease was noted.

### ***Free Abdomen***

The mesenteric **lymph nodes** presented normal length to width ratio with slight, swollen contour. There was no loss of parenchymal detail. This is most consistent with reactive lymphadenitis or lymphatic hyperplasia.

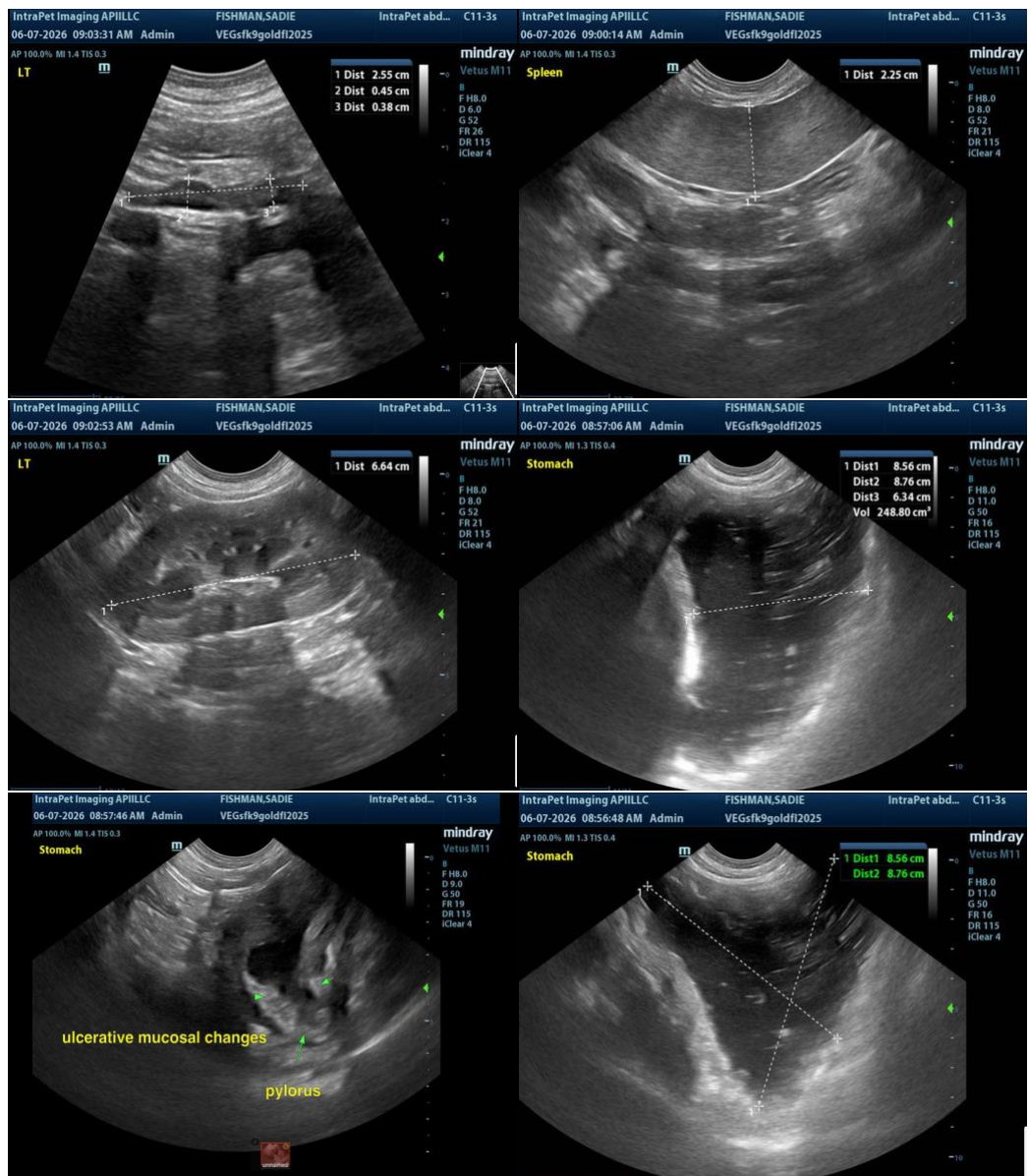
## **ULTRASONOGRAPHIC FINDINGS**

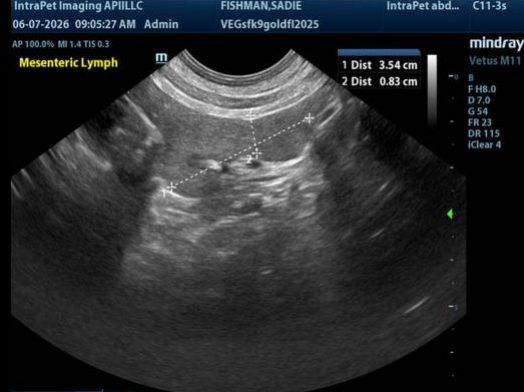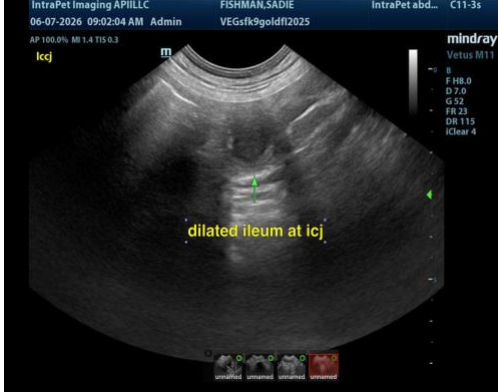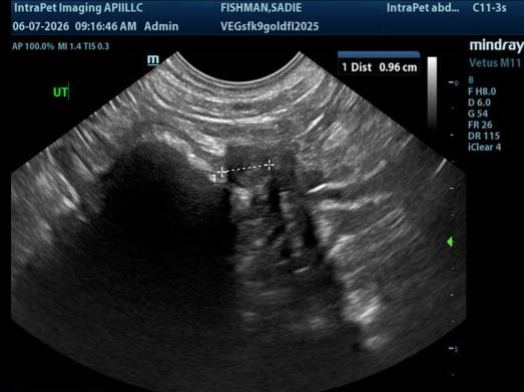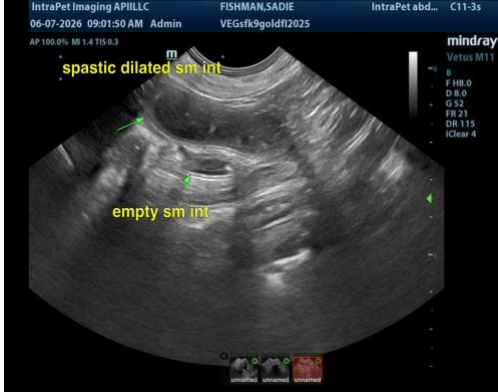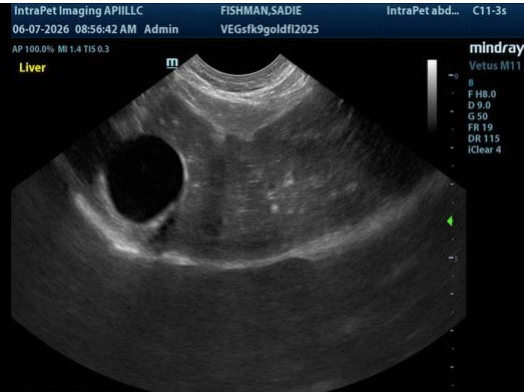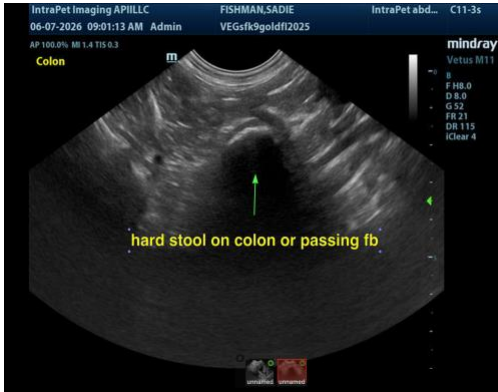- Gastric ileus with distal small intestinal dilation at the level of the ileocecal junction and hard stool.

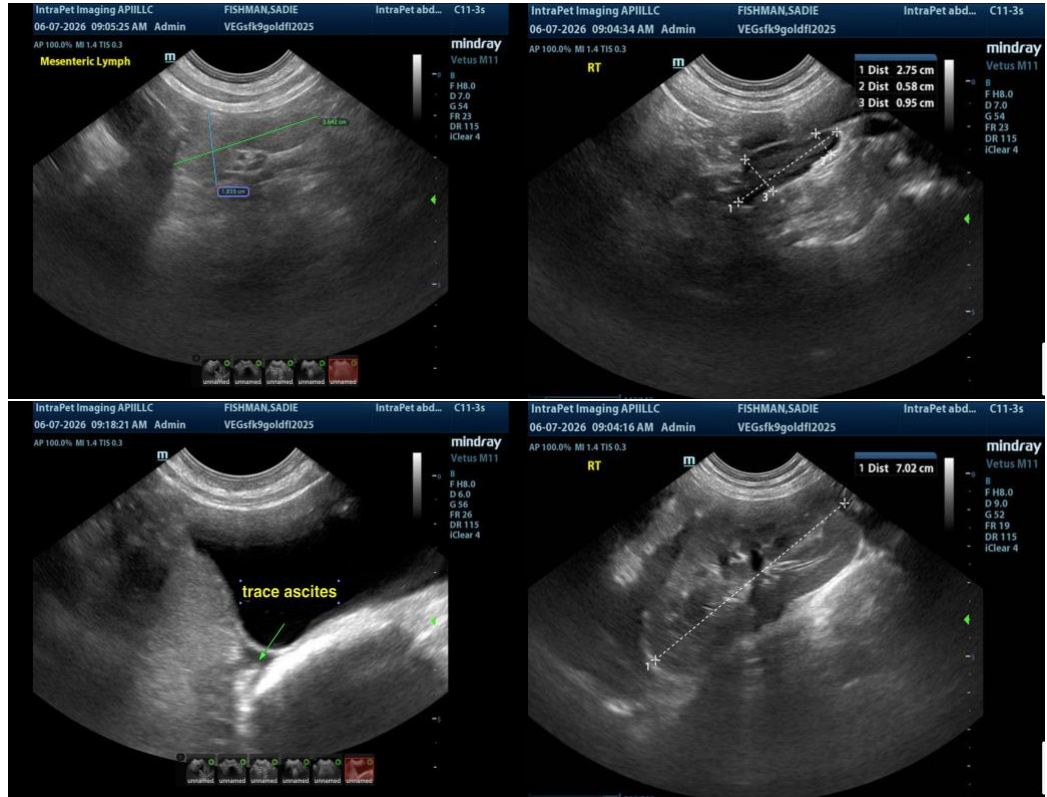
- Splenic folding.
- Mesenteric lymph nodes.

### INTERPRETATION OF THE FINDINGS & FURTHER RECOMMENDATIONS

Recommended medical management in this patient. GI protectant protocol, management for enterotoxins, examination of the stool production for any potential foreign matter and recheck sonogram in 48-72 hours to ensure adequate resolution.







The information and recommendations provided are based on the images presented by the referring veterinarian/sonographer. No evaluation can be communicated regarding pathology that was not visible in the image/video clips provided.

Thank you for this referral. If the clinical or image interpretation does not parallel your findings or if I can be of any further assistance, please contact me.

Eric Lindquist, DMV, DABVP(CFM), Cert. IVUSS,

CEO, Owner, Founder -- SonoPath.com

[info@SonoPath.com](mailto:info@SonoPath.com)