



<b>PATIENT</b>	<b>PRESENTING CLINICAL SIGNS</b>
Toby Tozer	Losing weight. managed hyperthyroid cat Abnormal PE/Chem/CBC/UA Results: total bili 0.5, alkphos 105, sdma 18, t4 2.8
<b>SPECIES</b>	<b>ULTRASONOGRAPHIC EXAMINATION OF THE ABDOMEN</b>
Feline	<b>Urinary System</b>
<b>BREED</b>	The <b>urinary bladder</b> was structurally unremarkable. However, some coalescing debris was noted. This does not appear to be tissue related. Power Doppler of the area in question should be performed to assess if vascularity is present.
Domestic Shorthair	
<b>SEX</b>	The <b>kidneys</b> presented a relatively uniform cortical hyperechogenicity when compared to the renal medulla, spleen and liver. No overt masses were noted. Corticomedullary definition was nebulous and the ratio favored the cortex slightly. The ureters were not visible and assumed to be normal. These changes are most consistent with chronic interstitial nephritis yet infiltrative disease could not be entirely ruled out without biopsy though neoplasia is not suspected. The left kidney measured 4.08 cm. The right kidney measured 4.16 cm.
Neutered male	
<b>AGE</b>	
14 years	
<b>WEIGHT</b>	<b>Adrenal Glands</b>
9.8 lbs	Both <b>adrenal glands</b> were visualized and recognized as having normal shape, size, position and echogenicity for this breed. The phrenic vasculature, glandular echogenicity and detail were unremarkable. Capsule, cortex, and medullary definition were normal for this age patient. The adrenal glands measured 0.5 cm.
<b>INTERPRETED BY</b>	
Eric Lindquist, DMV DABVP, Cert. IVUSS	<b>Spleen</b>
<b>IMAGING PERFORMED BY</b>	The <b>spleen</b> revealed subtle, micronodular changes with minor enlargement. The spleen was folded upon itself cranially and caudally.
Dr. Roche	
<b>HOSPITAL NAME</b>	<b>Liver</b>
Fredon AH	The <b>liver</b> was slightly swollen and mildly irregular with slightly increased portal markings. The gallbladder and common bile duct were unremarkable.
<b>REFERRING VET</b>	
Dr. Roche	<b>Gastrointestinal</b>
<b>INVOICE</b>	Examination of the <b>gastrointestinal tract</b> revealed a stomach and intestine free of stasis, of normal wall thickness, acceptable curvilinear mural detail, and peristaltic activity. Small and large intestine demonstrated normal luminal chyme and stool consistency respectively. No obstructive or overt infiltrative disease was noted. No associated abnormal lymphatic activity was noted.
30892	
<b>DATE</b>	
6/7/22	



**PATIENT**

**Pancreas**

Toby Tozer

The base and limbs of the **pancreas** were observed to be largely isoechoic to surrounding omental fat. Some parenchymal remodeling, however, with mild deviation from curvilinear normalcy was observed. Pancreatic duct and capsular irregularities were present consistent with age related changes. If pain upon imaging (+ Murphy sign) was present or if the patient is focally painful in subxiphoid palpation then low-grade smoldering chronic pancreatitis should be suspected.

**SPECIES**

Feline

**BREED**

Domestic Shorthair

**ULTRASONOGRAPHIC FINDINGS**

Chronic interstitial nephrosis renal pattern.

**SEX**

Irregular and micronodular spleen with splenohepatomegaly.

Neutered male

**INTERPRETATION OF THE FINDINGS & FURTHER RECOMMENDATIONS**

**AGE**

FNA of the spleen and liver are recommended to assess for round cell neoplasia versus splenitis and reactive liver.

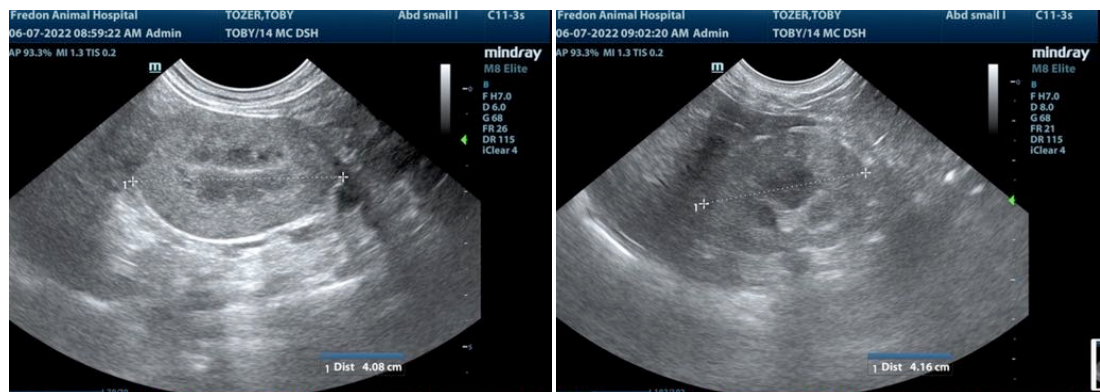
14 years

**WEIGHT**

9.8 lbs

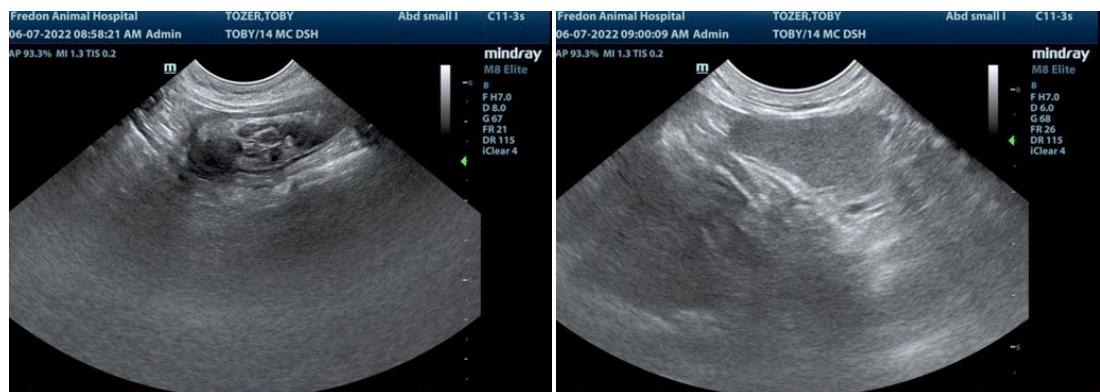
**INTERPRETED BY**

Eric Lindquist, DMV  
DABVP, Cert. IVUS



**IMAGING PERFORMED BY**

Dr. Roche



**HOSPITAL NAME**

Fredon AH

**REFERRING VET**

Dr. Roche

**INVOICE**

30892

**DATE**

6/7/22



**PATIENT**

Toby Tozer

**SPECIES**

Feline

**BREED**

Domestic Shorthair

**SEX**

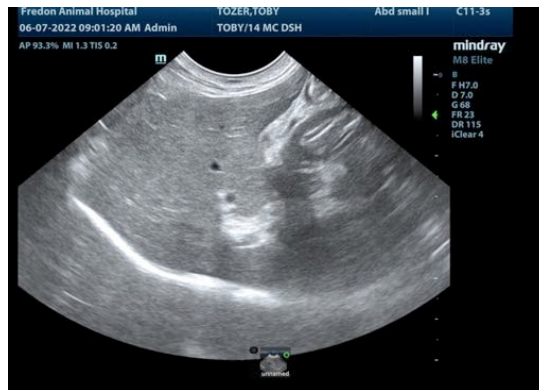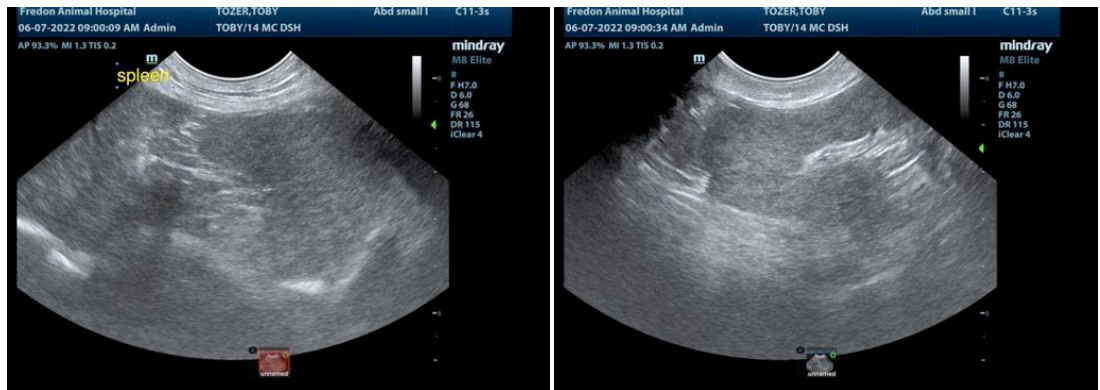
Neutered male

**AGE**

14 years

**WEIGHT**

9.8 lbs



**INTERPRETED BY**

Eric Lindquist, DMV  
DABVP, Cert. IVUSS

The information and recommendations provided are based on the images presented by the referring veterinarian/sonographer. No evaluation can be communicated regarding pathology that was not visible in the image/video clips provided.

**IMAGING PERFORMED BY**

Dr. Roche

Thank you for this referral. If the clinical or image interpretation does not parallel your findings or if I can be of any further assistance please contact me.

**HOSPITAL NAME**

Fredon AH

Eric Lindquist, DMV, DABVP, Cert. IVUSS, CEO of SonoPath.com  
info@SonoPath.com

**REFERRING VET**

Dr. Roche

**INVOICE**

30892

**DATE**

6/7/22