



PATIENT

Skye Brawn Henderson

SPECIES

Canine

BREED

Airedale Terrier

SEX

Spayed Female

AGE

10 years

WEIGHT

25 kg

INTERPRETED BY

Eric Lindquist, DMV
DABVP, Cert. IVUSS

IMAGING PERFORMED BY

Dr. Belan

HOSPITAL NAME

Signal Hill AH

REFERRING VET

Dr. Lebouldus

INVOICE

30911

DATE

6/7/22

PRESENTING CLINICAL SIGNS

History: Suspect protein losing nephropathy and pancreatitis. Ab 63 images echo 56 images 119 total

Abnormal PE/Chem/CBC/UA Results: Marked elevation of cPL but no vomiting renal values ok and protein in urine Repeating blood work today.

ULTRASONOGRAPHIC EXAMINATION OF THE ABDOMEN

Urinary System

The **urinary bladder**, trigone, and pelvic urethra presented normal thicknesses and normal tone. The ureters were not visible which is normal. No uroliths or sediment were visualized and anechoic urine was present. No evidence of inflammatory or neoplastic changes was noted. Ureteral papillae were normal.

The **kidneys** revealed normal size and structure, corticomedullary definition and ratio for this age. The cortices presented largely uniform texture with normal echogenic relationship to liver and spleen. Medullary structure differed distinctly from the cortex and no evidence of pelvic dilation was present. The capsules were acceptably uniform without significant irregularities. The right kidney measured 6.63 cm. The left kidney measured 6.47 cm.

Adrenal Glands

Both **adrenal glands** were visualized and recognized as having normal shape, size, position and echogenicity for this breed. The phrenic vasculature, glandular echogenicity and detail were unremarkable. Capsule, cortex, and medullary definition were normal for this age patient. The right adrenal gland measured 0.46 cm. The left adrenal gland measured 0.54 cm at maximum width.

Spleen

The **spleen** presented a smooth homogeneous parenchyma hyperechoic to liver and renal cortical parenchyma. The capsule was smooth without noticeable expansion or deviation from within the spleen or adjacent pathology. The splenic vasculature demonstrated normal volume without signs of congestion or thrombosis. No sonographic evidence of acute or chronic inflammatory, neoplastic, or infarctual changes was noted.

Liver

The **liver** images from right and left intercostal as well as subcostal views revealed subjectively normal liver size, contour, and structure. Some age-related parenchymal remodeling was noted but likely not clinically significant at this time. Vascular and biliary tracts were of normal volume and no evidence of congestion was noted. The gallbladder presented some dependent debris with essentially normal contour. The cystic and common bile ducts were normal. No overt evidence of active inflammatory, infiltrative or regenerative pathology was noted but should be paired with current or past LE elevations regarding any clinical significance to this presentation. The hepatic lymph nodes were unremarkable.



PATIENT

Gastrointestinal

Skye Brawn Henderson

The **stomach** revealed minor uniform thickening with hypertrophied muscularis and minor gastric artifact. There was no loss of mural detail. The small intestine is unremarkable. The mesenteric lymph nodes were reactive and measured up to 0.6 cm in width.

SPECIES

Canine

Pancreas

BREED

Airedale Terrier

The right **pancreatic** limb revealed hypoechoic, ill-defined 1.8 cm nodule with hyperechoic, ill-defined surrounding fat. This is suggestive for necrosis or potential neoplastic event.

SEX

Spayed Female

ULTRASONOGRAPHIC EXAMINATION OF THE HEART

AGE

10 years

The echocardiogram in this patient demonstrated normal **left atrial** size based on 3 different LA measurement methods. Chamber volumes and echogenicity were normal. The cranial and caudal **mitral** valve leaflets presented vegetative thickening consistent with endocardiosis. Eccentric moderate jet was noted on color flow assessment of the mitral valve. Doppler indicated measurable insufficiency. The **left ventricle** presented thicknesses with linear contour and was not dilated nor restricted. The **myocardium** presented normal echogenicity without subjective evidence of significant fibrotic or ischemic disease. **Contractility** of the ventricular walls was adequate and in normal range for this patient evidenced by the fractional shortening measurement and subjective evaluation of the different regions of the myocardium. The **left ventricular outflow** tract demonstrated normal laminar flow and subjective structural integrity. The **right atrium** and auricle revealed normal size, structure and content. No evidence of masses was noted or chamber overload. **Tricuspid** valvular assessment demonstrated adequate linear morphology. The **right ventricle** was of normal size (1/3 diameter of LV), chordae structure, myocardial echogenicity and thickness. **Pulmonic** tract assessment revealed normal valve structure, laminar flow, and diameter (approx. 1:1 pa/ao ratio). No visible **pericardial** or free pleura fluid was noted. No echographically detectable evidence of infiltrative disease was visible. The cranial **mediastinum and pericardial regions** were free of masses in the visible window.

WEIGHT

25 kg

INTERPRETED BY

Eric Lindquist, DMV
DABVP, Cert. IVUSS

IMAGING PERFORMED BY

Dr. Belan

HOSPITAL NAME

Signal Hill AH

REFERRING VET

Dr. Lebouldus

INVOICE

30911

DATE

6/7/22

CANINE	MR	TR	LA/AO	LA/AO	FS	EF	EPSS
CARDIAC PARAMETERS	VMAX (m/s)	VMAX (m/s)	(Boon method)	(Heart Base; Swe)	(%)	(%)	(cm)
NORMAL PARAMETER	4.5-5.5	<2.7	1.3	<1.3	28-40	40-100	<0.6
PATIENT	5.76		1.35	1.4	42	73	0.3
CANINE	HR	AV	PV	BODY WEIGHT	LA	LVIDd	LVIDs
CARDIAC PARAMETERS	(BPM)	VMAX (m/s)	MAX (m/s)	(kg)	2D short axis Base view (cm)	Avg; 2D and m-mode short axis (cm)	Avg; 2D and m-mode short axis (cm)
NORMAL PARAMETER	50-100	0.7-1.7	0.7-1.6				
PATIENT		1.4	0.97	25 kg	4.7 max	4.87	



PATIENT

Skye Brawn Henderson

ULTRASONOGRAPHIC FINDINGS

Right pancreatic nodule/mass. Necrosis versus carcinoma.

SPECIES

Canine

Otherwise, unremarkable abdomen.

BREED

Airedale Terrier

Stage B1 valvular disease.

INTERPRETATION OF THE FINDINGS & FURTHER RECOMMENDATIONS

FNA of the pancreatic nodule is recommended for further definition. This appears resectable.

SEX

Spayed Female

No cardiac therapy is recommended at this time.

AGE

10 years

B1: The heart is stable without clinical disease. No overt contraindication for anesthesia of brief to moderate duration. I suggest Torbutrol premed, Propofol induction, Isoflurane maintenance or similar protocol if anesthesia is desired. Blood pressure recommended if not already performed and target white coat negative systolic pressure of < 160 mmHg. If higher than this ACE-inhibitor is suggested to reach this level. Recheck echocardiogram is recommended in 6 months, earlier if murmur grade increases or clinical signs initiate.

WEIGHT

25 kg

INTERPRETED BY

Eric Lindquist, DMV
DABVP, Cert. IVUSS

IMAGING PERFORMED BY

Dr. Belan

HOSPITAL NAME

Signal Hill AH

REFERRING VET

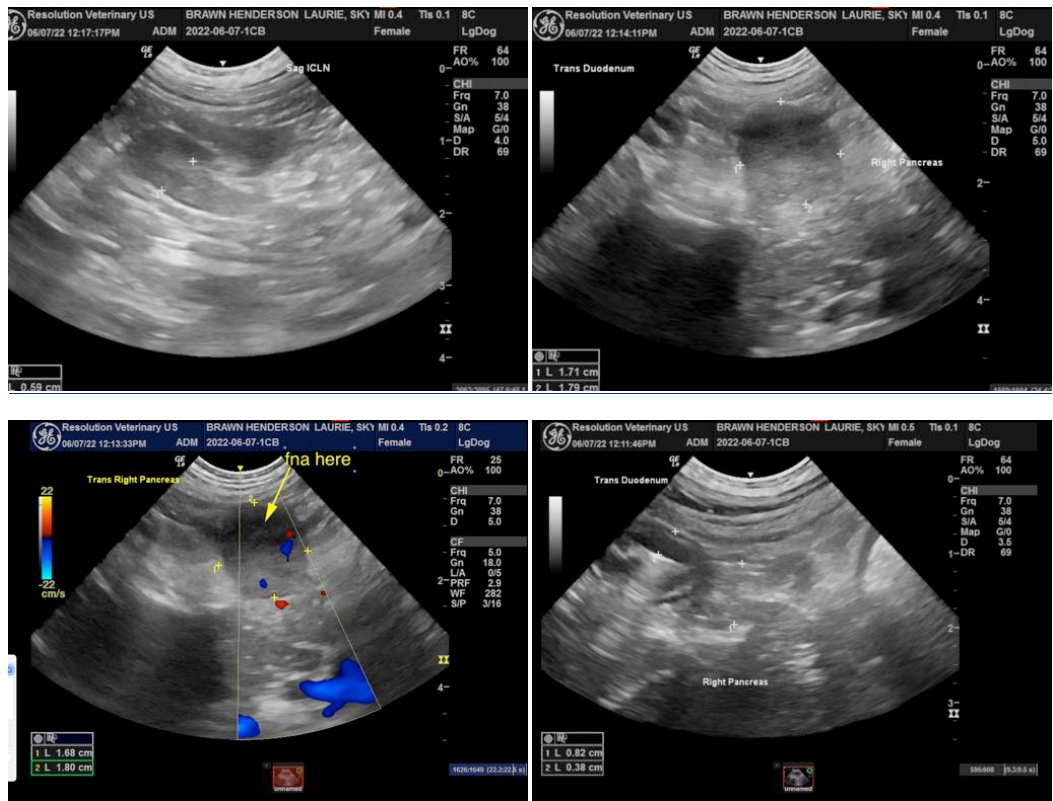
Dr. Lebouldus

INVOICE

30911

DATE

6/7/22





PATIENT

Skye Brawn Henderson

SPECIES

Canine

BREED

Airedale Terrier

SEX

Spayed Female

AGE

10 years

WEIGHT

25 kg

INTERPRETED BY

Eric Lindquist, DMV
DABVP, Cert. IVUSS

IMAGING PERFORMED BY

Dr. Belan

HOSPITAL NAME

Signal Hill AH

REFERRING VET

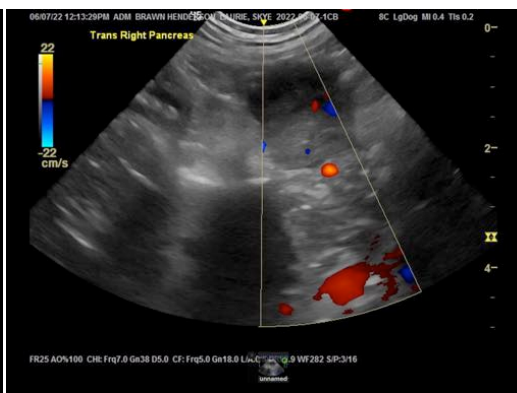
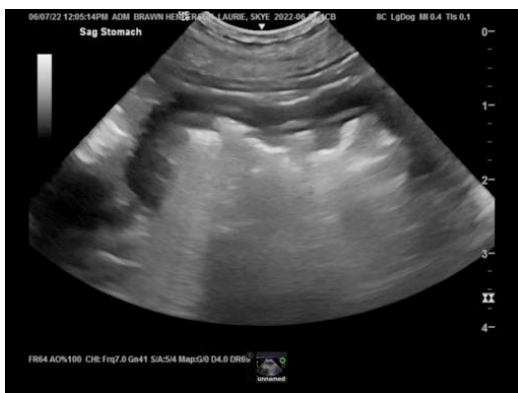
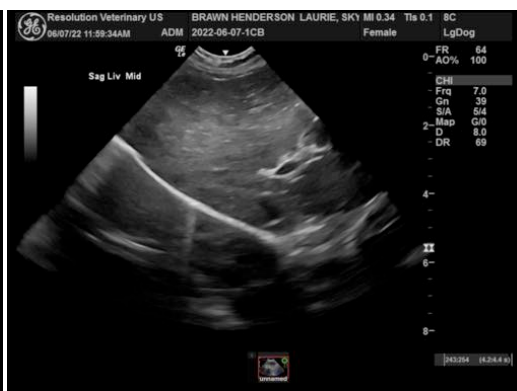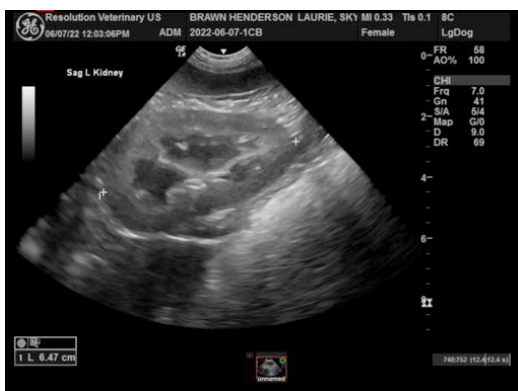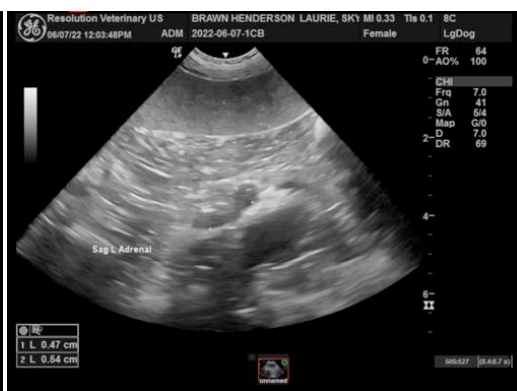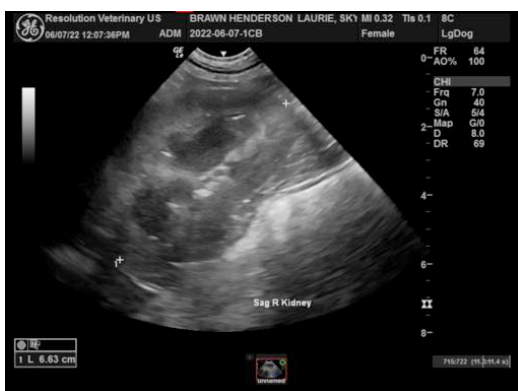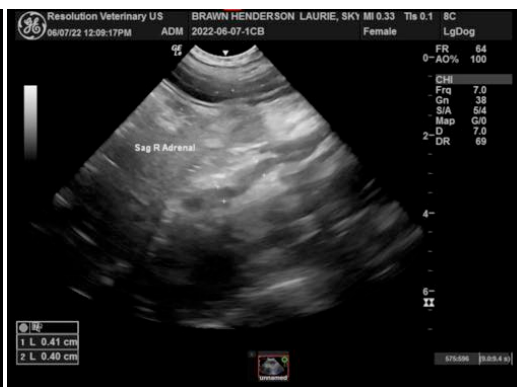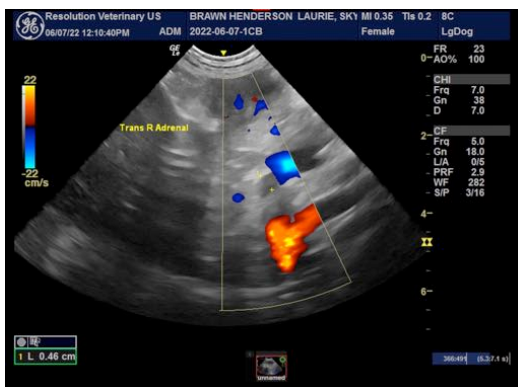Dr. Lebouldus

INVOICE

30911

DATE

6/7/22





PATIENT

Skye Brawn Henderson

SPECIES

Canine

BREED

Airedale Terrier

SEX

Spayed Female

AGE

10 years

WEIGHT

25 kg

INTERPRETED BY

Eric Lindquist, DMV
DABVP, Cert. IVUSS

IMAGING PERFORMED BY

Dr. Belan

HOSPITAL NAME

Signal Hill AH

REFERRING VET

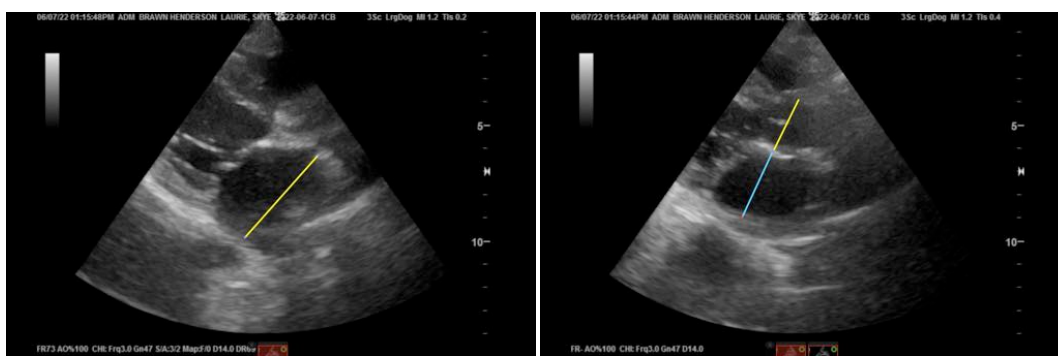
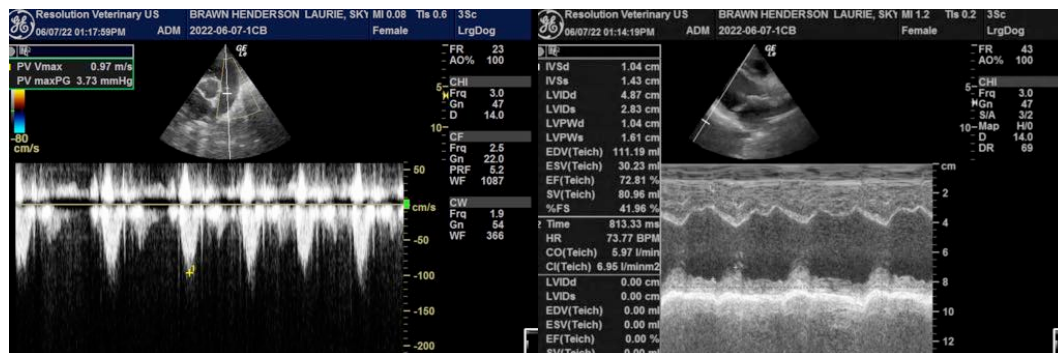
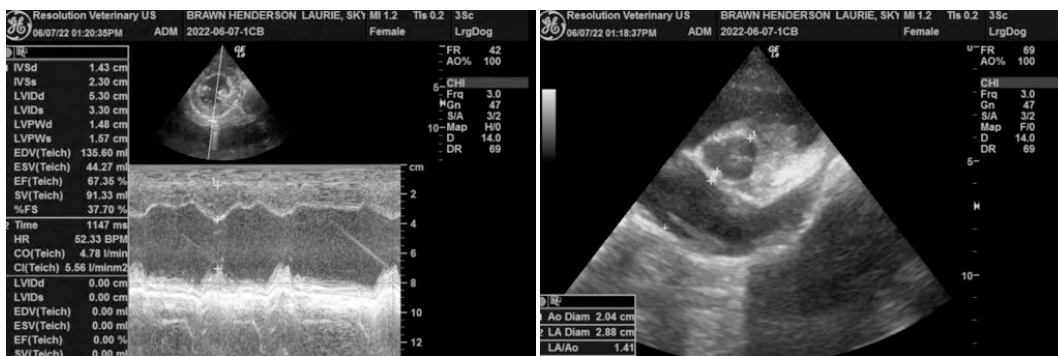
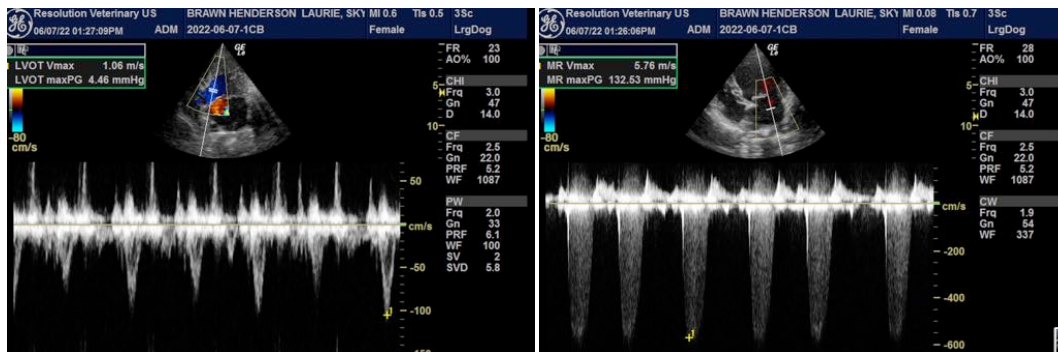
Dr. Lebouldus

INVOICE

30911

DATE

6/7/22





PATIENT

Skye Brawn Henderson

SPECIES

Canine

BREED

Airedale Terrier

SEX

Spayed Female

AGE

10 years

WEIGHT

25 kg

INTERPRETED BY

Eric Lindquist, DMV
DABVP, Cert. IVUSS

**IMAGING
PERFORMED BY**

Dr. Belan

HOSPITAL NAME

Signal Hill AH

REFERRING VET

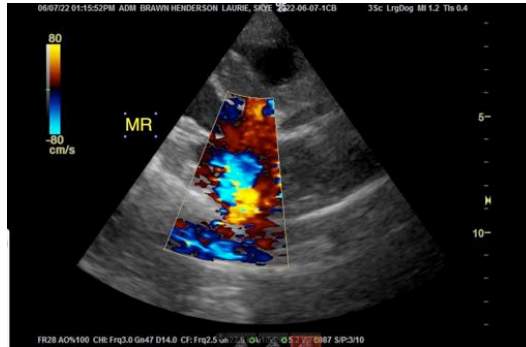
Dr. Lebouldus

INVOICE

30911

DATE

6/7/22



The information and recommendations provided are based on the images presented by the referring veterinarian/sonographer. No evaluation can be communicated regarding pathology that was not visible in the image/video clips provided.

Thank you for this referral. If the clinical or image interpretation does not parallel your findings or if I can be of any further assistance please contact me.

Eric Lindquist, DMV, DABVP, Cert. IVUSS, CEO of SonoPath.com
info@SonoPath.com