

IMAGING PERFORMED BY

IntraPet.com



**SonoPath**

Clinical Sonography & Telecytology

EDUCATIONAL TELECONSULTATION SERVICES™

1-800-838-4268 info@sonopath.com SonoPath.com

**DATE**

6/7/22

**PATIENT**

Kai Nechay

**SPECIES**

Canine

**BREED**

Portugese Water Dog

**SEX**

Neutered Male

**AGE**

5/25/12

**WEIGHT**

45 Pounds

**INTERPRETED BY**

Eric Lindquist, DMV  
DABVP, Cert. IVUSS

**IMAGING PERFORMED BY**

Stephanie Pearce  
RDMS, RVT

**HOSPITAL NAME**

Hickory Vet Hospital

**REFERRING VET**

Dr. Silcox

**INVOICE**

38480

**PRESENTING CLINICAL SIGNS**

HX of daily vomiting for 6 weeks. Seen at AEH 4/19/2022 - Exam, radiographs and labs pointed to gastritis. Did not improve after overnight treatment per owner. Seen at Hickory Veterinary Hospital on 5/25 for continued vomiting. Patient BAR with good energy and appetite per owner. Vomiting happens during the day. Usually just bile, not food. Current on Heartgard once a month. Lost 5 lbs since april. Fecal negative and cPL normal. Has responded to 4 day treatment of cerenia and long term OTC prilosec. No more vomiting.

Current Medications: 20mg Omeprazole QD Current, 60mg Cerenia - recently finished.  
Date of Previous IntraPet Ultrasound: No previous.  
Sedation: Dexdomitor IM.  
Stat Report: Not requested.

**ULTRASONOGRAPHIC EXAMINATION OF THE ABDOMEN**

**Urinary System**

The **urinary bladder**, trigone, and pelvic urethra presented normal thicknesses and normal tone. The ureters were not visible which is normal. No uroliths or sediment were visualized and anechoic urine was present. No evidence of inflammatory or neoplastic changes were noted. Ureteral papillae were normal.

The residual prostate was uniform at 1.19 cm.

The **kidneys** revealed largely normal size and structure, corticomedullary definition and ratio (cortex 1/3 of medulla) were essentially maintained with some age-related loss of curvilinear patterns regarding the capsule and C/M junction. The cortices presented largely uniform texture with some increased echogenicity expected for his age patient. Medullary structure differed distinctly from that of the cortex and no evidence of pelvic dilation was present. The right kidney measured 5.34 cm. The left kidney measured 5.46 cm.

**Adrenal Glands**

Both **adrenal glands** were visualized and recognized as having largely normal shape, size, position and acceptable echogenicity for this age group and breed. Some heterogeneity was noted within the adrenal parenchyma without concerning capsular distortion. These changes are likely age related but should be monitored by sonogram should the patient be suspected of having adrenal disease. The right adrenal gland measured 2.74 cm x 0.73 cm at the caudal pole and 0.74 cm at the cranial pole. The left adrenal gland measured 2.41 cm x 0.68 cm at the caudal pole and 0.66 cm at the cranial pole.

**Spleen**

The **spleen** presented a smooth homogeneous parenchyma hyperechoic to liver and renal cortical parenchyma. The spleen was folded upon itself caudally, positional variant. The capsule was smooth without noticeable expansion or deviation from within the spleen or adjacent pathology. The splenic vasculature demonstrated normal volume without signs of congestion or thrombosis. No sonographic evidence of acute or chronic inflammatory, neoplastic, or infarctual changes were noted.

**Liver**

The **liver** images submitted revealed subjectively normal liver size, contour, and structure. Parenchymal echogenicity was naturally coarse and hypoechoic to the spleen. The gallbladder presented acceptably thin walls with primarily anechoic content. The cystic and common bile ducts were normal. No pathological hepatic lymphadenopathy was evident. No overt structural evidence of inflammatory, infiltrative or regenerative pathology was evident.

Hepatic veins were mild to moderately dilated. The vena cava was dilated at 1.72 cm. Echocardiogram and thoracic workup recommended to assess for causes of passive congestion.

### ***Gastrointestinal***

Examination of the **gastrointestinal tract** revealed a stomach and intestine free of stasis, of normal wall thickness, acceptable curvilinear mural detail, and peristaltic activity. Small and large intestine demonstrated normal luminal chyme and stool consistency respectively. No obstructive or overt infiltrative disease was noted. The ileocecal junction revealed lymph node enlargement of 3.0 cm. Length to width ratio was maintained. However, I'm concerned for round cell neoplasia. FNA indicated. Other separate lymph nodes also enlarged.

### ***Pancreas***

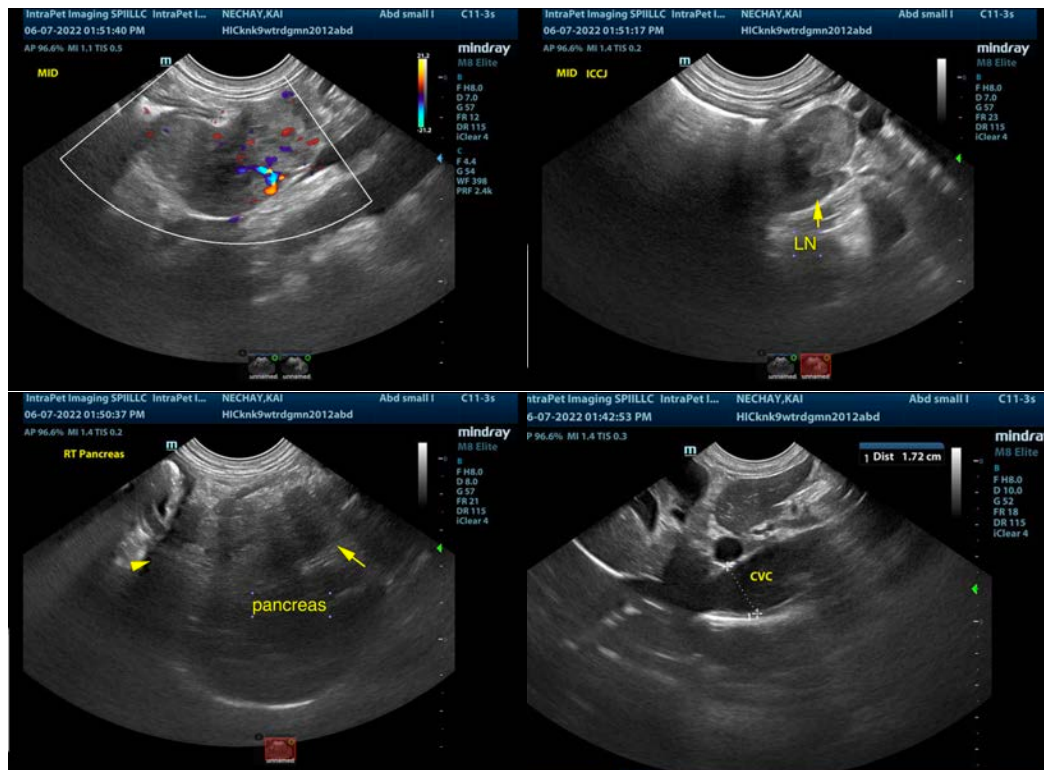
The **pancreas** was irregular and enlarged with undulating contour. Subxiphoid palpation is recommended to assess for pain or discomfort associated with the pancreas.

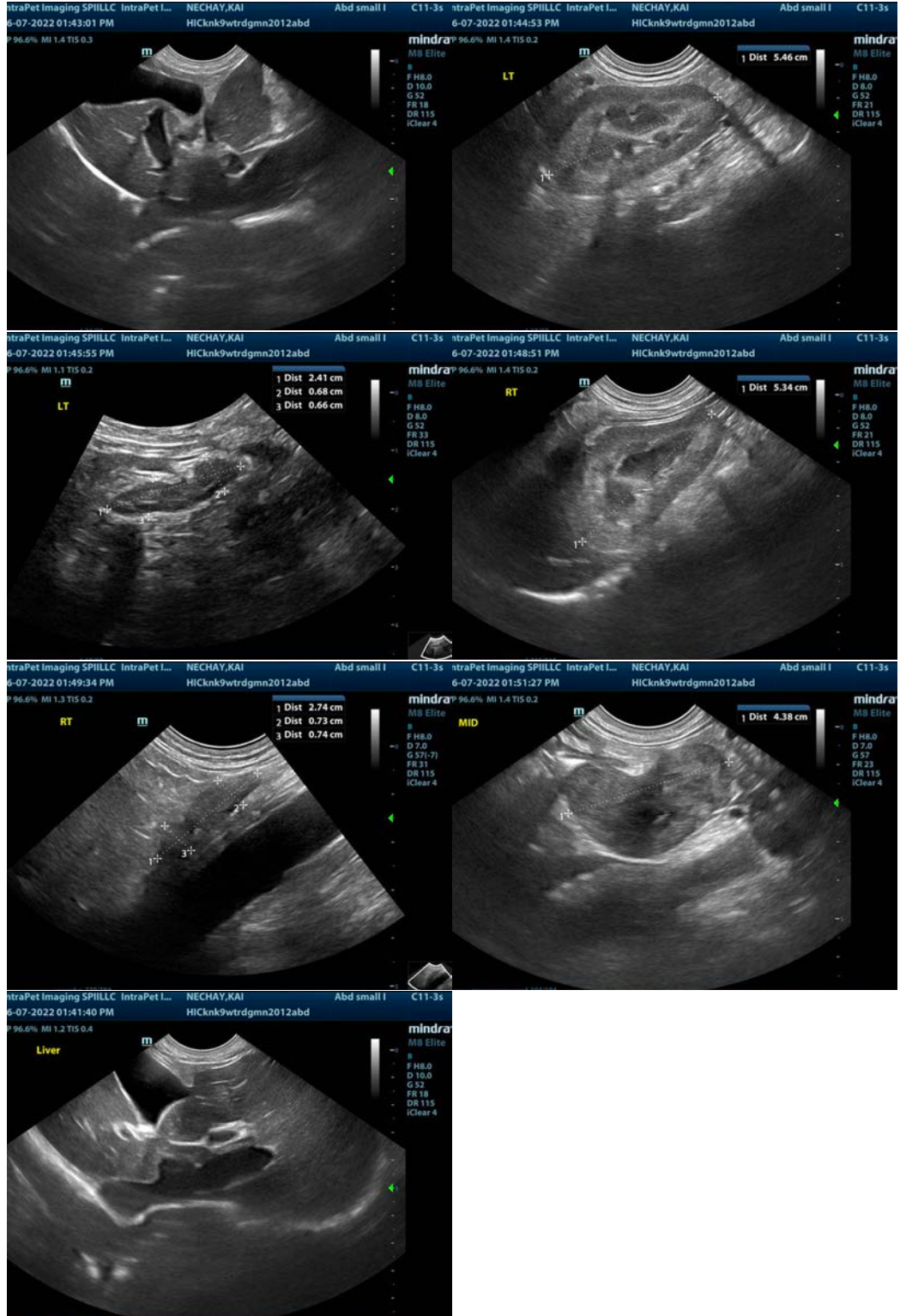
### **ULTRASONOGRAPHIC FINDINGS**

- Passive congestion liver pattern – possibly owing to sedation if Dexdomitor was utilized.
- Possible low-grade pancreatitis, chronic active form.
- Mesenteric lymphadenopathy

### **INTERPRETATION OF THE FINDINGS & FURTHER RECOMMENDATIONS**

Given the excessive vascularity with the mesenteric lymph nodes, coagulation panel recommended prior to 25-gauge FNA.





**The information and recommendations provided are based on the images presented by the referring veterinarian/sonographer. No evaluation can be communicated regarding pathology that was not visible in the image/video clips provided.**

Thank you for this referral. If the clinical or image interpretation does not parallel your findings or if I can be of any further assistance please contact me.

**Eric Lindquist**, DMV, DABVP, Cert. IVUSS, CEO of SonoPath.com  
[info@SonoPath.com](mailto:info@SonoPath.com)