



PATIENT

Henry Ziegler

SPECIES

Canine

BREED

Shepherd Mix

SEX

Neutered male

AGE

5 years

WEIGHT

51.2 lbs

INTERPRETED BY

Eric Lindquist, DMV
DABVP, Cert. IVUSS

IMAGING PERFORMED BY

Dr. Beard

HOSPITAL NAME

Animal Care VC

REFERRING VET

Dr. Hartman

INVOICE

30895

DATE

6/7/22

PRESENTING CLINICAL SIGNS

History: Weight loss and anorexia since about January.

Abnormal PE/Chem/CBC/UA Results: Areas of dullness in the cranial thorax. Heart sounded normal. CBC is unremarkable. Chemistry has low BUN. Survey radiographs revealed a cranial thoracic mass on VD, looks mostly on R side. Trachea is pushed up to the spine.

ULTRASONOGRAPHIC EXAMINATION

The liver revealed passive congestion pattern. The gallbladder presented acceptably thin walls with primarily anechoic content. The cystic and common bile ducts were normal.

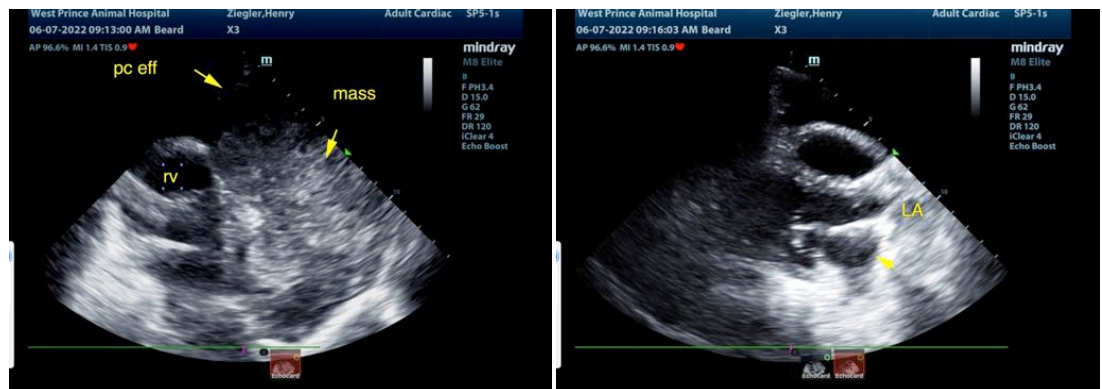
Pleural effusion was noted through the diaphragm as well as mild pericardial effusion and a large space occupying mass that impinged upon the heart as well as nodular pleural changes. The parenchymal portion of the mass measured approximately 10 cm and was surrounded by a cystic area. This does not appear resectable.

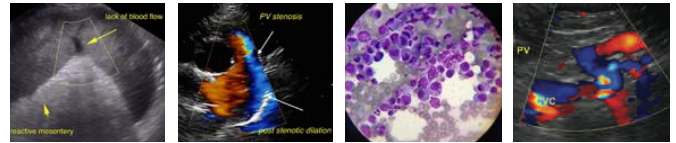
ULTRASONOGRAPHIC FINDINGS

Large space occupying mass impinging on the heart with nodular pleural changes.

INTERPRETATION OF THE FINDINGS & FURTHER RECOMMENDATIONS

CT evaluation could be considered for further definition. Ultrasound-guided FNA of the parenchymal portion of the mass as well as pleurocentesis and cytospin could be considered for further definition of neoplastic type. In addition radiation and/or chemotherapy may be palliative. Full abdominal sonogram is recommended to assess concurrent lesions in the abdomen related to the mass. The mass appears to be likely lymph node in origin. However, some lung and pleural involvement appeared to be an issue as well.





PATIENT

Henry Ziegler

SPECIES

Canine

BREED

Shepherd Mix

SEX

Neutered male

AGE

5 years

WEIGHT

51.2 lbs

INTERPRETED BY

Eric Lindquist, DMV
DABVP, Cert. IVUSS

IMAGING PERFORMED BY

Dr. Beard

HOSPITAL NAME

Animal Care VC

REFERRING VET

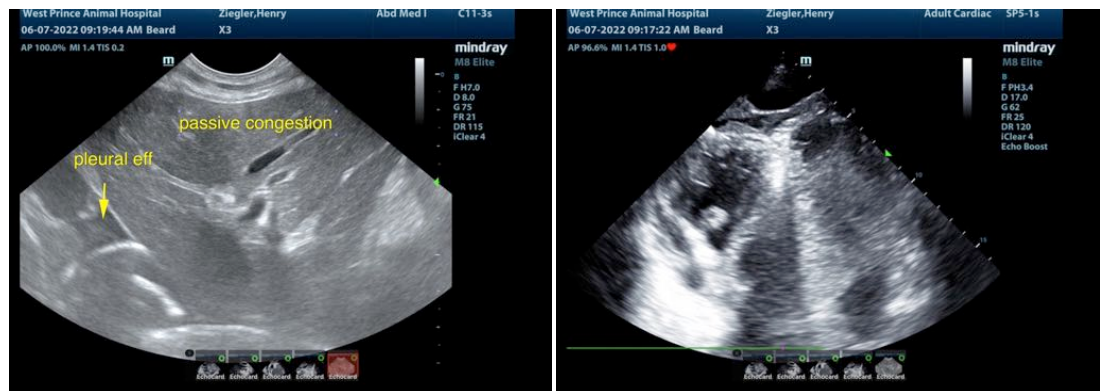
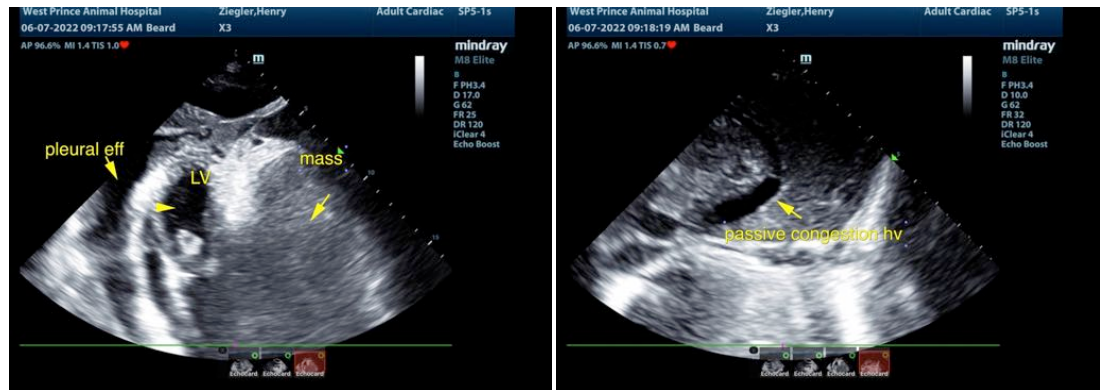
Dr. Hartman

INVOICE

30895

DATE

6/7/22



The information and recommendations provided are based on the images presented by the referring veterinarian/sonographer. No evaluation can be communicated regarding pathology that was not visible in the image/video clips provided.

Thank you for this referral. If the clinical or image interpretation does not parallel your findings or if I can be of any further assistance please contact me.

Eric Lindquist, DMV, DABVP, Cert. IVUSS, CEO of SonoPath.com
info@SonoPath.com