



DATE PRESENTING CLINICAL SIGNS

6/5/26 **Patient History:** Anorexia, not drinking, lethargy, tremors/shaking/trembling, fever (unknown origin), abnormal behavior.

PATIENT

Mr. Tom Merrill **Current Medications:** Ondansetron, Maropitant, Buprenorphine, Gabapentin.
Labwork Results: Labwork submitted. Reported as

SPECIES

Feline

-CBC on 6/1 at Parkville: PCV 29% (reference range 30-55%)
-CBC on 6/3: PCV 29%
-Abdominal radiographs on 6/2: No evidence of foreign body or obstruction, small amount of gas in colon
-Kidney values normal on 6/2

BREED

DSH

Date of Previous IntraPet Ultrasound: No previous.
Sedation: Not required to complete full diagnostic ultrasound.
Stat Report: Requested.
Imaging Performed by: Andi Parkinson, BS, RDMS.

SEX

Neutered Male

ULTRASONOGRAPHIC EXAMINATION OF THE ABDOMEN

AGE

5/31/21

Urinary System

The **urinary bladder**, trigone, and pelvic urethra presented normal thicknesses and normal tone. The ureters were not visible which is normal. No uroliths or sediment were visualized and anechoic urine was present. No evidence of inflammatory or neoplastic changes were noted. Ureteral papillae were normal.

WEIGHT

17.8 lbs

The **right kidney** revealed normal size and structure, corticomedullary definition and ratio for this age. The cortex presented largely uniform texture with normal echogenic relationship to liver and spleen. Medullary structure differed distinctly from the cortex and no evidence of pelvic dilation was present. The capsule was acceptably uniform without significant irregularities. Right kidney measured 4.88 cm.

INTERPRETED BY

Eric Lindquist, DMV,
DABVP, Cert. IVUSS

The **left kidney** presented cortical infarct and collapse at the cranial pole. Slight pyelectasia and areas of mineralization noted. Left kidney measured 4.9 cm. Regional mild inflammatory pattern noted.

HOSPITAL NAME

Animal Emergency
Hospital

Adrenal Glands

Both **adrenal glands** were visualized and recognized as having normal shape, size, position and echogenicity for this breed. The phrenic vasculature, glandular echogenicity and detail were unremarkable. Capsule, cortex, and medullary definition were normal for this age patient. Left measured 0.53 cm. Right measured 0.48 cm.

REFERRING VET

Dr. Rodriguez

Spleen

The **spleen** was mildly enlarged at 1.7 cm, unremarkable otherwise.

INVOICE

75745

Liver

The **liver** images submitted revealed subjectively normal liver size, contour, and structure. Parenchymal echogenicity was naturally coarse and hypoechoic to the spleen. Vascular and biliary tracts were of normal volume with no evidence of congestion. The gallbladder presented acceptably thin walls with primarily anechoic content. The cystic and common bile ducts were normal. No pathological hepatic lymphadenopathy was evident. No overt structural evidence of inflammatory, infiltrative or regenerative pathology was evident.

Gastrointestinal

Examination of the **gastrointestinal tract** revealed a stomach and intestine free of stasis, of normal wall thickness, acceptable curvilinear mural detail, and peristaltic activity. Small and large intestine demonstrated normal luminal chyme and stool consistency respectively. No obstructive or overt infiltrative disease was noted. No associated abnormal lymphatic activity was noted.

Pancreas

The **pancreas** was mildly hypoechoic with slight undulating contour, measuring 0.80 cm in width.

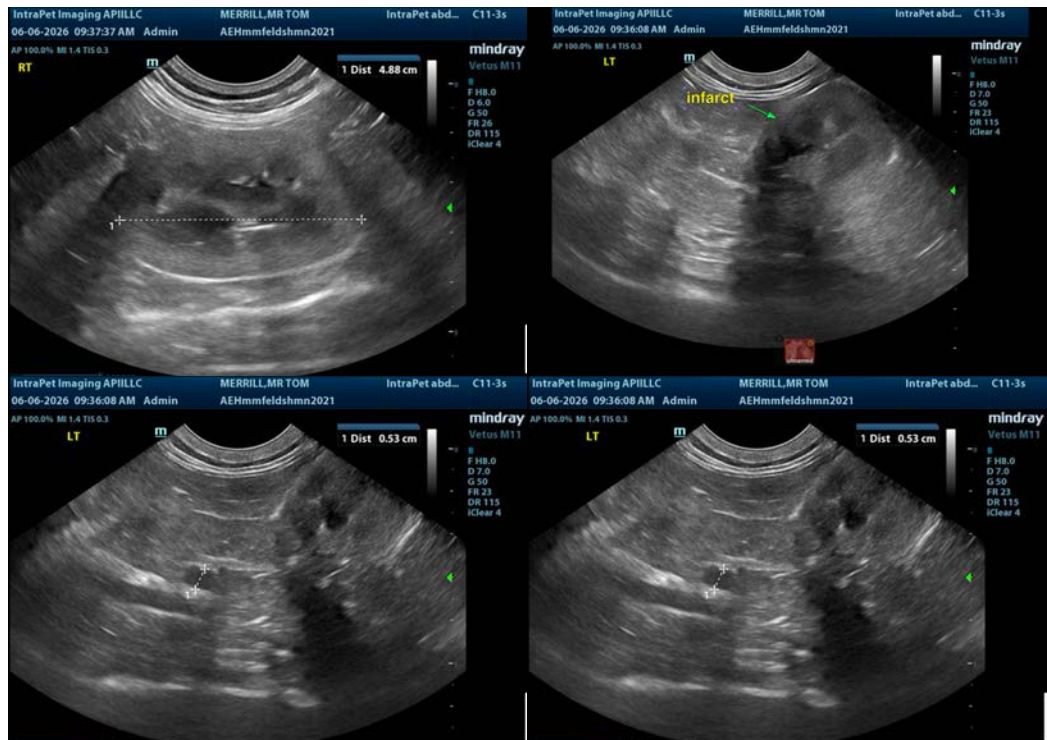
ULTRASONOGRAPHIC FINDINGS

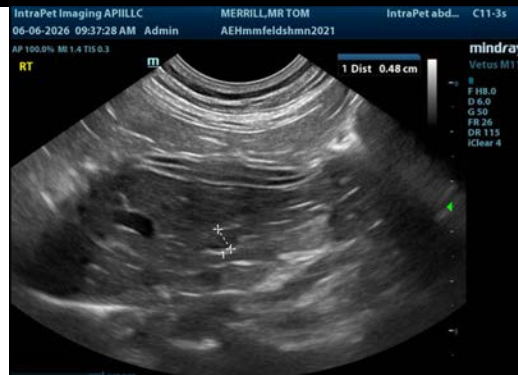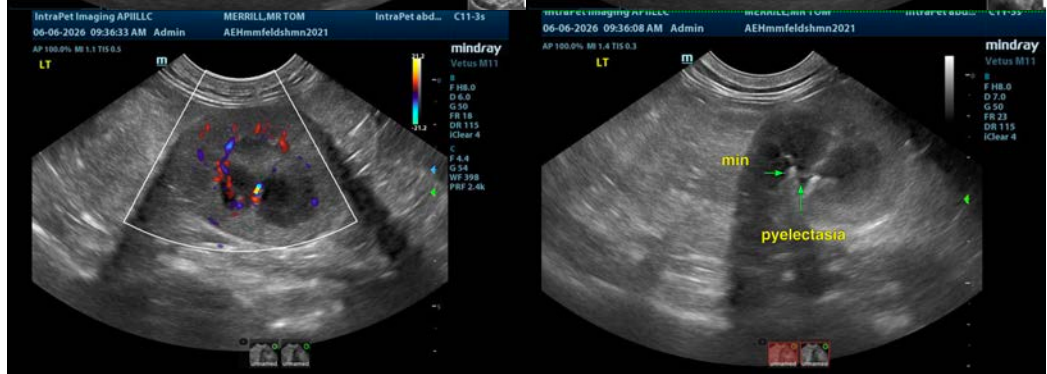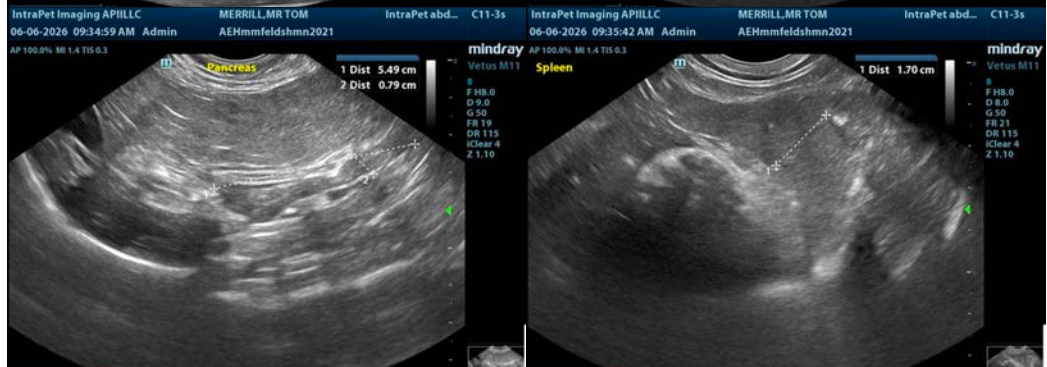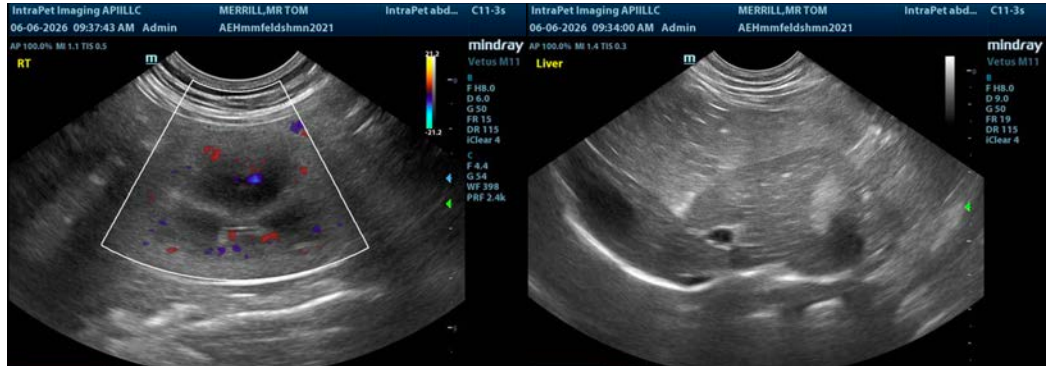
- Prominent pancreas.
- Enlarged spleen.
- Left renal infarct and low-grade nephritis pattern.

INTERPRETATION OF THE FINDINGS & FURTHER RECOMMENDATIONS

Non-specific presentation. Given elevated globulins and anemia, FNA of the spleen and CBC path review indicated. Bartonella and toxoplasmosis titers indicated.

The patient may be moving calculi periodically. Manual palpation of the left kidney indicated to assess for any discomfort.





The information and recommendations provided are based on the images presented by the referring veterinarian/sonographer. No evaluation can be communicated regarding pathology that was not visible in the image/video clips provided.

Thank you for this referral. If the clinical or image interpretation does not parallel your findings or if I can be of any further assistance please contact me.

Eric Lindquist, DMV, DABVP(CFM), Cert. IVUSS,
CEO, Owner, Founder -- SonoPath.com
info@SonoPath.com

**Excerpt from the Curbside Guide: <https://sonopath.com/thecurbsideguide/>
FEVER OF UNKNOWN ORIGIN**

DESCRIPTON Fever of unknown origin (FUO) is any fever greater than a few days duration in which the cause is not obvious on initial history and physical examination. Important etiologies are infectious disease, immune-mediated diseases, and neoplasia. The common causes of FUO were summarized concisely in a presentation at the American College of Veterinary Internal Medicine 2004 Forum as follows:

Final Diagnosis	Bennett (Dogs & Cats)	Dunn and Dunn (Dogs Only)	Lunn (Dogs & 1 cat)	Total	Percent
Infection	21	16	10	47	28
Immune	18	22	6	46	27
Bone Marrow Disease	4	22	2	28	16
Neoplasia (outside marrow)	0	10	2	12	7
Miscellaneous	2	12	2	16	9
No Diagnosis	0	19	2	21	12
TOTALS	45	101	24	170	99

The types of infection diagnosed in this case series were varied, ranging from discospondylitis (8 cases), blastomycosis (6 cases), and bacterial endocarditis (4 cases), to leishmaniasis (1 case), prostatitis (1 case), and Ehrlichia canis infection (1 case); a multitude of other infectious causes also fell within the spectrum. Of the cases where immune-mediated disease was found, 44% had immune-mediated polyarthritis. Bone marrow diseases included myeloproliferative disease, myelodysplasia (8 cases), lymphocytic leukemia (8 cases), myeloma (3 cases), chronic granulocytic leukemia (3 cases), lymphoblastic leukemia, and malignant histiocytosis. The types of neoplasia located outside the bone marrow included lymphoma (6 cases), metastatic disease (2 cases), and neoplasms of the lung, spleen, and stomach. Finally, miscellaneous diseases included hypertrophic osteodystrophy (6 cases), meningitis (3 cases), portosystemic shunt (3 cases), lymphadenitis (2 cases), panosteitis, and intervertebral disc disease. Overall, the most common causes across all cases were polyarthritis (44 cases), lymphoid neoplasia (15 cases), discospondylitis (8 cases), myelodysplasia (8 cases), hypertrophic osteodystrophy (6 cases), and blastomycosis (6 cases).

CLINICAL SIGNS Animals usually present with either persistent or waxing and waning fevers ranging from 103–106 °F (39.5–41 °C). Other clinical signs depend on the underlying cause of the fever. Careful and thorough physical examination is required to assess potential causes. History and physical examination represent the first, best, and least expensive opportunity to localize the disease process causing the fever.

DIAGNOSTICS FUO etiologies are partly related to geography and thus, locale or travel history should factor into a practitioner's diagnostic approach. A patient's lifestyle may also provide clues regarding exposure to certain etiologic agents. Therefore, obtaining a thorough history can unveil important pieces of the diagnostic puzzle. Physical examination is especially important and should include an inspection of all accessible lymph

nodes, palpation and movement of the joints, a fundic examination, a neurological evaluation, spinal and limb palpation and range of motion tests, and a rectal examination.

A minimum database should include a CBC reviewed by a clinical pathologist, as well as a biochemical profile and urinalysis and retroviral testing in cats. In areas where tick-borne disease is prevalent, in-house testing should be performed early. Advanced laboratory work can include urine culture, blood culture, and infectious disease panels (PCR and/or serology). In dogs, one may screen for the following infectious agents: Ehrlichia spp., Borrelia burgdorferi, Rocky Mountain Spotted Fever, Bartonella spp. (culture and PCR), and Leptospira spp. in cases of hepatic or renal involvement. In cats, one should evaluate for FeLV, FIV, feline infectious peritonitis (FIP) virus, toxoplasmosis, Hemoplasma spp. (Mycoplasma), and Bartonella spp. (culture and PCR). Testing for Ehrlichia spp., Rickettsia spp., and Anaplasma phagocytophilum can also be considered. A fungal assay is indicated if the patient lives in or has had exposure to a region with a higher incidence of fungal disease. Other infectious disease tests may be performed depending on the geographical location of the pet. Screening for Brucella should be done in breeding dogs. Immune-mediated disease screening can include a Coombs test, a slide agglutination test (if the patient is anemic), and an antinuclear antibody (ANA) test. Immune disease is often a diagnosis of exclusion.

Imaging should include thoracic radiographs, abdominal ultrasound, and/or abdominal radiographs. Ultrasound can be very useful for assessing evidence of cholangiohepatitis, pyelonephritis, chronic urinary tract infection, abscess formation, peritonitis, and neoplasia. It also permits an examination of the intra-abdominal lymph nodes. An echocardiogram can offer assessment for vegetative endocarditis, whereas spinal radiographs offer assessment for discospondylitis. In cases where all other testing has proven negative and the patient has not responded to broad-spectrum antibiotics and supportive care, arthrocentesis should be considered to evaluate for septic joint disease, immune-mediated polyarthritis, and infectious disease. Finally, one can consider assessing the cerebrospinal fluid for meningoencephalitis, GME, and meningitis/arteritis. A bone marrow exam should be performed if blood dyscrasias are noted on the CBC.

TREATMENT Treatment of the fever depends entirely on the underlying cause. Ideally, a thorough diagnostic plan will yield a diagnosis that will guide the appropriate therapeutic course. However, if an exhaustive approach has not produced a definitive diagnosis and there is no response to broad-spectrum antibiotics, trial therapy with immunosuppressive agents such as prednisolone can be considered to treat presumed immune-mediated diseases. Given the potential for negative sequelae should an underlying infection be present, one must be certain that the investigation is thorough and monitor the patient's response carefully.

CONCLUSION If a documented fever has not responded to antibiotics, antipyretics, or general nursing care, it is important to obtain a diagnosis to guide more specific treatment. A systematic physical examination and thorough history-taking will help inform further diagnostics in addition to what is revealed by the minimum database.

REFERENCES

1. Battersby IA, Murphy KF, et al. Retrospective study of fever in dogs: laboratory testing, diagnoses and influence of prior treatment. *J Small Anim Pract.* 2006; 47: 370-376.
2. Flood J. The diagnostic approach to fever of unknown origin in cats. *Compend Contin Educ Vet* 2009; 31 (1): 26-31.
3. Flood J. The diagnostic approach to fever of unknown origin in dogs. *Compend Contin Educ Vet* 2009; 31 (1): 14-21.
4. Lappin MR. The role of blood borne pathogens in feline fever of unknown origin. *Proceedings from the American College of Veterinary Internal Medicine, Denver, CO, June 15–18, 2011.*
5. Lunn KF. Fever of unknown origin: a systematic approach to diagnosis. *Compend Contin Educ Vet* 2001; 23 (11): 976-92.

6. Lunn KF. Fever of unknown origin: appropriate choice of diagnostic tests. Proceedings from the American College of Veterinary Internal Medicine, Minneapolis, MN, June 9–12, 2004.