



PATIENT

Coco Abel

SPECIES

Canine

BREED

Lab

SEX

Spayed Female

AGE

12

WEIGHT

90

INTERPRETED BY

Eric Lindquist, DMV,
DABVP(CFM), Cert.
IVUSS

IMAGING PERFORMED BY

Jenn

HOSPITAL NAME

Rockaway Animal
Hospital

REFERRING VET

Dr. Brooks

INVOICE

16386

DATE

06/06/26

PRESENTING CLINICAL SIGNS

Acute vomiting, decreased appetite, r/o pancreatitis gastritis, dietary indiscretion, increased liver enzymes r/o hepatitis, toxic hepatopathy, neoplasia, chronic appetite decreased appetite for 3 months R/O dental dz, pancreatitis, hepatic dz, multiple SQ masses Current meds Denamarin 425mg 2 tabs BID

Abnormal PE/Chem/CBC/UA Results: ALT 307 ALP 232 (decreased from 535 in Dec) Baseline Cortisol 5.7 r/o Addisons

ULTRASONOGRAPHIC EXAMINATION OF THE ABDOMEN

Urinary System

The **urinary bladder**, trigone, and pelvic urethra to a depth of 2.0 cm presented normal thicknesses and normal tone. The ureters were not visible which is normal. No uroliths or sediment were visualized, and anechoic urine was present. No evidence of inflammatory or neoplastic changes were noted. Ureteral papillae were normal.

The **kidneys** revealed largely normal size and structure, corticomedullary definition and ratio (cortex 1/3 of medulla) were essentially maintained with some minor age-related loss of curvilinear patterns regarding the capsule and C/M junction. The cortices presented largely uniform texture with some increased echogenicity expected for his age patient. Medullary structure differed distinctly from that of the cortex and no evidence of pelvic dilation was present. The left kidney measured 6.6 cm in length. The right kidney measured 5.7 cm in length.

Adrenal Glands

Both **adrenal glands** were visualized and recognized as having normal shape, upper limits of normal size, position and echogenicity for this breed. The phrenic vasculature, glandular echogenicity and detail were unremarkable. Capsule, cortex, and medullary definition were normal for this age patient. The left adrenal gland measured 2.4 cm x 0.9 cm width at the cranial pole and 0.9 cm width at the caudal pole. The right adrenal gland measured 1.4 cm width at the cranial pole and 0.73 cm width at the caudal pole.

Spleen

The **spleen** was largely smooth with mild heterogeneous parenchymal changes while maintaining normal echogenic relationship to the liver and kidney. These changes are consistent with normal age-related alteration. The capsule was smooth without noticeable impingement from within the spleen or from pathology in the adjacent abdomen. The splenic vasculature demonstrated normal volume without signs of congestion or significant contraction. No evidence of active acute or chronic inflammatory, neoplastic, or infarctual changes was noted.

Liver

The **liver** images from right and left intercostal as well as subcostal views revealed subjectively normal liver size, contour, and structure. Some moderate age-related parenchymal remodeling was noted but likely not clinically significant at this time. Vascular and biliary tracts were of normal volume and no evidence of congestion was noted. The gallbladder presented some dependent debris with essentially normal contour. The cystic and common bile ducts were normal. No overt evidence of active inflammatory, infiltrative or regenerative pathology was noted but should be paired with current or



PATIENT

Coco Abel

SPECIES

Canine

BREED

Lab

SEX

Spayed Female

AGE

12

WEIGHT

90

INTERPRETED BY

Eric Lindquist, DMV,
DABVP(CFM), Cert.
IVUSS

IMAGING PERFORMED BY

Jenn

HOSPITAL NAME

Rockaway Animal
Hospital

REFERRING VET

Dr. Brooks

INVOICE

16386

DATE

06/06/26

past LE elevations regarding any clinical significance to this presentation. The hepatic lymph nodes were unremarkable.

Gastrointestinal

Examination of the **gastrointestinal tract** revealed a stomach and intestine free of stasis, of normal wall thickness, acceptable curvilinear mural detail, and peristaltic activity. Small and large intestine demonstrated normal luminal chyme and stool consistency respectively. No obstructive or overt infiltrative disease was noted. No associated abnormal lymphatic activity was noted.

Pancreas

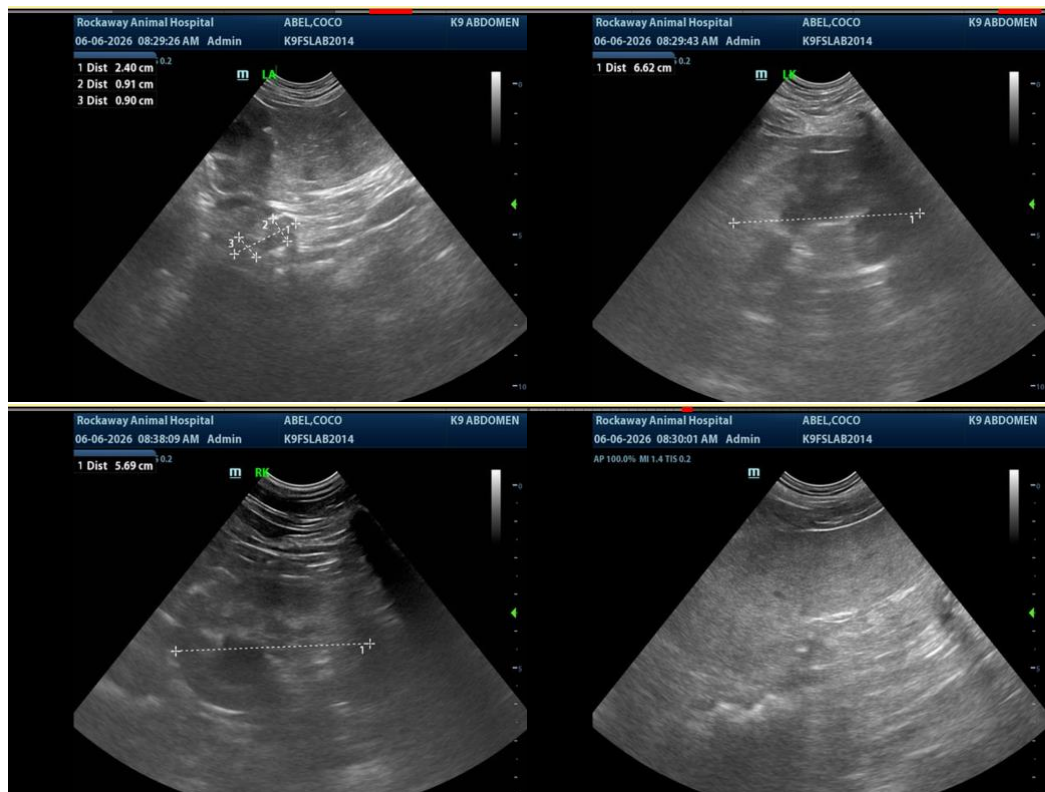
The base and limbs of the **pancreas** were observed to be largely isoechoic to surrounding omental fat. Pancreatic duct and capsular contour were acceptably normal and parenchyma respected normal curvilinear patterns. No overt evidence of active inflammatory or neoplastic disease was noted.

ULTRASONOGRAPHIC FINDINGS

- Age-related abdominal changes.
- Moderate hepatic remodeling.
- Structurally unremarkable GI tract.

INTERPRETATION OF THE FINDINGS & FURTHER RECOMMENDATIONS

No evidence of specific disease. Bile acid profile would be ideal to ensure early dysfunction is not an issue, yet no other evidence of disease.





PATIENT

Coco Abel

SPECIES

Canine

BREED

Lab

SEX

Spayed Female

AGE

12

WEIGHT

90

INTERPRETED BY

Eric Lindquist, DMV,
DABVP(CFM), Cert.
IVUSS

**IMAGING
PERFORMED BY**

Jenn

HOSPITAL NAME

Rockaway Animal
Hospital

REFERRING VET

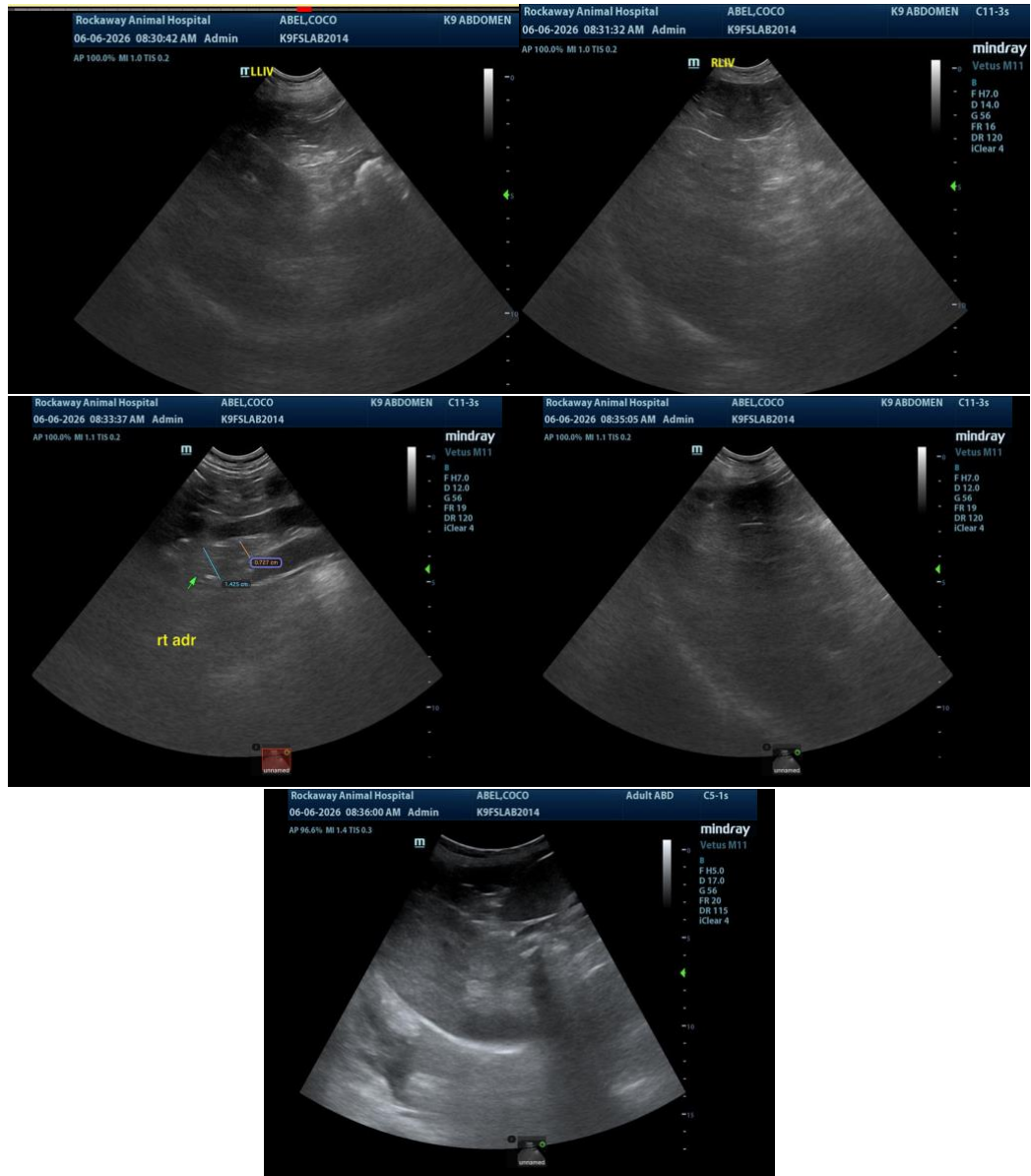
Dr. Brooks

INVOICE

16386

DATE

06/06/26



The information and recommendations provided are based on the images presented by the referring veterinarian/sonographer. No evaluation can be communicated regarding pathology that was not visible in the image/video clips provided.

Thank you for this referral. If the clinical or image interpretation does not parallel your findings or if I can be of any further assistance, please contact me.

Eric Lindquist, DMV, DABVP(CFM), Cert. IVUSS,

CEO, Owner, Founder -- SonoPath.com

info@SonoPath.com



PATIENT

Coco Abel

SPECIES

Canine

BREED

Lab

SEX

Spayed Female

AGE

12

WEIGHT

90

INTERPRETED BY

Eric Lindquist, DMV,
DABVP(CFM), Cert.
IVUSS

IMAGING PERFORMED BY

Jenn

HOSPITAL NAME

Rockaway Animal
Hospital

REFERRING VET

Dr. Brooks

INVOICE

16386

DATE

06/06/26