



PATIENT

Spot Ashman

SPECIES

Feline

BREED

DSH

SEX

Spayed Female

AGE

15 Years

WEIGHT

11.9 lbs

INTERPRETED BY

Eric Lindquist, DMV,
DABVP (CFM), Cert.
IVUSS

IMAGING PERFORMED BY

Chloe Lowe, CVT

HOSPITAL NAME

Animal Hospital of
Sussex County

REFERRING VET

Dr. Lovell

INVOICE

75716

DATE

6/5/26

PRESENTING CLINICAL SIGNS

Assess spleen due to concern on recent in house ultrasound. Clinically WNL.
Abnormal PE/Chem/CBC/UA Results: WNL

ULTRASONOGRAPHIC EXAMINATION OF THE ABDOMEN

Urinary System

The **urinary bladder**, trigone, and pelvic urethra presented normal thicknesses and normal tone. The ureters were not visible which is normal. No uroliths or sediment were visualized and anechoic urine was present. No evidence of inflammatory or neoplastic changes were noted. Ureteral papillae were normal. The pelvic urethra was imaged 2.0 cm beyond the cystourethral junction.

The **kidneys** revealed largely normal size and structure, corticomedullary definition and ratio (cortex 1/3 of medulla) were essentially maintained with some age-related loss of curvilinear patterns regarding the capsule and C/M junction. The cortices presented largely uniform texture with some increased echogenicity expected for his age patient. Medullary structure differed distinctly from that of the cortex and no evidence of pelvic dilation was present. Left kidney measured 3.7 cm. Right kidney measured 3.48 cm with slight pinpoint mineralizations noted.

Adrenal Glands

Both **adrenal glands** were visualized and recognized as having normal shape, size, position and echogenicity for this breed. The phrenic vasculature, glandular echogenicity and detail were unremarkable. Capsule, cortex, and medullary definition were normal for this age patient. Right measured 0.35 cm. Left measured 0.38 cm.

Spleen

The **spleen** was folded upon itself cranially and revealed very subtle hypoechoic nodular changes, non-disruptive. Likely age related changes. Splenic width was normal at 0.86 cm.

Liver

The **liver** images from right and left intercostal as well as subcostal views revealed subjectively normal liver size, contour, and structure. Some age-related parenchymal remodeling was noted but likely not clinically significant at this time. Vascular and biliary tracts were of normal volume and no evidence of congestion was noted. The gallbladder presented some dependent debris with essentially normal contour. The cystic and common bile ducts were normal. No overt evidence of active inflammatory, infiltrative or regenerative pathology was noted but should be paired with current or past LE elevations regarding any clinical significance to this presentation. The hepatic lymph nodes were unremarkable.

Gastrointestinal

Examination of the **gastrointestinal tract** revealed a stomach and intestine free of stasis, of normal wall thickness, acceptable curvilinear mural detail, and peristaltic activity. Small and large intestine demonstrated normal luminal chyme and stool consistency respectively. No obstructive or overt infiltrative disease was noted. No associated abnormal lymphatic activity was noted.



PATIENT

Spot Ashman

SPECIES

Feline

BREED

DSH

SEX

Spayed Female

AGE

15 Years

WEIGHT

11.9 lbs

INTERPRETED BY

Eric Lindquist, DMV,
DABVP (CFM), Cert.
IVUSS

IMAGING PERFORMED BY

Chloe Lowe, CVT

HOSPITAL NAME

Animal Hospital of
Sussex County

REFERRING VET

Dr. Lovell

INVOICE

75716

DATE

6/5/26

Pancreas

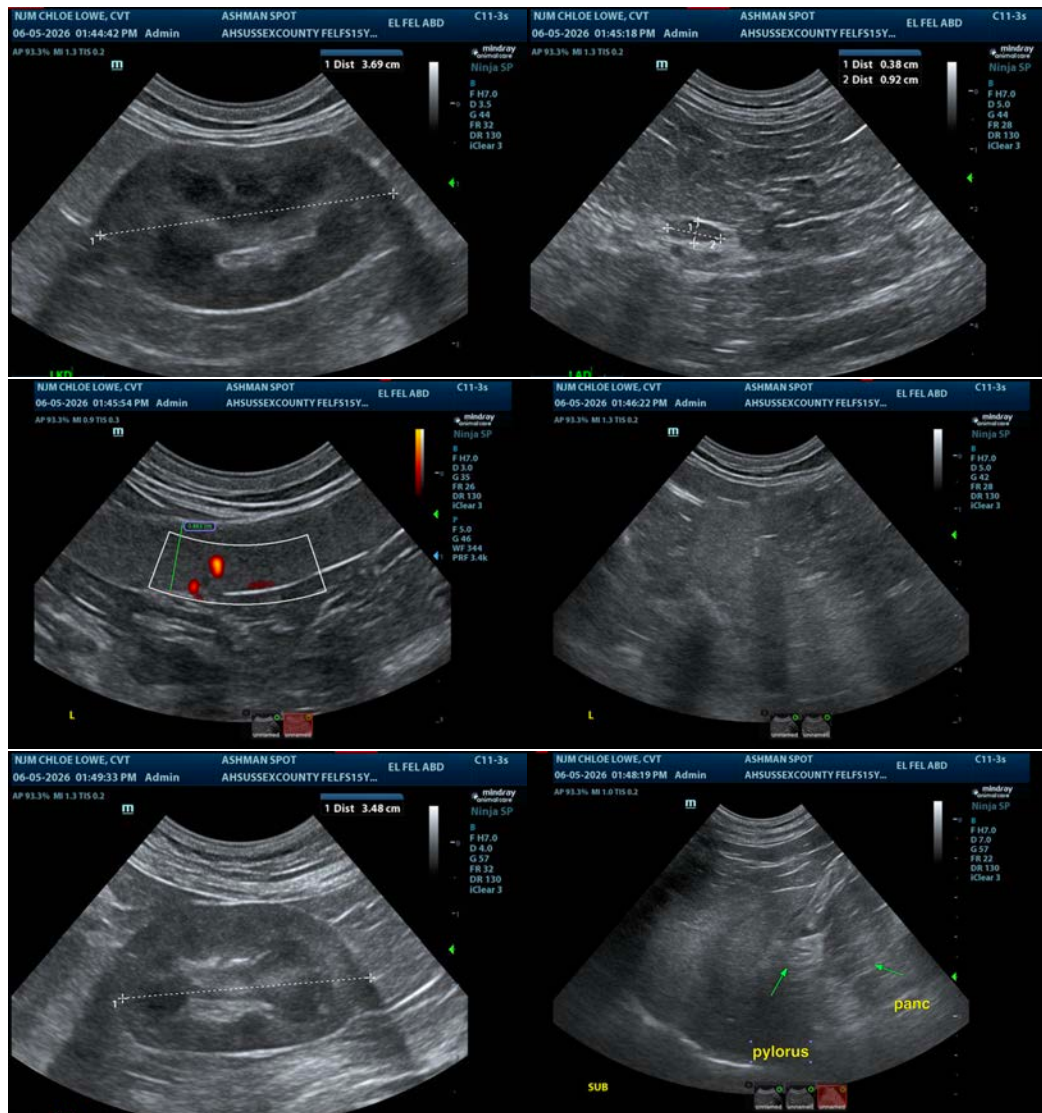
The base and limbs of the **pancreas** were observed to be largely isoechoic to surrounding omental fat. Pancreatic duct and capsular contour were acceptably normal and parenchyma respected normal curvilinear patterns. No overt evidence of active inflammatory or neoplastic disease was noted.

ULTRASONOGRAPHIC FINDINGS

- Subtle heterogeneous splenic changes, not overtly pathological.
- Age related renal and hepatic changes.

INTERPRETATION OF THE FINDINGS & FURTHER RECOMMENDATIONS

If any weight loss is an issue 25-gauge FNA of the spleen could be considered, yet changes are considered benign and expected for this age patient.





PATIENT

Spot Ashman

SPECIES

Feline

BREED

DSH

SEX

Spayed Female

AGE

15 Years

WEIGHT

11.9 lbs

INTERPRETED BY

Eric Lindquist, DMV,
 DABVP (CFM), Cert.
 IVUSS

IMAGING PERFORMED BY

Chloe Lowe, CVT

HOSPITAL NAME

Animal Hospital of
 Sussex County

REFERRING VET

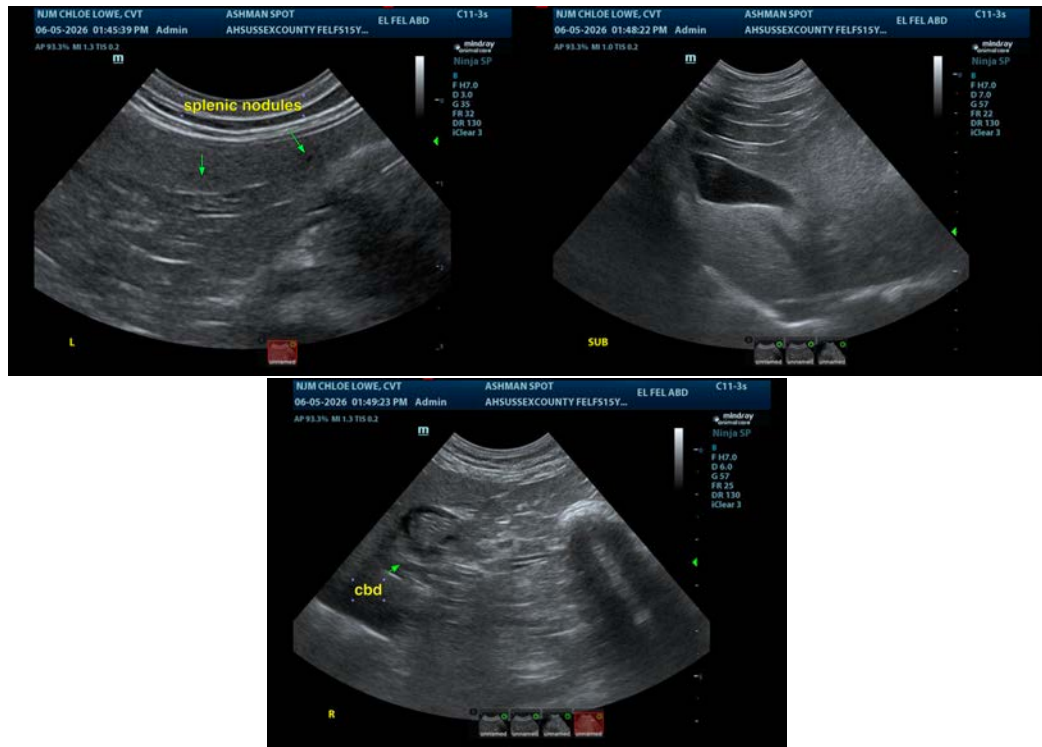
Dr. Lovell

INVOICE

75716

DATE

6/5/26



The information and recommendations provided are based on the images presented by the referring veterinarian/sonographer. No evaluation can be communicated regarding pathology that was not visible in the image/video clips provided.

Thank you for this referral. If the clinical or image interpretation does not parallel your findings or if I can be of any further assistance please contact me.

Eric Lindquist, DMV, DABVP(CFM), Cert. IVUSS,
 CEO, Owner, Founder -- SonoPath.com
info@SonoPath.com