



PATIENT

Janis Fridliana

SPECIES

Feline

BREED

Sphynx

SEX

Spayed Female

AGE

13 Years

WEIGHT

7 lbs

INTERPRETED BY

Eric Lindquist, DMV,
DABVP (CFM), Cert.
IVUSS

IMAGING PERFORMED BY

Kerri Becker

HOSPITAL NAME

Vetco Total Care –
Kinnelon

REFERRING VET

Dr. Griffin

INVOICE

75718

DATE

6/5/26

PRESENTING CLINICAL SIGNS

Recheck echo HX of HM and hypertension last echo w sonopath Stage B1. Meds amlodipine 1.25mg sid. Early ckd stage 1

ULTRASONOGRAPHIC EXAMINATION OF THE HEART

FELINE CARDIAC PARAMETERS	BODY WEIGHT (lbs)	HR (BPM)	IVSd (cm)	LVIDd (cm)	LVWd (cm)	FS (%)	EF (%)
NORMAL PARAMETER	-----	150-240	0.3-0.6	1.0-2.1	0.25-0.6	35-67	80-100
PATIENT	7	211	0.33	1.55	0.33	34	67
FELINE CARDIAC PARAMETERS	LA/AO (M-mode)	LA/AO HEART BASE (Sisson)	LAD LA MAX 4 Chamber		LVOT VEL. (m/s)	RVOT VEL. (m/s)	IVRT (m)
NORMAL PARAMETER	<1.5	1.6	0.7-1.7		<1.6	<1.3	40-60
PATIENT	1.1	1.3	1.3		1.0	1.0	NM
Adapted from June Boon, Veterinary Echocardiography, 1998 Sisson D et al. Jvim 1991; 5: 232, Jacobs et al. Am J Vet Res 1985; 46:1705							

E-wave velocity = 0.6

Cardiac Presentation

The echocardiogram in this patient demonstrated normal **left atrial** size based on 3 separate LA measurements. The cranial and caudal **mitral** valve leaflets presented normal linear structure and kinetics. The **left ventricle** presented normal thicknesses with linear contour and was not dilated nor restricted. The **myocardium** presented normal echogenicity without subjective evidence of significant fibrotic or ischemic disease. **Contractility** of the ventricular walls was adequate and in normal range for this patient evidenced by the fractional shortening measurement and subjective evaluation of the different regions and angles of the myocardium. The **left ventricular outflow** tract demonstrated normal laminar flow and subjective structural integrity. The **right atrium** and auricle revealed normal size, structure and content. No evidence of masses was noted or chamber overload. **Tricuspid** valvular assessment demonstrated adequate linear morphology and kinetics. The **right ventricle** was of normal size (1/3 diameter of LV), chordae structure, myocardial echogenicity and thickness. **Pulmonic** tract assessment revealed normal valve structure, laminar flow, and diameter (approx. 1:1 pa/ao ratio). No visible **pericardial** or free pleura fluid was noted or extra cardiac pathology in the visible planes. The cranial **mediastinum** and **pericardial** regions were free of masses in the visible window.

ULTRASONOGRAPHIC FINDINGS

- Normal echocardiogram.



PATIENT

Janis Fridliana

SPECIES

Feline

BREED

Sphynx

SEX

Spayed Female

AGE

13 Years

WEIGHT

7 lbs

INTERPRETED BY

Eric Lindquist, DMV,
DABVP (CFM), Cert.
IVUSS

IMAGING PERFORMED BY

Kerri Becker

HOSPITAL NAME

Vetco Total Care –
Kinnelon

REFERRING VET

Dr. Griffin

INVOICE

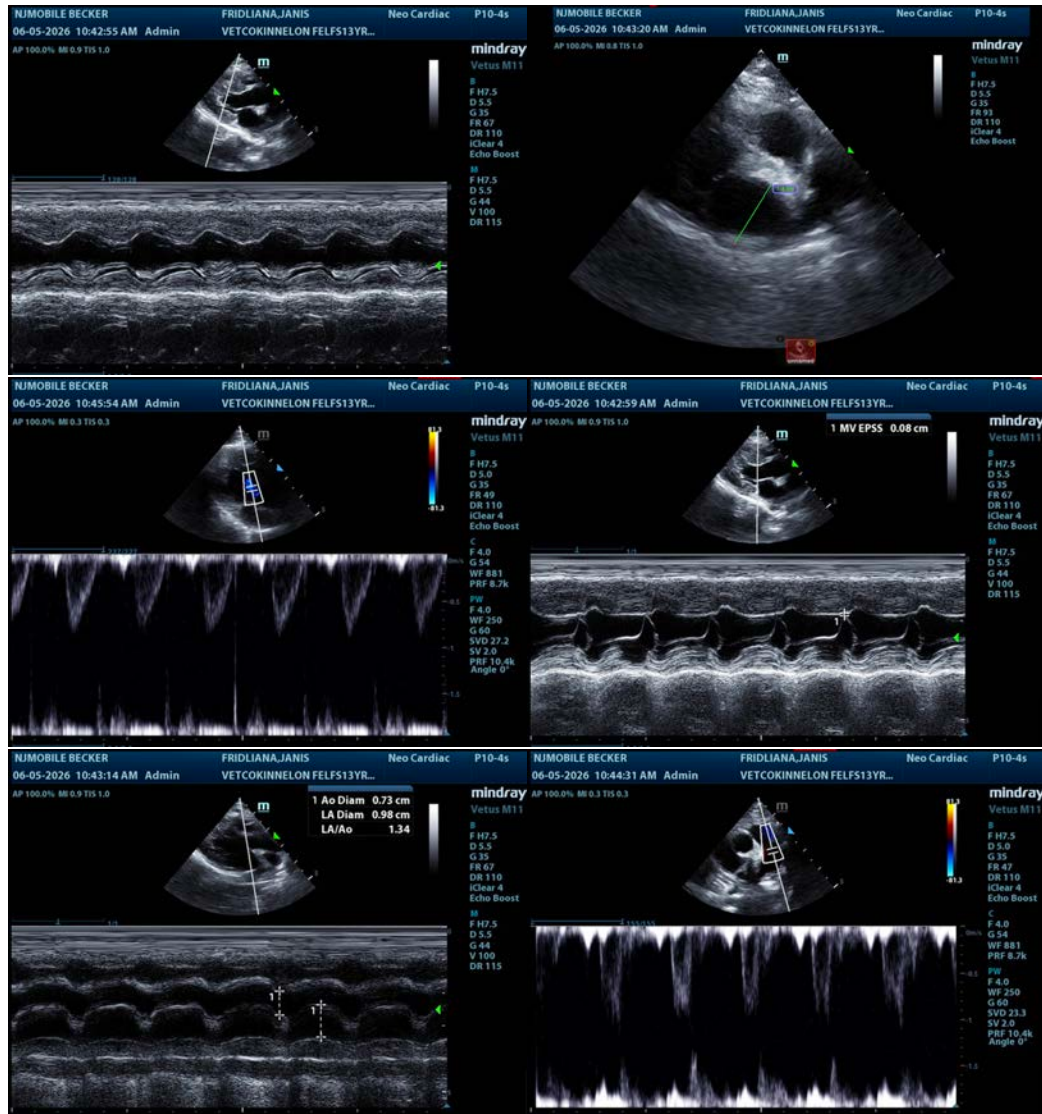
75718

DATE

6/5/26

INTERPRETATION OF THE FINDINGS & FURTHER RECOMMENDATIONS

No evidence of secondary changes owing to systemic hypertension. No evidence of structural or functional disease.





PATIENT

Janis Fridliana

SPECIES

Feline

BREED

Sphynx

SEX

Spayed Female

AGE

13 Years

WEIGHT

7 lbs

INTERPRETED BY

Eric Lindquist, DMV,
 DABVP (CFM), Cert.
 IVUSS

IMAGING PERFORMED BY

Kerri Becker

HOSPITAL NAME

Vetco Total Care –
 Kinnelon

REFERRING VET

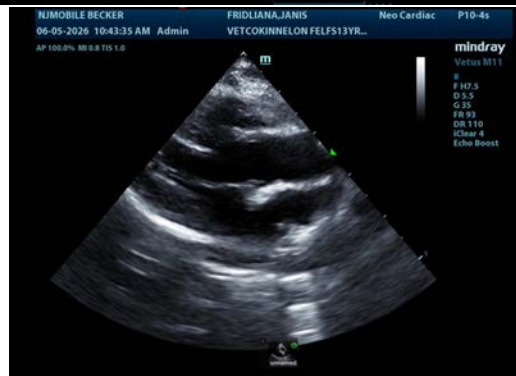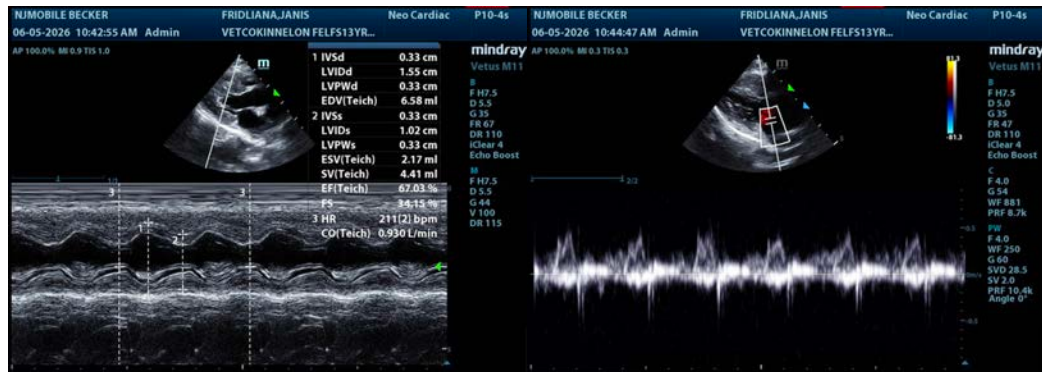Dr. Griffin

INVOICE

75718

DATE

6/5/26



The information and recommendations provided are based on the images presented by the referring veterinarian/sonographer. No evaluation can be communicated regarding pathology that was not visible in the image/video clips provided.

Thank you for this referral. If the clinical or image interpretation does not parallel your findings or if I can be of any further assistance please contact me.

Eric Lindquist, DMV, DABVP(CFM), Cert. IVUSS,
 CEO, Owner, Founder -- SonoPath.com
info@SonoPath.com