



PATIENT

Simba Mass

PRESENTING CLINICAL SIGNS

Congestive heart failure

SPECIES

Feline

BREED

Sphynx

SEX

Male

AGE

5

WEIGHT

10.6 lbs

ULTRASONOGRAPHIC EXAMINATION OF THE HEART

FELINE CARDIAC PARAMETERS	BODY WEIGHT	HR (BPM)	IVSd (cm)	LVIDd (cm)	LVWd (cm)	FS (%)	EF (%)
NORMAL PARAMETER	-----	150-240	0.3-0.6	1.0-2.1	0.25-0.6	35-67	80-100
PATIENT	10.6 lbs	NM	0.5	1.9	0.54	30	--
FELINE CARDIAC PARAMETERS	LA/AO (M-mode)	LA/AO HEART BASE (Sisson)	LAD LA MAX 4 Chamber		LVOT VEL. (m/s)	RVOT VEL. (m/s)	IVRT (m/)
NORMAL PARAMETER	<1.5	1.6	0.7-1.7		<1.6	<1.3	40-60
PATIENT	--	>2.0	2.7		1.0	NM	NM

Adapted from June Boon, Veterinary Echocardiography, 1998
Sisson D et al. JVIM 1991; 5: 232, Jacobs et al. Am J Vet Res 1985; 46:1705

EPSS: 0.5

INTERPRETED BY

Eric Lindquist, DMV, DABVP(CFM), Cert. IVUSS

Cardiac Presentation

Tricuspid insufficiency was present measuring 3.0 m/s. Mitral valve insufficiency was present measuring greater than 5.0 m/s. A large amount of pleural effusion was present in this patient with severe volume overload of the left and right heart. Slight pericardial effusion was visualized owing to left-sided failure. The insufficiency in this patient was severe. Septal and free wall thicknesses were normal in thickness, yet contractility was poor.

IMAGING PERFORMED BY

Dr. Lauren Sikorski

ULTRASONOGRAPHIC FINDINGS

- Unclassified cardiomyopathy/DCM type presentation with left and right-sided heart failure.

HOSPITAL NAME

Animal Internal Medicine

REFERRING VET

Dr. Lauren Sikorski

INTERPRETATION OF THE FINDINGS & FURTHER RECOMMENDATIONS

Taurine supplementation and diet assessment are indicated. Lasix is recommended at 12.5 mg BID. Palliative pleurocentesis is indicated. Pimobendan is indicated at 0.3 mg/kg, BID, ACE inhibitor at 0.5 mg/kg SID. Plavix therapy is also indicated. Prognosis is guarded. Causes of myocarditis in your region should be considered as well with recheck echo in two weeks.

INVOICE

16333

DATE

06/04/26



PATIENT

Simba Mass

SPECIES

Feline

BREED

Sphynx

SEX

Male

AGE

5

WEIGHT

10.6 lbs

INTERPRETED BY

Eric Lindquist, DMV,
DABVP(CFM), Cert.
IVUSS

IMAGING PERFORMED BY

Dr. Lauren Sikorski

HOSPITAL NAME

Animal Internal
Medicine

REFERRING VET

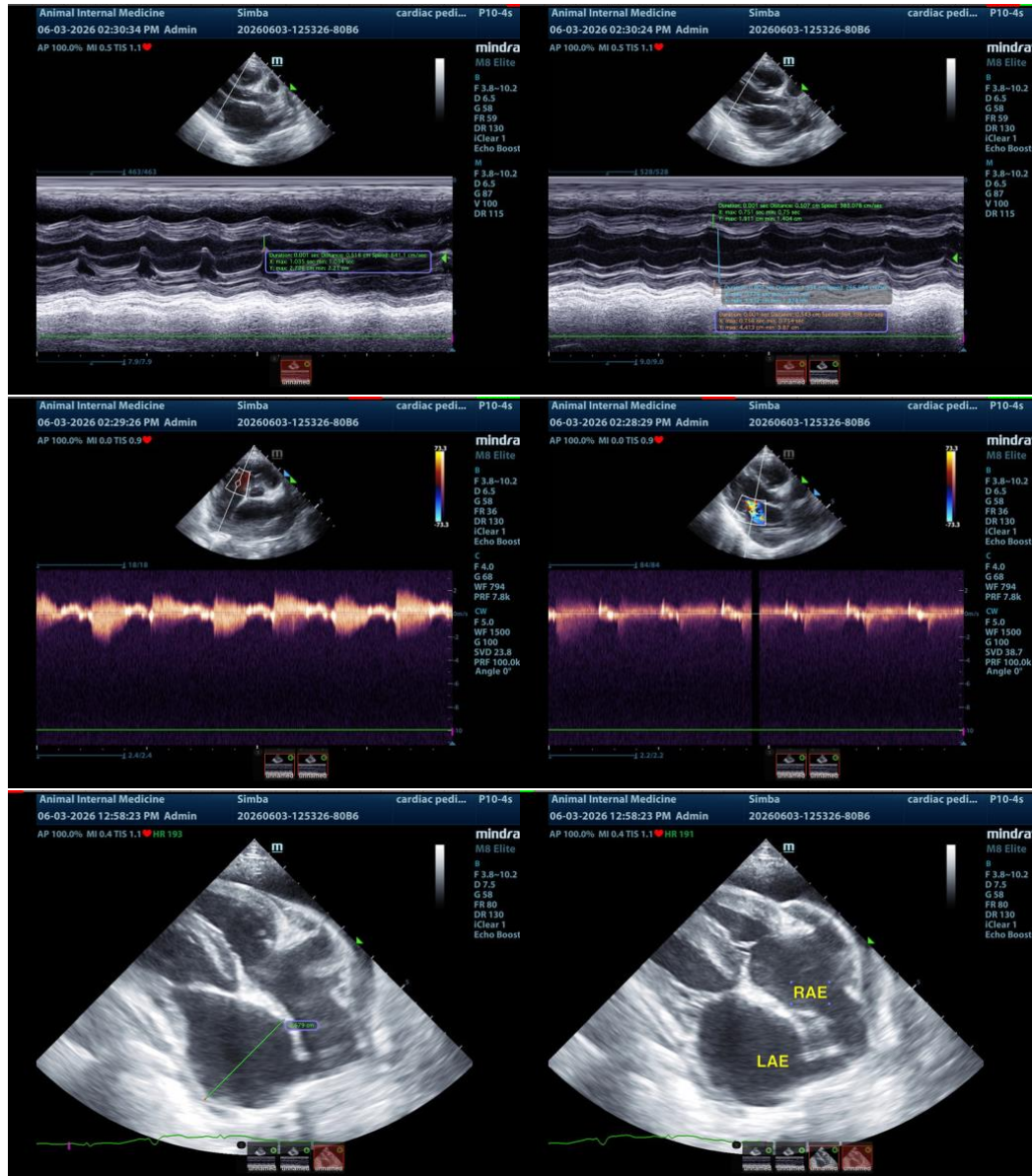
Dr. Lauren Sikorski

INVOICE

16333

DATE

06/04/26



The information and recommendations provided are based on the images presented by the referring veterinarian/sonographer. No evaluation can be communicated regarding pathology that was not visible in the image/video clips provided.

Thank you for this referral. If the clinical or image interpretation does not parallel your findings or if I can be of any further assistance, please contact me.

Eric Lindquist, DMV, DABVP(CFM), Cert. IVUSS,

CEO, Owner, Founder -- SonoPath.com

info@SonoPath.com



PATIENT

Simba Mass

SPECIES

Feline

BREED

Sphynx

SEX

Male

AGE

5

WEIGHT

10.6 lbs

INTERPRETED BY

Eric Lindquist, DMV,
DABVP(CFM), Cert.
IVUSS

IMAGING PERFORMED BY

Dr. Lauren Sikorski

HOSPITAL NAME

Animal Internal
Medicine

REFERRING VET

Dr. Lauren Sikorski

INVOICE

16333

DATE

06/04/26