



PATIENT

Rambo Santos

SPECIES

Canine

BREED

Mixed

SEX

Male

AGE

12 Years

WEIGHT

24 lbs

INTERPRETED BY

Eric Lindquist, DMV,
 DABVP(CFM), Cert.
 IVUSS

IMAGING PERFORMED BY

Vincent Ravancho CVT

HOSPITAL NAME

Veterinarian Pet
 Alliance

REFERRING VET

Dr. Rodriguez

INVOICE

16337

DATE

06/04/26

PRESENTING CLINICAL SIGNS

Suspect R sided CHF, Ascites, Grade 5/6 heart murmur. Clinical findings - Under conditioned secondary to cardiomyopathy, grade 2 dental dz, ascites secondary to cardiomyopathy. Current medications - Lasix 12.5 mg -2.2 mg/kg BID (2 tabs)

ULTRASONOGRAPHIC EXAMINATION OF THE HEART

CANINE CARDIAC PARAMETERS	MR VMAX (m/s)	TR VMAX (m/s)	LA/AO (M-Mode)	LA/AO (Heart Base; Swe)	FS (%)	EF (%)	EPSS (cm)
NORMAL PARAMETER	4.5-5.5	<2.7	1.3	Up to 1.6	28-40	40-100	<0.6
PATIENT	5.3	4.2	1.7	>2.5	57	88	0.2
CANINE CARDIAC PARAMETERS	HR (BPM)	AV VMAX (m/s)	PV MAX (m/s)	BODY WEIGHT	LAD LA MAX 4 Chamber	LVIDd Avg; 2D and m-mode short axis (cm)	LVIDs Avg; 2D and m-mode short axis (cm)
NORMAL PARAMETER	50-100	0.7-1.7	0.7-1.6				
PATIENT	176	1.4	0.9	24 lbs	4.3	3.5	--

Cardiac Presentation

The cardiac presentation in this patient presented with severe mitral and tricuspid insufficiency with volume overload in the left atrium, left ventricle, right atrium consistent with moderate to severe pulmonary hypertension. Arrhythmogenic activity was present. Prolapse of the anterior mitral valve leaflet was present. Pulmonary edema lines were present. The hepatic veins were dilated with secondary ascites. Significant hepatic remodeling was present with concurrent diffuse hepatic disease likely an issue.

ULTRASONOGRAPHIC FINDINGS

- Left and right-sided heart failure owing to valvular disease.

INTERPRETATION OF THE FINDINGS & FURTHER RECOMMENDATIONS

ECG and blood pressures are warranted if not already performed. Recommend continuation of Lasix therapy, adding Pimobendan at 0.3 mg/kg BID, Lasix at 3-4 mg/kg BID, ACE inhibitor 0.5 mg/ kg SID, spironolactone 1-2 mg/kg SID with recheck echocardiogram in 10 to 14 days. The patient is at risk for sudden death.



PATIENT

Rambo Santos

SPECIES

Canine

BREED

Mixed

SEX

Male

AGE

12 Years

WEIGHT

24 lbs

INTERPRETED BY

Eric Lindquist, DMV,
 DABVP(CFM), Cert.
 IVUSS

IMAGING PERFORMED BY

Vincent Ravancho CVT

HOSPITAL NAME

Veterinarian Pet
 Alliance

REFERRING VET

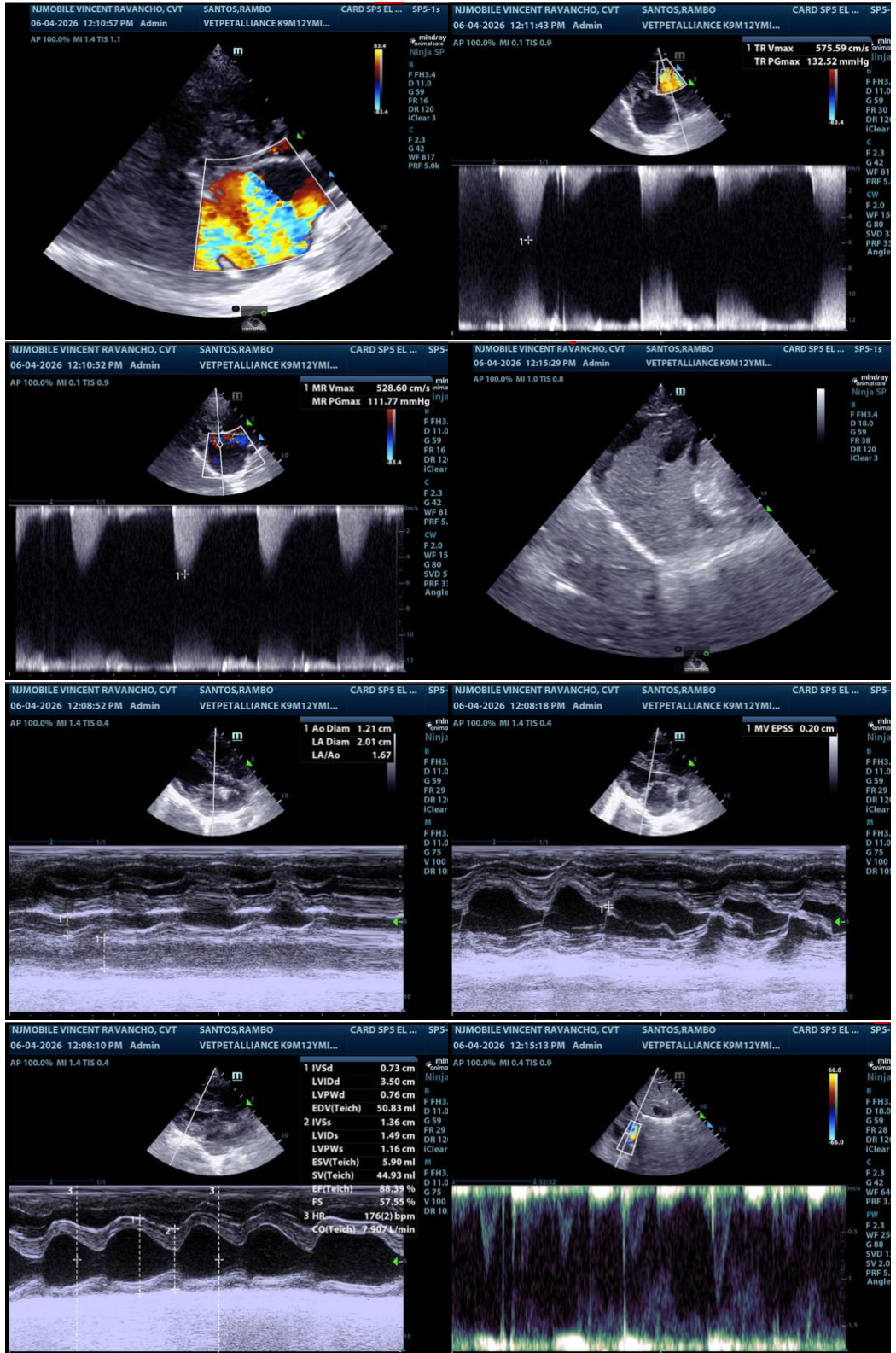
Dr. Rodriguez

INVOICE

16337

DATE

06/04/26





PATIENT

Rambo Santos

SPECIES

Canine

BREED

Mixed

SEX

Male

AGE

12 Years

WEIGHT

24 lbs

INTERPRETED BY

Eric Lindquist, DMV,
DABVP(CFM), Cert. IVUSS

IMAGING PERFORMED BY

Vincent Ravancho CVT

HOSPITAL NAME

Veterinarian Pet Alliance

REFERRING VET

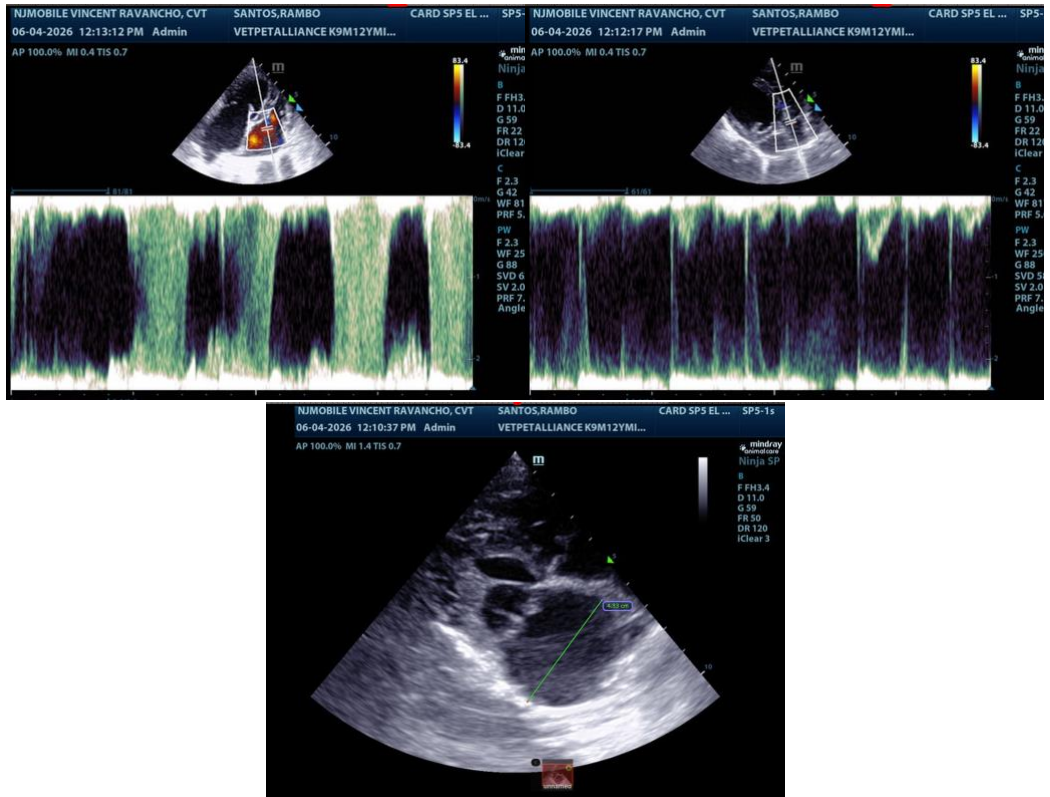
Dr. Rodriguez

INVOICE

16337

DATE

06/04/26



The information and recommendations provided are based on the images presented by the referring veterinarian/sonographer. No evaluation can be communicated regarding pathology that was not visible in the image/video clips provided.

Thank you for this referral. If the clinical or image interpretation does not parallel your findings or if I can be of any further assistance, please contact me.

Eric Lindquist, DMV, DABVP(CFM), Cert. IVUSS,

CEO, Owner, Founder -- SonoPath.com

info@SonoPath.com