



PATIENT

Molly Rotnam

SPECIES

Feline

BREED

DSH

SEX

Spayed Female

AGE

2 Years 10 Months

WEIGHT

5.6 kg

INTERPRETED BY

Eric Lindquist, DMV,
DABVP (Canine &
Feline), Cert. IVUSS

IMAGING PERFORMED BY

Dr. Mariusz
Chmielinski, DVM

HOSPITAL NAME

Apex VS

REFERRING VET

Alpine 24/7 ER Doctor

INVOICE

37353

DATE

6/4/26

PRESENTING CLINICAL SIGNS

History: Presented initially June 2, 2026 for acute vomiting. Treated symptomatically with maropitant, SQ fluids, and probiotics. Returned June 3, 2026 for persistent anorexia and lethargy. CBC/chemistry reportedly unremarkable. Abdominal radiographs demonstrated mild constipation/obstipation and a soft tissue opacity/nodular structure in the pyloric/hepatic region. Manual de-obstipation was performed under sedation and patient discharged with mirtazapine, gabapentin, and FortiFlora. Returned June 4, 2026 for significant clinical deterioration including persistent anorexia, lethargy, dehydration, and fever despite previous treatment.

Abnormal PE/Chem/CBC/UA Results: Physical Examination: Temperature: 40.6°C Heart Rate: 230 bpm Approximately 7% dehydrated QAR Mild abdominal discomfort Significant discomfort localized to the right cranial abdomen during ultrasound examination despite methadone 0.2 mg/kg administration Overall, Molly's bloodwork was unremarkable despite significant clinical illness.

ULTRASONOGRAPHIC EXAMINATION OF THE ABDOMEN

Urinary System

The **urinary bladder**, trigone, and pelvic urethra presented normal thicknesses and normal tone. The ureters were not visible which is normal. No uroliths or sediment were visualized and anechoic urine was present. No evidence of inflammatory or neoplastic changes were noted. Ureteral papillae were normal.

The **kidneys** revealed normal size and structure, corticomedullary definition and ratio for this age. The cortices presented largely uniform texture with normal echogenic relationship to liver and spleen. Medullary structure differed distinctly from the cortex and no evidence of pelvic dilation was present. The capsules were acceptably uniform without significant irregularities. The right kidney measured 4.72 cm. The left kidney measured 3.9 cm.

Adrenal Glands

The **left adrenal gland** was visualized and recognized as having normal shape, size, position and echogenicity for this breed. The phrenic vasculature, glandular echogenicity and detail were unremarkable. Capsule, cortex, and medullary definition were normal for this age patient. The left adrenal gland measured 0.49 cm.

The region of the **right adrenal gland** revealed no evident pathology.

Spleen

The **spleen** presented a smooth homogeneous parenchyma hyperechoic to liver and renal cortical parenchyma. The capsule was smooth without noticeable expansion or deviation from within the spleen or adjacent pathology. The splenic vasculature demonstrated normal volume without signs of congestion or thrombosis. No sonographic evidence of acute or chronic inflammatory, neoplastic, or infarctual changes were noted.

Liver



PATIENT

Molly Rotnam

SPECIES

Feline

BREED

DSH

SEX

Spayed Female

AGE

2 Years 10 Months

WEIGHT

5.6 kg

INTERPRETED BY

Eric Lindquist, DMV,
DABVP (Canine &
Feline), Cert. IVUSS

IMAGING PERFORMED BY

Dr. Mariusz
Chmielinski, DVM

HOSPITAL NAME

Apex VS

REFERRING VET

Alpine 24/7 ER Doctor

INVOICE

37353

DATE

6/4/26

The **liver** images submitted revealed subjectively normal liver size, contour, and structure. Parenchymal echogenicity was naturally coarse and hypoechoic to the spleen. Vascular and biliary tracts were of normal volume with no evidence of congestion. The gallbladder presented acceptably thin walls with primarily anechoic content. The cystic and common bile ducts were normal. No pathological hepatic lymphadenopathy was evident. No overt structural evidence of inflammatory, infiltrative or regenerative pathology was evident.

Gastrointestinal

The **gastric** lumen was fluid filled. This is consistent with gastric ileus. Some hyperperistalsis was noted in the small intestine, as well as soft stool in the colon.

Pancreas

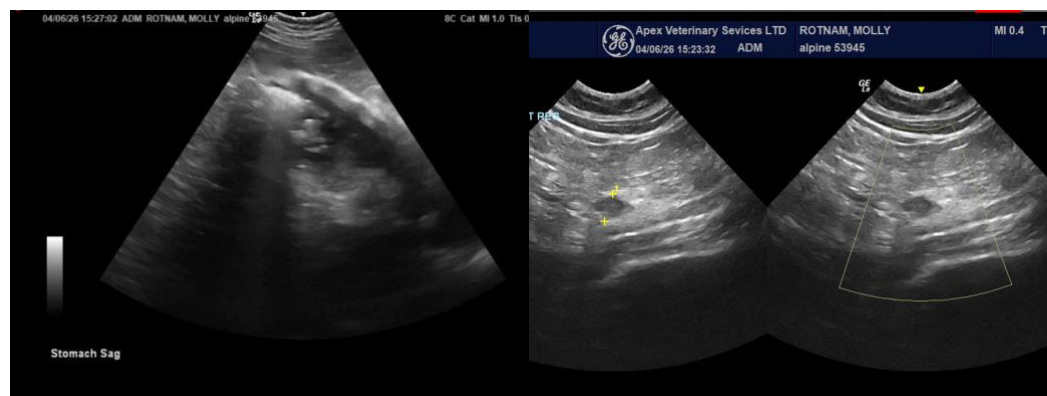
The base and limbs of the **pancreas** were observed to be largely isoechoic to surrounding omental fat. Pancreatic duct and capsular contour were acceptably normal and parenchyma respected normal curvilinear patterns. No overt evidence of active inflammatory or neoplastic disease was noted.

ULTRASONOGRAPHIC FINDINGS

- Structurally unremarkable abdomen
- Fluid filled gastric lumen– no evidence of obstruction.
- Hyperperistalsis in the small intestine
- Soft stool in the colon

INTERPRETATION OF THE FINDINGS & FURTHER RECOMMENDATIONS

Supportive care for GI upset should prove effective. Enterotoxins, parasites and dietary intolerance are primary concerns. No evidence of significant structural disease.





PATIENT

Molly Rotnam

SPECIES

Feline

BREED

DSH

SEX

Spayed Female

AGE

2 Years 10 Months

WEIGHT

5.6 kg

INTERPRETED BY

Eric Lindquist, DMV,
DABVP (Canine &
Feline), Cert. IVUSS

IMAGING PERFORMED BY

Dr. Mariusz
Chmielinski, DVM

HOSPITAL NAME

Apex VS

REFERRING VET

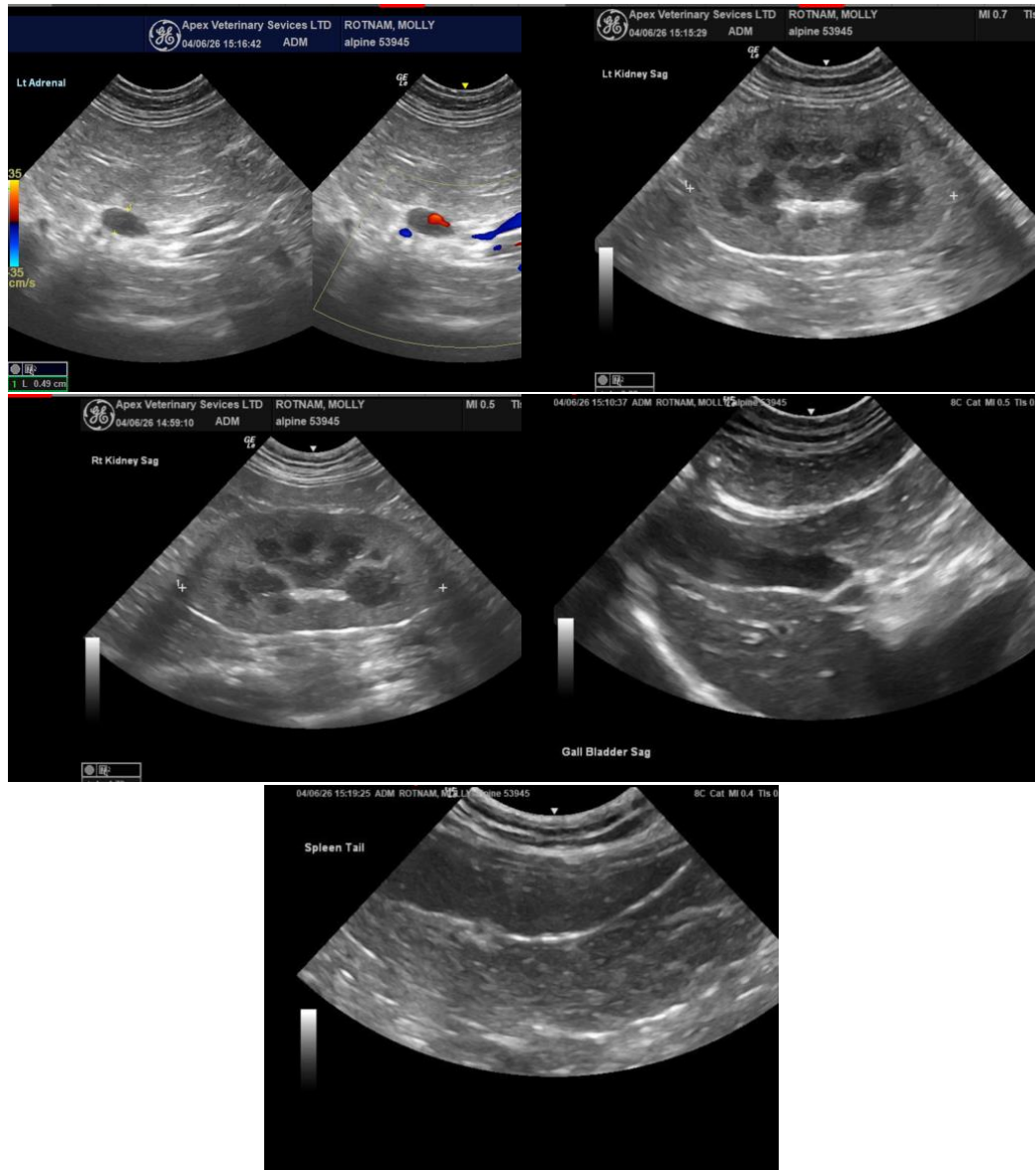
Alpine 24/7 ER Doctor

INVOICE

37353

DATE

6/4/26



The information and recommendations provided are based on the images presented by the referring veterinarian/sonographer. No evaluation can be communicated regarding pathology that was not visible in the image/video clips provided.

Thank you for this referral. If the clinical or image interpretation does not parallel your findings or if I can be of any further assistance please contact me.

Eric Lindquist, DMV, DABVP(CFM), Cert. IVUSS, CEO, Owner, Founder -- SonoPath.com
info@SonoPath.com