



PATIENT

Mika Camille

SPECIES

Canine

BREED

Shiba Inu

SEX

Spayed Female

AGE

11

WEIGHT

33

INTERPRETED BY

Eric Lindquist, DMV,
DABVP(CFM), Cert.
IVUSS

IMAGING PERFORMED BY

Grace Jayne, CVT

HOSPITAL NAME

Ark Animal HomeCare

REFERRING VET

Dr Erika De Beckers

INVOICE

37335

DATE

6/3/26

PRESENTING CLINICAL SIGNS

History: Presented for a recheck of a urinary tract infection. The owner suspected constipation due to a distended abdomen.

Abnormal PE/Chem/CBC/UA Results: Distended painful abdomen.

LIMITED ULTRASONOGRAPHIC EXAMINATION

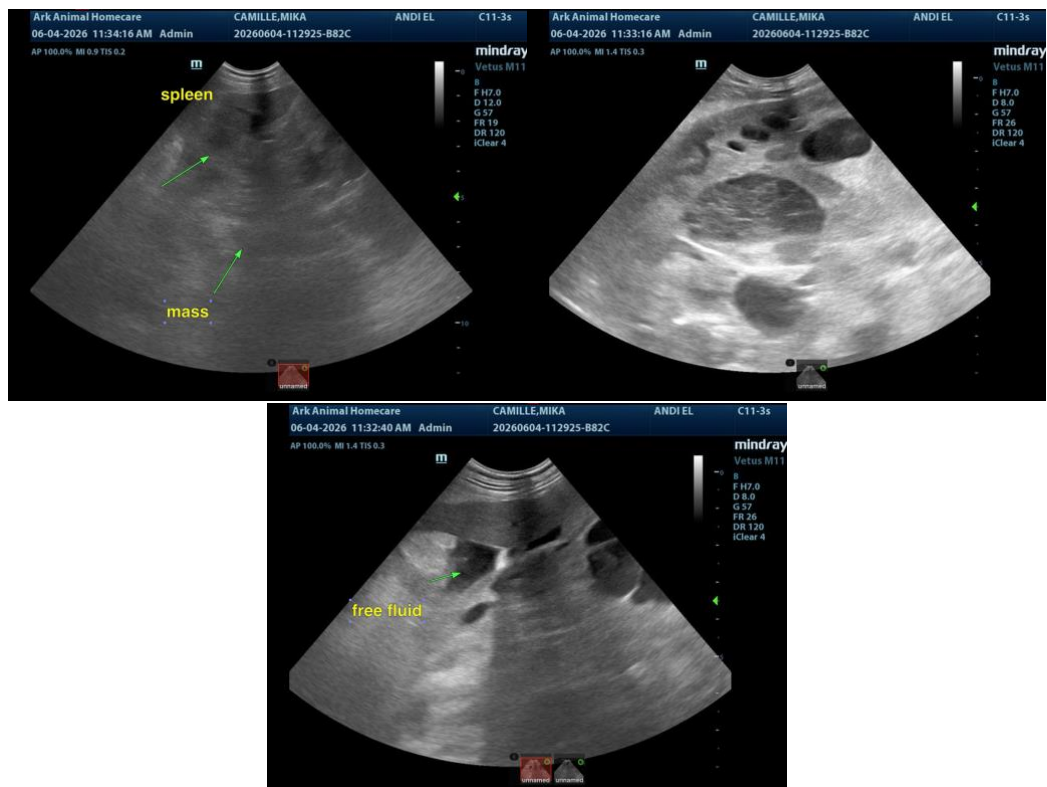
An extensive mixed hypoechoic cystic and complex mass was noted occupying the majority of the abdomen, impinging upon portions of the GI tract. In two views, it appears that this mass derives from likely the mid caudal body of the spleen. Free fluid was noted in the area, suggestive for rupture, potential hemorrhage.

ULTRASONOGRAPHIC FINDINGS

- Extensive mass, likely of splenic origin, yet cannot definitively determine the origin.

INTERPRETATION OF THE FINDINGS & FURTHER RECOMMENDATIONS

Full abdominal sonogram or CT, or direct exploratory are indicated. Surgical exploratory and intervention are recommended.



The information and recommendations provided are based on the images presented by the



PATIENT

Mika Camille

SPECIES

Canine

BREED

Shiba Inu

SEX

Spayed Female

AGE

11

WEIGHT

33

INTERPRETED BY

Eric Lindquist, DMV,
DABVP(CFM), Cert.
IVUSS

IMAGING PERFORMED BY

Grace Jayne, CVT

HOSPITAL NAME

Ark Animal HomeCare

REFERRING VET

Dr Erika De Beckers

INVOICE

37335

DATE

6/3/26

referring veterinarian/sonographer. No evaluation can be communicated regarding pathology that was not visible in the image/video clips provided.

Thank you for this referral. If the clinical or image interpretation does not parallel your findings or if I can be of any further assistance please contact me.

Eric Lindquist, DMV, DABVP(CFM), Cert. IVUSS, CEO, Owner, Founder -- SonoPath.com
info@SonoPath.com