



PATIENT

Chewie Stern

SPECIES

Canine

BREED

Pitbull Mix

SEX

Neutered Male

AGE

5 Years

WEIGHT

48 lbs

INTERPRETED BY

Eric Lindquist, DMV,
DABVP(CFM), Cert.
IVUSS

IMAGING PERFORMED BY

Dr. Rodriguez

HOSPITAL NAME

Foxfield Veterinary
Services

REFERRING VET

Dr. Rodriguez

INVOICE

16289

DATE

06/04/26

PRESENTING CLINICAL SIGNS

Large mass in the R submandibular region

FNA cytology: Chronic suppurative Inflammation

LIMITED ULTRASONOGRAPHIC EXAMINATION

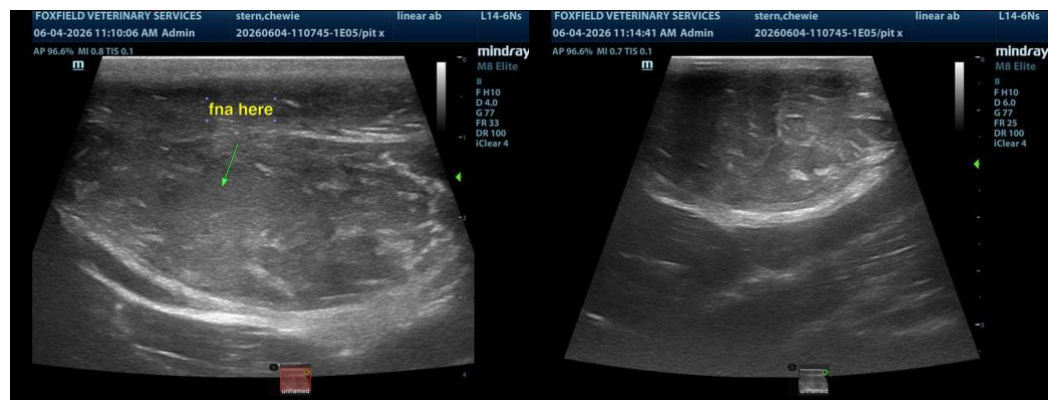
The **submandibular region** revealed an encapsulated 4.5 cm fluid and tissue-filled structure, consistent with sialocele and appears encapsulated yet does not appear overtly neoplastic.

ULTRASONOGRAPHIC FINDINGS

- Sialocele like mass.

INTERPRETATION OF THE FINDINGS & FURTHER RECOMMENDATIONS

Ultrasound-guided FNA and drainage are indicated with culture. CT evaluation would be ideal for surgical planning. The mass appears encapsulated and surgically removable.



The information and recommendations provided are based on the images presented by the referring veterinarian/sonographer. No evaluation can be communicated regarding pathology that was not visible in the image/video clips provided.

Thank you for this referral. If the clinical or image interpretation does not parallel your findings or if I can be of any further assistance, please contact me.

Eric Lindquist, DMV, DABVP(CFM), Cert. IVUSS,

CEO, Owner, Founder -- SonoPath.com

info@SonoPath.com