



**PATIENT**

Carmelle Schimoier

**SPECIES**

Canine

**BREED**

Cockapoo

**SEX**

Spayed Female

**AGE**

9 Years 5 Months

**WEIGHT**

22 lbs

**INTERPRETED BY**

Eric Lindquist, DMV,  
DABVP(CFM), Cert.  
IVUSS

**IMAGING PERFORMED BY**

Dr. Ken Leal

**HOSPITAL NAME**

Black River Veterinary  
Hospital

**REFERRING VET**

Dr. Hill

**INVOICE**

16336

**DATE**

06/04/26

**PRESENTING CLINICAL SIGNS**

6 month recheck. 3/6 heart murmur, Strong pulses, normal rate and rhythm. Medications: None

**ULTRASONOGRAPHIC EXAMINATION OF THE HEART**

CANINE CARDIAC PARAMETERS	MR VMAX (m/s)	TR VMAX (m/s)	LA/AO (M-Mode)	LA/AO (Heart Base; Swe)	FS (%)	EF (%)	EPSS (cm)
NORMAL PARAMETER	4.5-5.5	<2.7	1.3	Up to 1.6	28-40	40-100	<0.6
PATIENT	6.3	1.45	1.3	--	54	86	0.1
CANINE CARDIAC PARAMETERS	HR (BPM)	AV VMAX (m/s)	PV MAX (m/s)	BODY WEIGHT	LAD LA MAX 4 Chamber	LVIDd Avg; 2D and m-mode short axis (cm)	LVIDs Avg; 2D and m-mode short axis (cm)
NORMAL PARAMETER	50-100	0.7-1.7	0.7-1.6				
PATIENT	108	--	0.77	22 lbs	3.8	2.27	--

**Cardiac Presentation**

Cardiac presentation in this patient presented, persistent mitral and tricuspid insufficiency with minor prolapse of the anterior mitral valve leaflet. No significant volume overload in any of the four chambers. No progression from the prior sonogram. Pericardial and pleural spaces were unremarkable.

**ULTRASONOGRAPHIC FINDINGS**

- Persistent stable stage B1 valvular disease.

**INTERPRETATION OF THE FINDINGS & FURTHER RECOMMENDATIONS**

The heart is stable without clinical disease. No overt contraindication for anesthesia of brief to moderate duration. I suggest Torbutrol premed, Propofol induction, Isoflo maintenance or similar protocol if anesthesia is desired. Blood pressure, EKG and chest radiographs are recommended if not already performed. Target white coat negative systolic pressure of < 160 mmHg. If higher than this ACE-inhibitor is suggested to reach this level. Recheck echocardiogram is recommended in 6-12 months, earlier if murmur grade increases or clinical signs initiate.



**PATIENT**

Carmelle Schimoier

**SPECIES**

Canine

**BREED**

Cockapoo

**SEX**

Spayed Female

**AGE**

9 Years 5 Months

**WEIGHT**

22 lbs

**INTERPRETED BY**

Eric Lindquist, DMV,  
 DABVP(CFM), Cert.  
 IUUSS

**IMAGING PERFORMED BY**

Dr. Ken Leal

**HOSPITAL NAME**

Black River Veterinary  
 Hospital

**REFERRING VET**

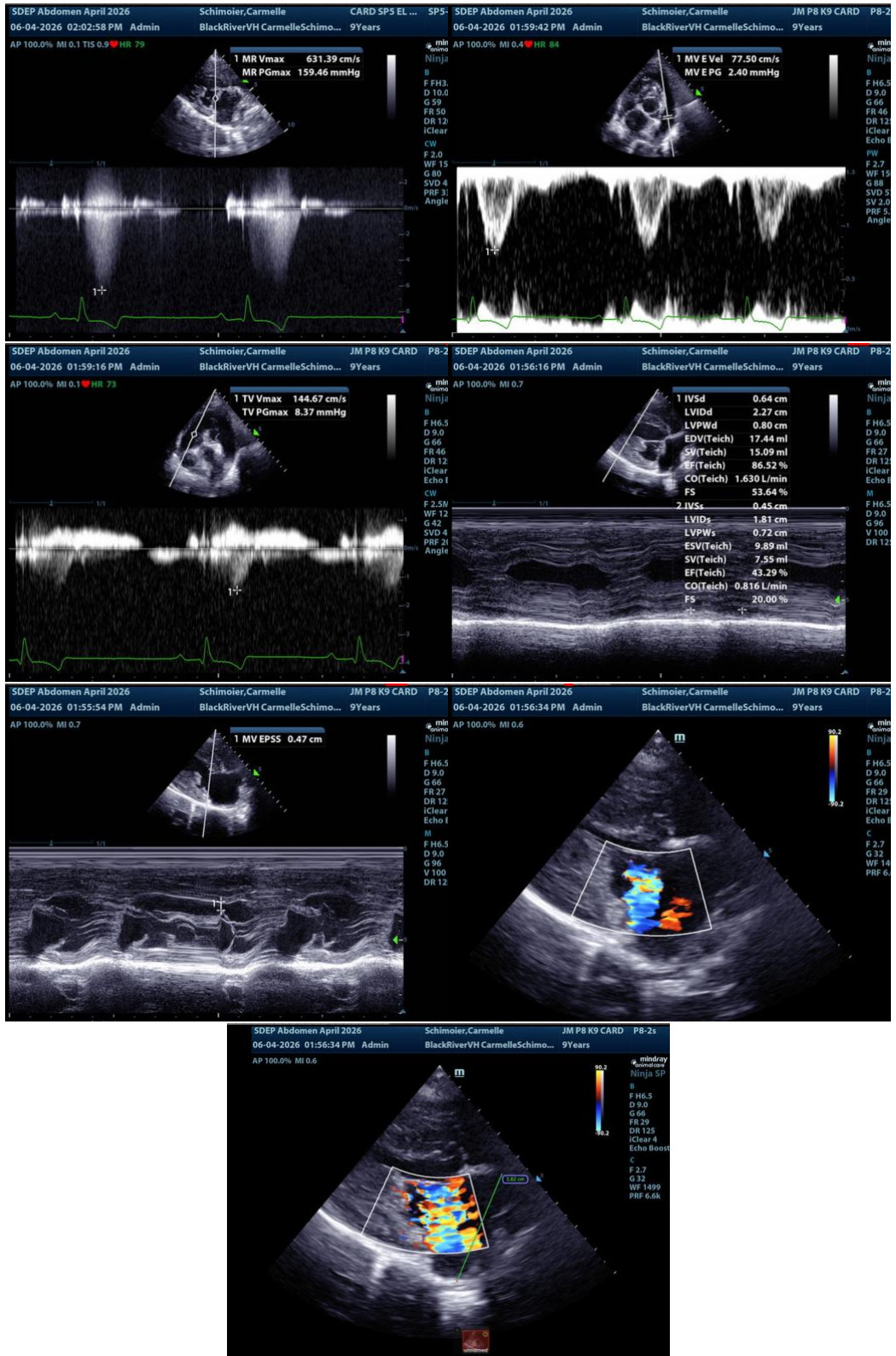
Dr. Hill

**INVOICE**

16336

**DATE**

06/04/26





**PATIENT**

Carmelle Schimoier

**SPECIES**

Canine

**BREED**

Cockapoo

**SEX**

Spayed Female

**AGE**

9 Years 5 Months

**WEIGHT**

22 lbs

**INTERPRETED BY**

Eric Lindquist, DMV,  
DABVP(CFM), Cert.  
IVUSS

**IMAGING  
PERFORMED BY**

Dr. Ken Leal

**HOSPITAL NAME**

Black River Veterinary  
Hospital

**REFERRING VET**

Dr. Hill

**INVOICE**

16336

**DATE**

06/04/26

The information and recommendations provided are based on the images presented by the referring veterinarian/sonographer. No evaluation can be communicated regarding pathology that was not visible in the image/video clips provided.

Thank you for this referral. If the clinical or image interpretation does not parallel your findings or if I can be of any further assistance, please contact me.

**Eric Lindquist, DMV, DABVP(CFM), Cert. IVUSS,**

CEO, Owner, Founder -- SonoPath.com

[info@SonoPath.com](mailto:info@SonoPath.com)