



PATIENT

Blue Onischuk

SPECIES

Canine

BREED

Spaniel Mix

SEX

Neutered Male

AGE

5 Years 8 Months

WEIGHT

40 lbs

INTERPRETED BY

Eric Lindquist, DMV,
 DABVP(CFM), Cert.
 IVUSS

IMAGING PERFORMED BY

Vincent Ravancho CVT

HOSPITAL NAME

Rockaway Animal
 Hospital

REFERRING VET

Dr. Brooks

INVOICE

16327

DATE

06/04/26

PRESENTING CLINICAL SIGNS

PU/PD. Increased panting, potbellied, hepatomegaly. Concern for Cushing's, had LDDST. Also, muscle weakness left front limping. Current medications - rimadyl, gabapentin

Abnormal PE/Chem/CBC/UA Results: ALP 1882. LDDST- rest 2.29, 4hr <0.5, 8hr 0.8. U/A - protein 30, UPC <0.2. USG 1.036

ULTRASONOGRAPHIC EXAMINATION OF THE ABDOMEN

Urinary System

The **urinary bladder**, trigone, and pelvic urethra to a depth of 3.0 cm presented normal thicknesses and normal tone. The ureters were not visible which is normal. No uroliths or sediment were visualized, and anechoic urine was present. No evidence of inflammatory or neoplastic changes were noted. Ureteral papillae were normal.

The **kidneys** revealed normal size and structure, corticomedullary definition and ratio for this age. The cortices presented largely uniform texture with normal echogenic relationship to liver and spleen. Medullary structure differed distinctly from the cortex and no evidence of pelvic dilation was present. The capsules were acceptably uniform without significant irregularities. The left kidney measured 5.73 cm in length. The right kidney measured 6.63 cm in length.

Adrenal Glands

Both **adrenal glands** were visualized and recognized as having normal shape, size, position and echogenicity for this breed. The phrenic vasculature, glandular echogenicity and detail were unremarkable. Capsule, cortex, and medullary definition were normal for this age patient. The left adrenal gland measured 2.09 cm x 0.47 cm width at the cranial pole and 0.54 cm width at the caudal pole. The right adrenal gland measured 2.32 cm x 1.48 cm width at the cranial pole and 0.4 cm width at the caudal pole.

Spleen

The **spleen** presented a smooth homogeneous parenchyma hyperechoic to liver and renal cortical parenchyma. The capsule was smooth without noticeable expansion or deviation from within the spleen or adjacent pathology. The splenic vasculature demonstrated normal volume without signs of congestion or thrombosis. No sonographic evidence of acute or chronic inflammatory, neoplastic, or infarctual changes were noted.

Liver

The **liver** revealed mild uniform enlargement with slight increased portal markings. These changes are minor and nonspecific. The gallbladder and common bile duct were unremarkable.

Gastrointestinal

Examination of the **gastrointestinal tract** revealed a stomach and intestine free of stasis, of normal wall thickness, acceptable curvilinear mural detail, and peristaltic activity. Small and large intestine demonstrated normal luminal chyme and stool consistency respectively. No obstructive or overt infiltrative disease was noted. No associated abnormal lymphatic activity was noted.

Pancreas



PATIENT

Blue Onischuk

SPECIES

Canine

BREED

Spaniel Mix

SEX

Neutered Male

AGE

5 Years 8 Months

WEIGHT

40 lbs

INTERPRETED BY

Eric Lindquist, DMV,
 DABVP(CFM), Cert.
 IUUSS

IMAGING PERFORMED BY

Vincent Ravancho CVT

HOSPITAL NAME

Rockaway Animal
 Hospital

REFERRING VET

Dr. Brooks

INVOICE

16327

DATE

06/04/26

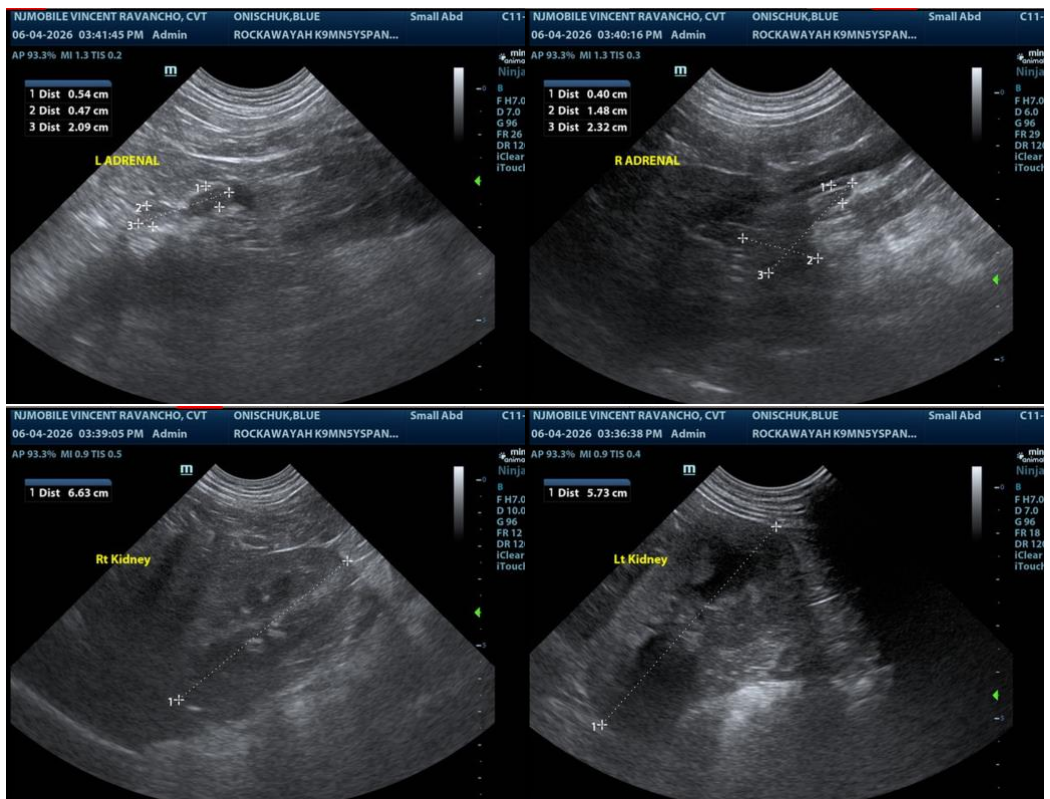
The base and limbs of the **pancreas** were observed to be largely isoechoic to surrounding omental fat. Pancreatic duct and capsular contour were acceptably normal and parenchyma respected normal curvilinear patterns. No overt evidence of active inflammatory or neoplastic disease was noted.

ULTRASONOGRAPHIC FINDINGS

- Structurally unremarkable abdomen with benign hepatopathy and minor remodeling.
- Structurally normal adrenal glands.

INTERPRETATION OF THE FINDINGS & FURTHER RECOMMENDATIONS

Given that the adrenal glands are normal and the urine-specific gravity is well-concentrated, Cushing's is unlikely. Benign alkaline/phosphatase elevation may be a breed predisposition, or other endocrinopathy may be in play, yet structurally, the abdomen appears unremarkable.





PATIENT

Blue Onischuk

SPECIES

Canine

BREED

Spaniel Mix

SEX

Neutered Male

AGE

5 Years 8 Months

WEIGHT

40 lbs

INTERPRETED BY

Eric Lindquist, DMV,
DABVP(CFM), Cert.
IVUSS

IMAGING PERFORMED BY

Vincent Ravancho CVT

HOSPITAL NAME

Rockaway Animal
Hospital

REFERRING VET

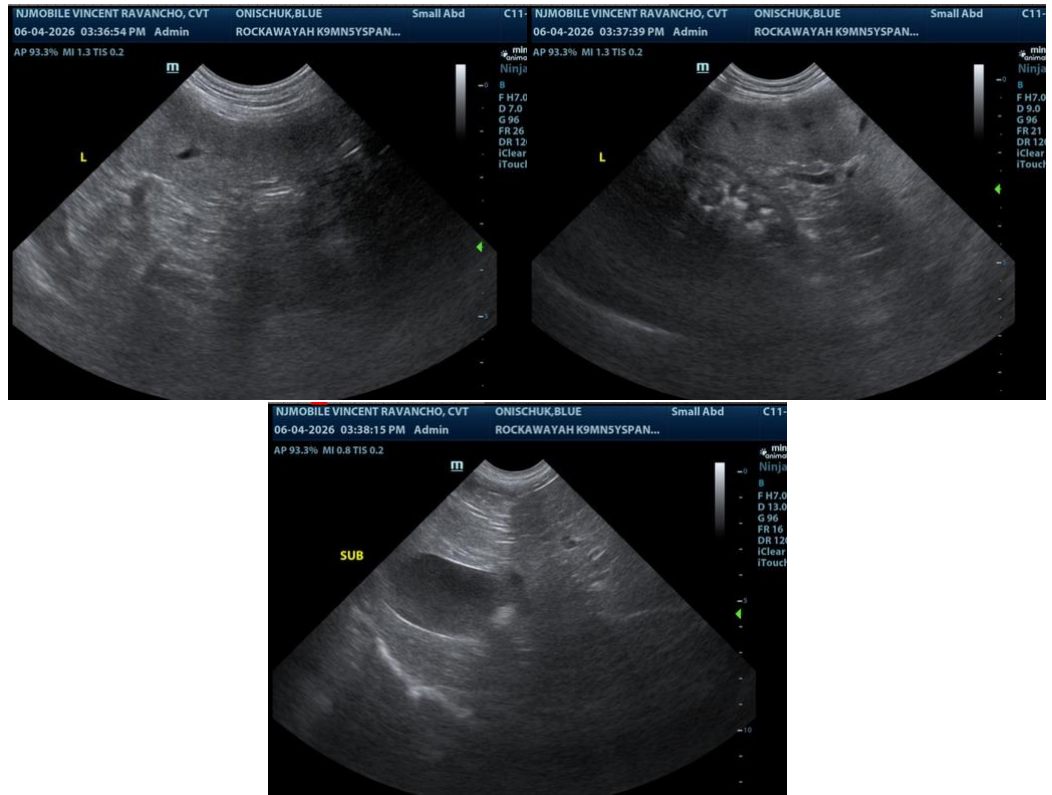Dr. Brooks

INVOICE

16327

DATE

06/04/26



The information and recommendations provided are based on the images presented by the referring veterinarian/sonographer. No evaluation can be communicated regarding pathology that was not visible in the image/video clips provided.

Thank you for this referral. If the clinical or image interpretation does not parallel your findings or if I can be of any further assistance, please contact me.

Eric Lindquist, DMV, DABVP(CFM), Cert. IVUSS,

CEO, Owner, Founder -- SonoPath.com

info@SonoPath.com