



**PATIENT**

Zuzu Revello

**SPECIES**

Canine

**BREED**

Mini Poodle Mix

**SEX**

Spayed Female

**AGE**

12 Years

**WEIGHT**

4.02 kg

**INTERPRETED BY**

Eric Lindquist, DMV  
DABVP, Cert. IVUSS

**IMAGING PERFORMED BY**

Dr. Massa

**HOSPITAL NAME**

Animal Emergency  
Hospital, Volusia

**REFERRING VET**

Dr. Massa

**INVOICE**

15888

**DATE**

6/4/22

**PRESENTING CLINICAL SIGNS**

History: PP for eval of no appetite severe lethargy and vomiting.

Abnormal PE/Chem/CBC/UA Results: positive CPLi, BUN/Crea to high to read

**ULTRASONOGRAPHIC EXAMINATION OF THE ABDOMEN**

**Urinary System**

The **urinary bladder** was not visualized.

The **kidneys** revealed largely normal size and structure, corticomedullary definition and ratio (cortex 1/3 of medulla) were essentially maintained with some minor age-related loss of curvilinear patterns regarding the capsule and C/M junction. The cortices presented largely uniform texture with some increased echogenicity expected for his age patient. Medullary structure differed distinctly from that of the cortex and no evidence of pelvic dilation was present. Both kidneys measured 4.0 cm each.

**Adrenal Glands**

The **adrenal glands** were not visualized.

**Spleen**

The **spleen** revealed a hypoechoic 5.0 mm nodule in the mid cranial body and a separate 0.5 cm nodule. Age-related splenic changes were noted otherwise.

**Liver**

The **liver** images from right and left intercostal as well as subcostal views revealed subjectively normal liver size, contour, and structure. Some minor age-related parenchymal remodeling was noted but likely not clinically significant at this time. Vascular and biliary tracts were of normal volume and no evidence of congestion was noted. The gallbladder presented some dependent debris with essentially normal contour. The cystic and common bile ducts were normal. No overt evidence of active inflammatory, infiltrative or regenerative pathology was noted but should be paired with current or past LE elevations regarding any clinical significance to this presentation. The hepatic lymph nodes were unremarkable.

**Gastrointestinal**

Examination of the **gastrointestinal tract** revealed a stomach and intestine free of stasis, of normal wall thickness, acceptable curvilinear mural detail, and peristaltic activity. Small and large intestine demonstrated normal luminal chyme and stool consistency respectively. No obstructive or overt infiltrative disease was noted. No associated abnormal lymphatic activity was noted.

**Pancreas**

The base and limbs of the **pancreas** were observed to be largely isoechoic to surrounding omental fat. Pancreatic duct and capsular contour were acceptably normal and parenchyma respected normal curvilinear patterns. No overt evidence of active inflammatory or neoplastic disease was noted.

**ULTRASONOGRAPHIC FINDINGS**

- Splenic nodules



## PATIENT

- Unremarkable abdomen otherwise

Zuzu Revello

## INTERPRETATION OF THE FINDINGS & FURTHER RECOMMENDATIONS

## SPECIES

Further imaging of the adrenal glands and lower urinary tract recommended. The cause of lethargy and vomiting is unclear. Structurally unremarkable abdomen otherwise. FNA of the splenic lesions recommended. Supportive care should prove effective. Dietary indiscretion, food intolerance, structurally insignificant inflammatory bowel or occult parasitism and occult Addison's are all potentials.

Canine

## BREED

Mini Poodle Mix

## SEX

Spayed Female

## AGE

12 Years

## WEIGHT

4.02 kg

## INTERPRETED BY

Eric Lindquist, DMV  
DABVP, Cert. IVUSS

## IMAGING PERFORMED BY

Dr. Massa

## HOSPITAL NAME

Animal Emergency  
Hospital, Volusia

## REFERRING VET

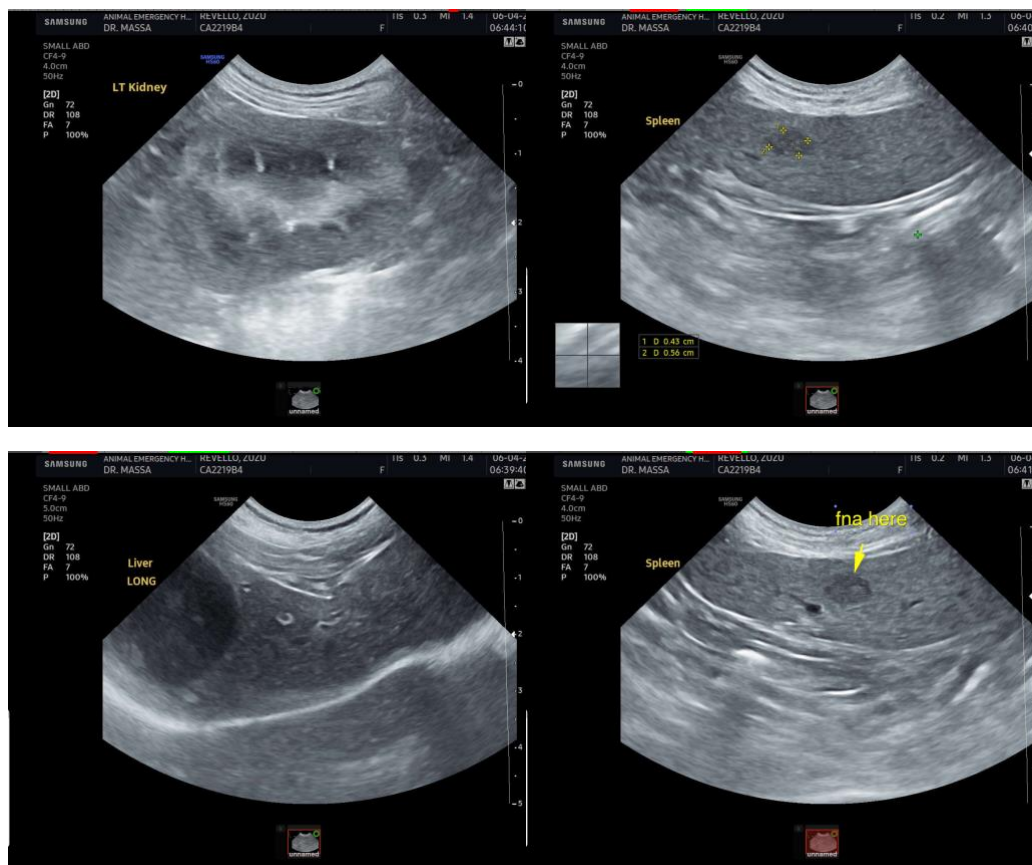
Dr. Massa

## INVOICE

15888

## DATE

6/4/22



The information and recommendations provided are based on the images presented by the referring veterinarian. No evaluation can be communicated regarding pathology that was not visible in the image/video clips provided.

Thank you for this referral. If the clinical or image interpretation does not parallel your findings or if I can be of any further assistance please contact me.

**Eric Lindquist**, DMV, DABVP, Cert. IVUSS, CEO of SonoPath.com  
info@SonoPath.com