



**PATIENT**

Peanut Dressel

**PRESENTING CLINICAL SIGNS**

splenic mass? pancreatitis Current meds Cerenia, Metro, Pantoprazole

**SPECIES**

Canine

**ULTRASONOGRAPHIC EXAMINATION OF THE HEART & ABDOMEN**

**BREED**

Bulldog X

CANINE CARDIAC PARAMETERS	MR VMAX (m/s)	TR VMAX (m/s)	LA/AO (Boon method)	LA/AO (Heart Base; Swe)	FS (%)	EF (%)	EPSS (cm)
NORMAL PARAMETER	4.5-5.5	<2.7	1.3	<1.6	28-40	40-100	<0.6
PATIENT		2.0	1.3	1.3	42	75	0.2
CANINE CARDIAC PARAMETERS	HR (BPM)	AV VMAX (m/s)	PV MAX (m/s)	BODY WEIGHT (kg)	LA 2D short axis Base view (cm)	LVIDd Avg; 2D and m-mode short axis (cm)	LVIDs Avg; 2D and m-mode short axis (cm)
NORMAL PARAMETER	50-100	0.7-1.7	0.7-1.6	BELOW	BELOW	BELOW	BELOW
PATIENT	107	1.47	0.8		--	2.92	

**SEX**

Spayed Female

**AGE**

14 Years

**WEIGHT**

51.5 Pounds

**Cardiac Presentation**

The echocardiogram in this patient demonstrated normal **left atrial** size based on 3 separate methods of LA evaluation. Minor mitral insufficiency noted, centralized. The **left ventricle** presented thicknesses with linear contour and was not dilated nor restricted. The **myocardium** presented normal echogenicity without subjective evidence of significant fibrotic or ischemic disease. **Contractility** of the ventricular walls was adequate and in normal range for this patient evidenced by the fractional shortening measurement and subjective evaluation of the different regions of the myocardium. The **left ventricular outflow** tract demonstrated normal laminar flow and subjective structural integrity. The **right atrium** and auricle revealed normal size, structure and content. No evidence of masses was noted. Minor **tricuspid** insufficiency noted. The **right ventricle** was of normal size (1/3 diameter of LV), chordae structure, myocardial echogenicity and thickness. **Pulmonary outflow** tract assessment revealed normal valve structure, laminar flow, and diameter (approx. 1:1 pa/ao ratio). No visible **pericardial** or free pleura fluid was noted. The cranial **mediastinum** and **pericardial** and **extra-cardiac** regions were free of masses in the visible window.

**Urinary System**

The **urinary bladder**, trigone, and pelvic urethra presented normal thicknesses and normal tone. The ureters were not visible which is normal. No uroliths or sediment were visualized and anechoic urine was present. No evidence of inflammatory or neoplastic changes were noted. Ureteral papillae were normal.

The **kidneys** revealed largely normal size and structure, corticomedullary definition and ratio (cortex 1/3 of medulla) were essentially maintained with some age-related loss of curvilinear patterns regarding the capsule and C/M junction. The cortices presented largely uniform texture with some increased echogenicity expected for his age patient. Medullary structure differed distinctly from that of the cortex

**INTERPRETED BY**

Eric Lindquist, DMV

DABVP, Cert. IVUSS

**IMAGING PERFORMED BY**

Jenn

**HOSPITAL NAME**

Rockaway AH

**REFERRING VET**

Dr. Maniar

**INVOICE**

38399

**DATE**

6/4/22



**PATIENT**

Peanut Dressel

and no evidence of pelvic dilation was present. The left kidney measured 5.0 cm. The right kidney measured 4.86 cm.

**Adrenal Glands**

**SPECIES**

Canine

Both **adrenal glands** were visualized and recognized as having normal shape, size, position and echogenicity for this breed. The phrenic vasculature, glandular echogenicity and detail were unremarkable. Capsule, cortex, and medullary definition were normal for this age patient. The right adrenal gland measured 2.97 cm x 1.05 cm at the cranial pole and 0.73 cm at the caudal pole.

**BREED**

Bulldog X

**Spleen**

The **spleen** revealed multifocal nodular changes and an overt parenchymal mass measuring 4.0 cm with capsular expansion.

**SEX**

Spayed Female

**Liver**

The **liver** images from right and left intercostal as well as subcostal views revealed subjectively normal liver size, contour, and structure. Some age-related parenchymal remodeling was noted but likely not clinically significant at this time. A hypoechoic nodule was noted in the left cranial liver, and other minor heterogeneous and cystic changes. These may be completely unrelated to the splenic pathology. Vascular and biliary tracts were of normal volume and no evidence of congestion was noted. The gallbladder presented some dependent debris with essentially normal contour. The cystic and common bile ducts were normal. No overt evidence of active inflammatory, infiltrative or regenerative pathology was noted but should be paired with current or past LE elevations regarding any clinical significance to this presentation. The hepatic lymph nodes were unremarkable.

**AGE**

14 Years

**WEIGHT**

51.5 Pounds

**Gastrointestinal**

**INTERPRETED BY**

Eric Lindquist, DMV

DABVP, Cert. IVUSS

Examination of the **gastrointestinal tract** revealed a stomach and intestine free of stasis, of normal wall thickness, acceptable curvilinear mural detail, and peristaltic activity. Small and large intestine demonstrated normal luminal chyme and stool consistency respectively. No obstructive or overt infiltrative disease was noted. No associated abnormal lymphatic activity was noted.

**IMAGING PERFORMED BY**

Jenn

**Pancreas**

The base and limbs of the **pancreas** were observed to be largely isoechoic to surrounding omental fat. Pancreatic duct and capsular contour were acceptably normal and parenchyma respected normal curvilinear patterns. No overt evidence of active inflammatory or neoplastic disease was noted.

**HOSPITAL NAME**

Rockaway AH

**ULTRASONOGRAPHIC FINDINGS**

- Trivial mitral and tricuspid insufficiency, Stage B1 valvular disease
- Splenic mass
- Undefined nodular hepatic changes – possible metastatic disease versus nodular hyperplasia more likely.

**REFERRING VET**

Dr. Maniar

**INVOICE**

38399

**DATE**

6/4/22

**INTERPRETATION OF THE FINDINGS & FURTHER RECOMMENDATIONS**

No evidence of clinical cardiac disease. The heart is stable without clinical disease. No overt contraindication for anesthesia of brief to moderate duration. I suggest Torbutrol premed, Propofol induction, Isoflurane maintenance or similar protocol if anesthesia is desired. Blood pressure recommended if not already performed and target white coat negative systolic pressure of < 160 mmHg. If higher than



**PATIENT**

Peanut Dressel

this ACE-inhibitor is suggested to reach this level. Recheck echocardiogram is recommended in 6 months, earlier if murmur grade increases or clinical signs initiate.

**SPECIES**

Canine

Recommend chest radiographs, exploratory splenectomy with liver inspection and biopsy.

**BREED**

Bulldog X

**SEX**

Spayed Female

**AGE**

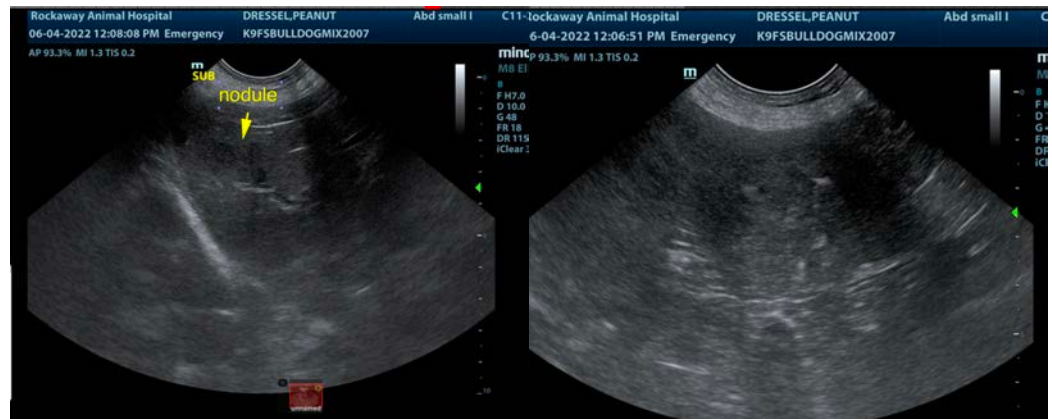
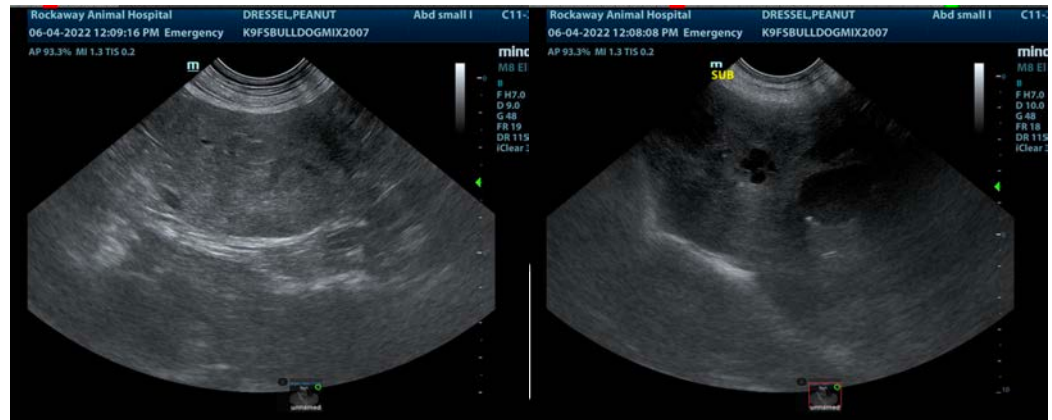
14 Years

**WEIGHT**

51.5 Pounds

**INTERPRETED BY**

Eric Lindquist, DMV  
DABVP, Cert. IVUSS



**IMAGING PERFORMED BY**

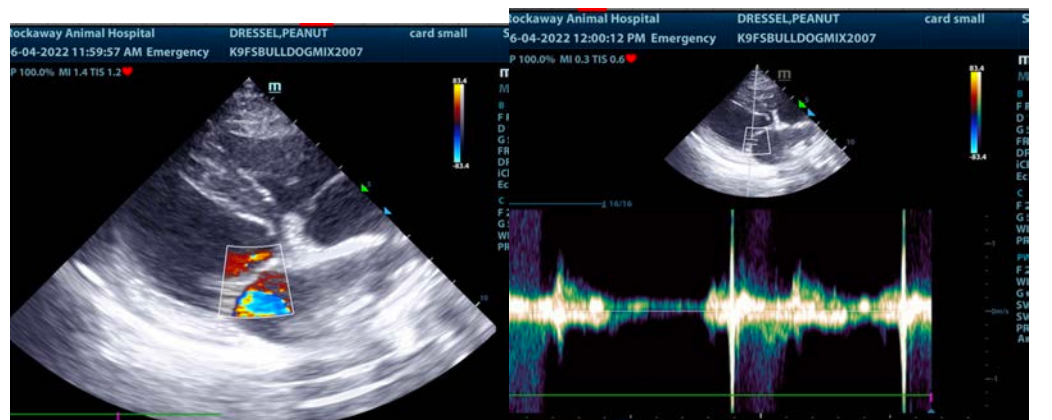
Jenn

**HOSPITAL NAME**

Rockway AH

**REFERRING VET**

Dr. Maniar



**INVOICE**

38399

**DATE**

6/4/22



**PATIENT**

Peanut Dressel

**SPECIES**

Canine

**BREED**

Bulldog X

**SEX**

Spayed Female

**AGE**

14 Years

**WEIGHT**

51.5 Pounds

**INTERPRETED BY**

Eric Lindquist, DMV

DABVP, Cert. IVUSS

**IMAGING PERFORMED BY**

Jenn

**HOSPITAL NAME**

Rockaway AH

**REFERRING VET**

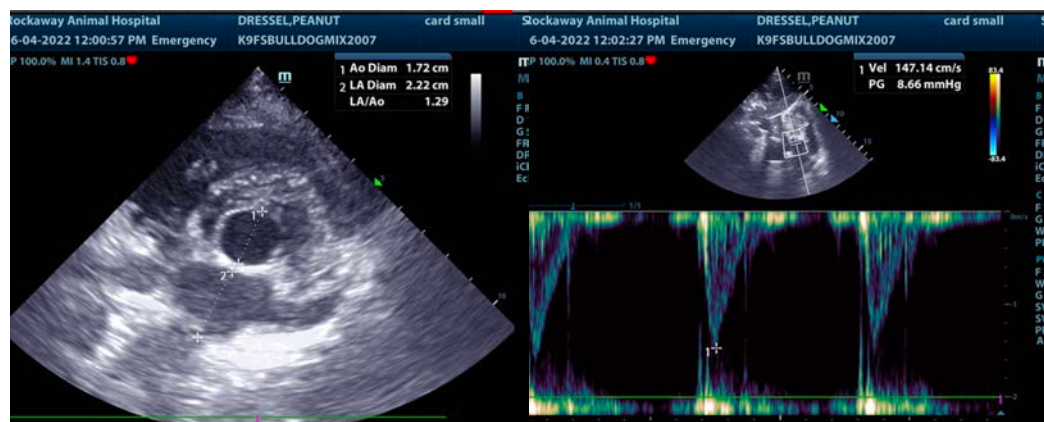
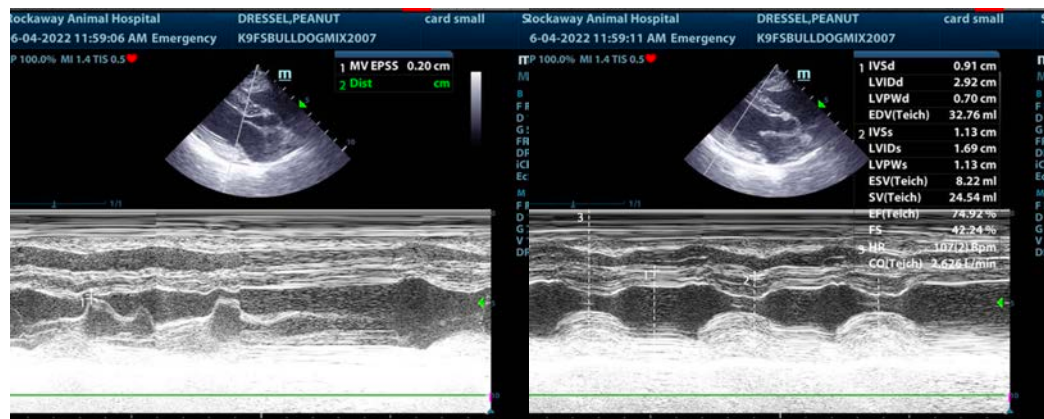
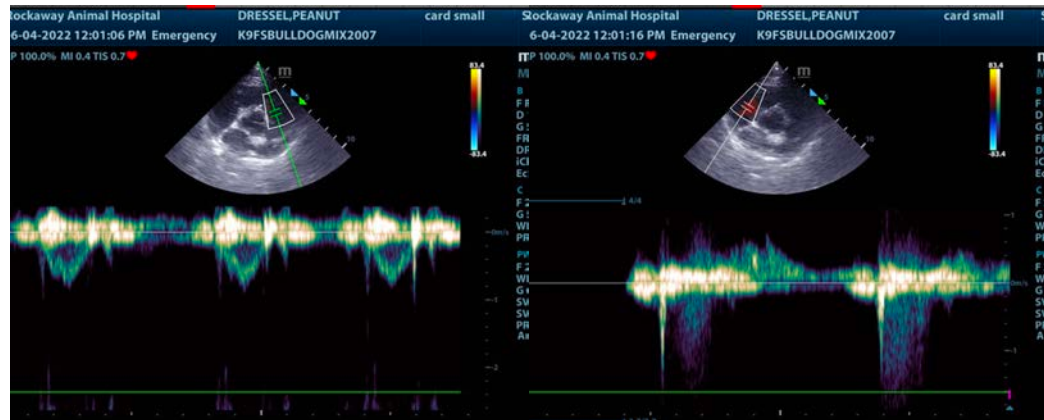
Dr. Maniar

**INVOICE**

38399

**DATE**

6/4/22





**PATIENT**

Peanut Dressel

**SPECIES**

Canine

**BREED**

Bulldog X

**SEX**

Spayed Female

**AGE**

14 Years

**WEIGHT**

51.5 Pounds

**INTERPRETED BY**

Eric Lindquist, DMV  
DABVP, Cert. IVUSS

**IMAGING PERFORMED BY**

Jenn

**HOSPITAL NAME**

Rockaway AH

**REFERRING VET**

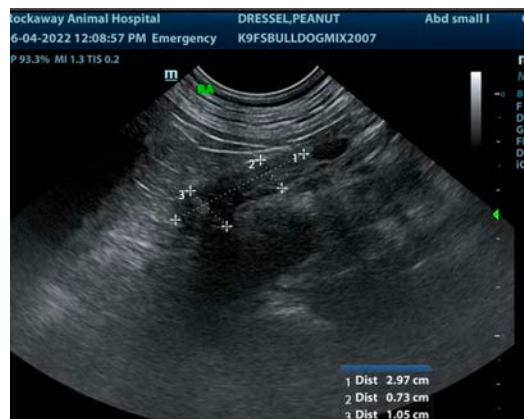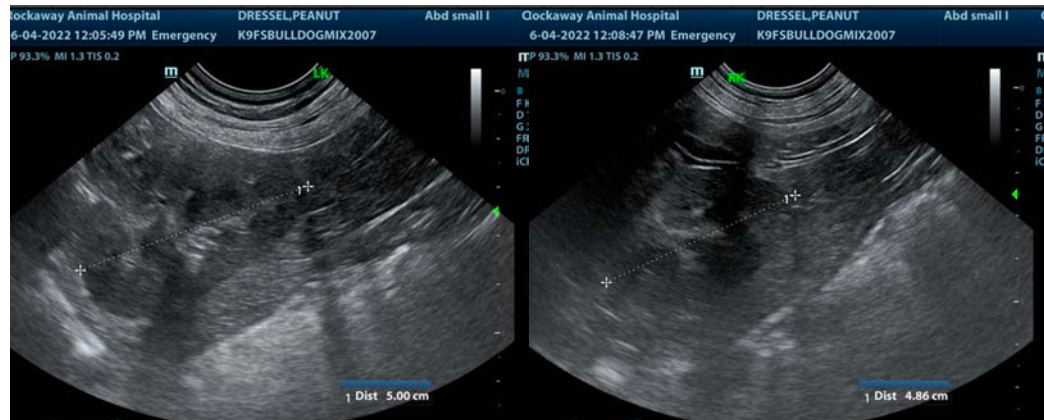
Dr. Maniar

**INVOICE**

38399

**DATE**

6/4/22



The information and recommendations provided are based on the images presented by the referring veterinarian/sonographer. No evaluation can be communicated regarding pathology that was not visible in the image/video clips provided.

Thank you for this referral. If the clinical or image interpretation does not parallel your findings or if I can be of any further assistance please contact me.

**Eric Lindquist, DMV, DABVP, Cert. IVUSS, CEO of SonoPath.com**

[info@SonoPath.com](mailto:info@SonoPath.com)