



PATIENT

Oliver Ginsberg

PRESENTING CLINICAL SIGNS

poss fell down stairs at home, wobbly lethargic

SPECIES

Canine

ULTRASONOGRAPHIC EXAMINATION OF THE ABDOMEN

Urinary System

The **urinary bladder**, trigone, and pelvic urethra presented normal thicknesses and normal tone. The ureters were not visible which is normal. No uroliths or sediment were visualized and anechoic urine was present. No evidence of inflammatory or neoplastic changes were noted. Ureteral papillae were normal.

BREED

French Bulldog

SEX

Male

The **kidneys** revealed normal size and structure, corticomedullary definition and ratio for this age. The cortices presented largely uniform texture with normal echogenic relationship to liver and spleen. Medullary structure differed distinctly from the cortex and no evidence of pelvic dilation was present. The capsules were acceptably uniform without significant irregularities. The left kidney measured 3.4 cm. The right kidney measured 3.9 cm.

AGE

12 Weeks

Adrenal Glands

Both **adrenal glands** were visualized and recognized as having normal shape, size, position and echogenicity for this breed. The phrenic vasculature, glandular echogenicity and detail were unremarkable. Capsule, cortex, and medullary definition were normal for this age patient. The right adrenal gland measured 1.34 cm x 0.56 cm at the caudal pole and 0.93 cm at the cranial pole. The left adrenal gland measured 1.43 cm x 0.32 cm at the caudal pole and 0.30 cm at the cranial pole.

WEIGHT

5.8 Pounds

Spleen

The **spleen** presented a smooth homogeneous parenchyma hyperechoic to liver and renal cortical parenchyma. The capsule was smooth without noticeable expansion or deviation from within the spleen or adjacent pathology. The splenic vasculature demonstrated normal volume without signs of congestion or thrombosis. No sonographic evidence of acute or chronic inflammatory, neoplastic, or infarctual changes were noted.

INTERPRETED BY

Eric Lindquist, DMV

DABVP, Cert. IVUSS

IMAGING PERFORMED BY

Jenn

HOSPITAL NAME

Rockaway AH

Liver

The **liver** images submitted revealed subjectively normal liver size, contour, and structure. Parenchymal echogenicity was naturally coarse and hypoechoic to the spleen. Vascular and biliary tracts were of normal volume with no evidence of congestion. The gallbladder presented acceptably thin walls with primarily anechoic content. The cystic and common bile ducts were normal. No pathological hepatic lymphadenopathy was evident. No overt structural evidence of inflammatory, infiltrative or regenerative pathology was evident.

REFERRING VET

Dr. Maniar

Portal vein to vena cava ratio was 1:1. No evidence of extrahepatic or intrahepatic shunting.

Gastrointestinal

INVOICE

38396

The **stomach** was mildly overdistended with chyme. The pylorus was free of evident pathology. The small intestine and colon were unremarkable.

Pancreas

DATE

6/4/22

The base and limbs of the **pancreas** were observed to be largely isoechoic to surrounding omental fat. Pancreatic duct and capsular contour were acceptably normal and parenchyma respected normal curvilinear patterns. No overt evidence of active inflammatory or neoplastic disease was noted.



PATIENT

Free Abdomen

Oliver Ginsberg

Physiologic free fluid noted in the abdomen.

SPECIES

Canine

ULTRASONOGRAPHIC FINDINGS

- Normal abdomen

BREED

French Bulldog

INTERPRETATION OF THE FINDINGS & FURTHER RECOMMENDATIONS

No evidence of abdominal disease responsible for the clinical signs. CNS and cardiac exams recommended.

SEX

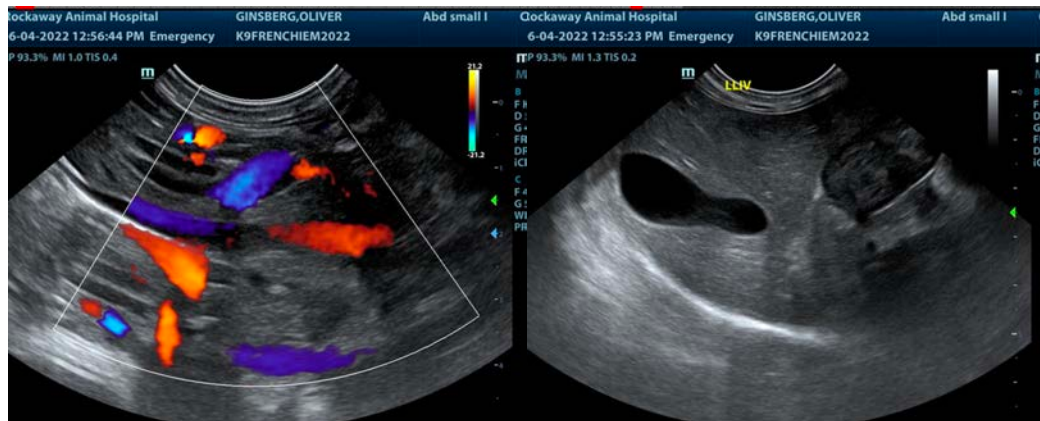
Male

AGE

12 Weeks

WEIGHT

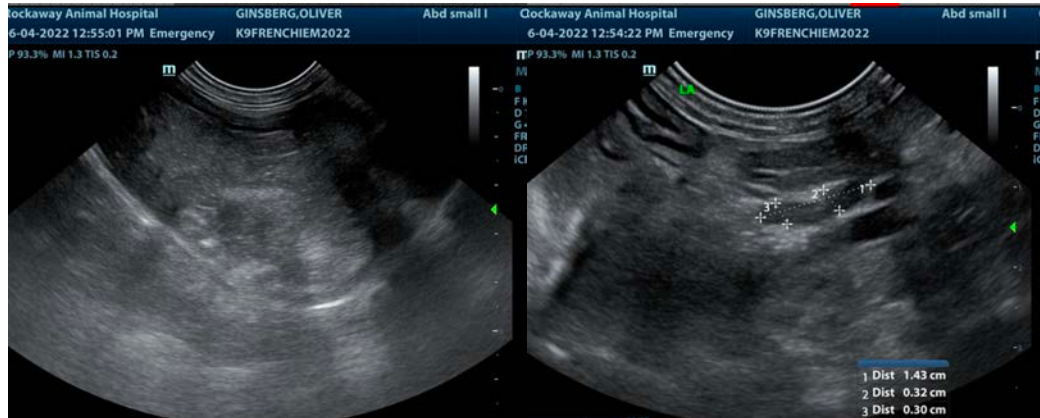
5.8 Pounds



INTERPRETED BY

Eric Lindquist, DMV

DABVP, Cert. IVUSS

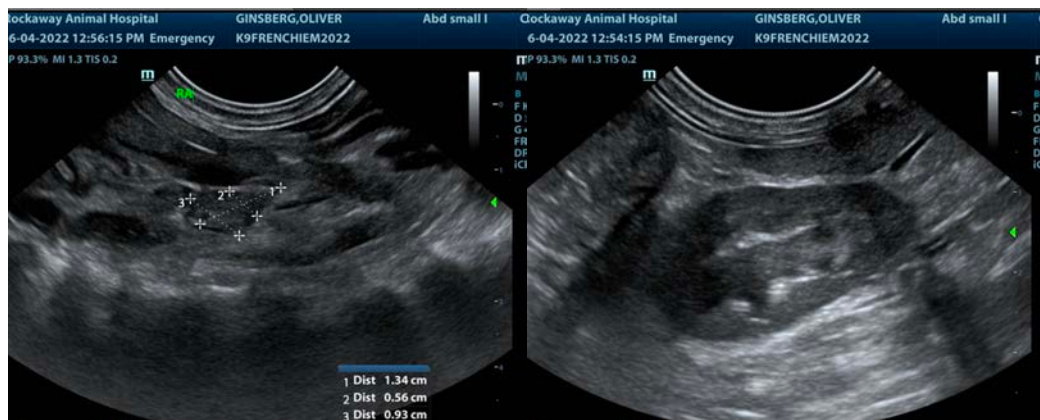


IMAGING PERFORMED BY

Jenn

HOSPITAL NAME

Rockaway AH



REFERRING VET

Dr. Maniar

INVOICE

38396

DATE

6/4/22



PATIENT

Oliver Ginsberg

The information and recommendations provided are based on the images presented by the referring veterinarian/sonographer. No evaluation can be communicated regarding pathology that was not visible in the image/video clips provided.

SPECIES

Canine

Thank you for this referral. If the clinical or image interpretation does not parallel your findings or if I can be of any further assistance please contact me.

Eric Lindquist, DMV, DABVP, Cert. IVUSS, CEO of SonoPath.com

info@SonoPath.com

BREED

French Bulldog

SEX

Male

AGE

12 Weeks

WEIGHT

5.8 Pounds

INTERPRETED BY

Eric Lindquist, DMV

DABVP, Cert. IVUSS

IMAGING PERFORMED BY

Jenn

HOSPITAL NAME

Rockaway AH

REFERRING VET

Dr. Maniar

INVOICE

38396

DATE

6/4/22